S Afr J Surg. 2026;64:322-330. Online first
https://doi.org/10.36303/SAJS.05104

Open Access article distributed under the terms of the Creative Commons Attribution-Non-Commercial Works 4.0 South Africa License (CC BY NC)
https://creativecommons.org/licenses/by-nc/4.0/

S Afr J Surg
ISSN: 0038-2361 eISSN: 2078-5151
© 2026 The Author(s)
REVIEW

An analysis of adverse oesophageal events after endoscopic variceal ligation

JEJ Krige,[1] SR Thomson[2]

[1] *Department of Surgery, Faculty of Health Sciences, Groote Schuur Hospital, University of Cape Town, South Africa*
[2] *Department of Medicine, Faculty of Health Sciences, Groote Schuur Hospital, University of Cape Town, South Africa*

Corresponding author, email: *jej.krige@uct.ac.za*

Endoscopic variceal ligation (EVL) is the preferred endoscopic treatment for acute oesophageal variceal bleeding and is used for primary and secondary prophylaxis because of its efficacy and improved safety compared with injection sclerotherapy. Nevertheless, procedure-related adverse events remain clinically important, particularly in patients with advanced portal hypertension and decompensated liver disease. Published complication rates vary widely due to differences in patient selection, operator experience, study design, duration of follow-up and inconsistent definitions and reporting of adverse events. This narrative review evaluates the spectrum, mechanisms, clinical presentation, prevention and management of oesophageal complications associated with EVL. Local oesophageal complications include intra-procedural bleeding, post-banding ulceration, post-banding ulcer bleeding, incomplete variceal eradication, recurrent varices, early rebleeding, dysmotility, dysphagia, oesophageal obstruction, stricture and perforation. Gastric mucosal consequences, including portal hypertensive gastropathy and duodenopathy are also considered. In addition, device-related technical complications, including band deployment failure, barrel dislodgement and ligator malfunction are included because of the distinct mechanisms and preventive strategies. Most complications are uncommon and can be minimised by careful patient selection, meticulous endoscopic technique, appropriate equipment checks and early recognition of evolving adverse events. Although serious complications are infrequent, prompt diagnosis and multidisciplinary management are essential to optimise patient outcomes. The review also highlights the lack of uniform reporting standards for EVL-related adverse events and emphasises the need for prospective, standardised classification systems to facilitate meaningful comparisons between studies. Improved understanding of the mechanisms, prevention and management of EVL-related complications should further enhance the safety and effectiveness of this established endoscopic therapy.
Keywords: oesophageal variceal bleeding, adverse events, endoscopic variceal ligation

Introduction

Endoscopic therapy has transformed the management of portal hypertensive bleeding and is now central to the treatment of both oesophageal and gastric varices (Figure 1).[1] Endoscopic variceal ligation (EVL) has replaced injection sclerotherapy (IST) as the first-line treatment for bleeding oesophageal varices, both during acute haemorrhage and for secondary prophylaxis because randomised controlled trials have demonstrated more rapid variceal eradication, lower rebleeding rates and fewer procedure-related complications.[2,3] Despite the favourable safety profile, both elective and emergency EVL remain associated with procedure-related adverse events.[4]

Among 17 prospective randomised controlled trials comparing EVL with IST, reported complication rates ranged from 2–69%, reflecting inconsistent definitions and reporting of adverse events rather than true differences in safety.[5] The absence of standardised reporting requirements has hindered accurate estimation of complication rates, which range from transient self-limiting symptoms to life-threatening haemorrhage and procedure-related mortality.[4] Although the recently developed AGREE (Adverse events in GastRointEstinal Endoscopy) classification provides a standardised framework for reporting endoscopic complications, retrospective application to the existing literature is limited because most studies predate its introduction and lack the clinical detail required for accurate severity grading.[6]

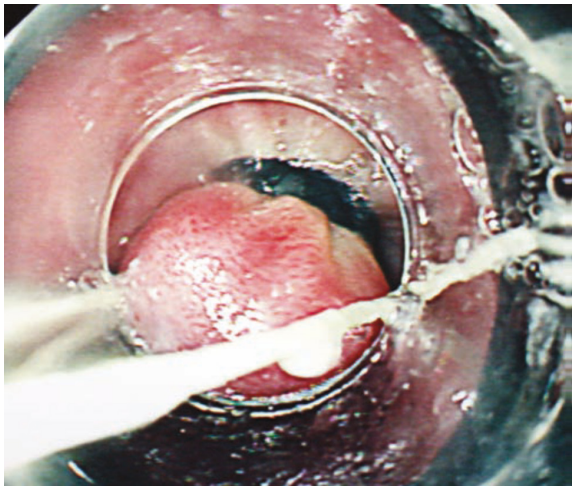

Figure 1: Ligated oesophageal varix with a secure band in situ

This review provides a contemporary overview of complications associated with endoscopic therapy for oesophageal varices. Complications are classified according

to their anatomical location, pathophysiological mechanism and clinical significance, with emphasis on their incidence, pathogenesis, prevention and management. Particular attention is given to post-banding ulcer bleeding, technical complications, and the evolving role of standardised complication reporting to facilitate future research and quality improvement.

Literature search

The literature reviewed in this narrative article was identified through comprehensive searches of PubMed/MEDLINE, PMC, Web of Science, Scopus, Primo and the Cochrane Library from database inception to 30 June 2026. Search terms included combinations of portal hypertension, oesophageal varices, endoscopic variceal ligation, complications, adverse events, rebleeding, post-banding ulcer bleeding, oesophageal obstruction, oesophageal stricture, perforation, and technical complications (Supplementary Table I). Reference lists of relevant articles, systematic reviews and international guidelines were manually searched to identify additional publications.

Data synthesis

As considerable heterogeneity existed in study designs, definition of complications and outcome reporting, formal meta-analysis was not appropriate and evidence was synthesised narratively. Complications were categorised as either (i) local or (ii) technical and device-related, and reviewed with regard to incidence, pathogenesis, clinical significance, prevention and management. Where possible, incidence estimates and management recommendations were based on systematic reviews, meta-analyses and prospective

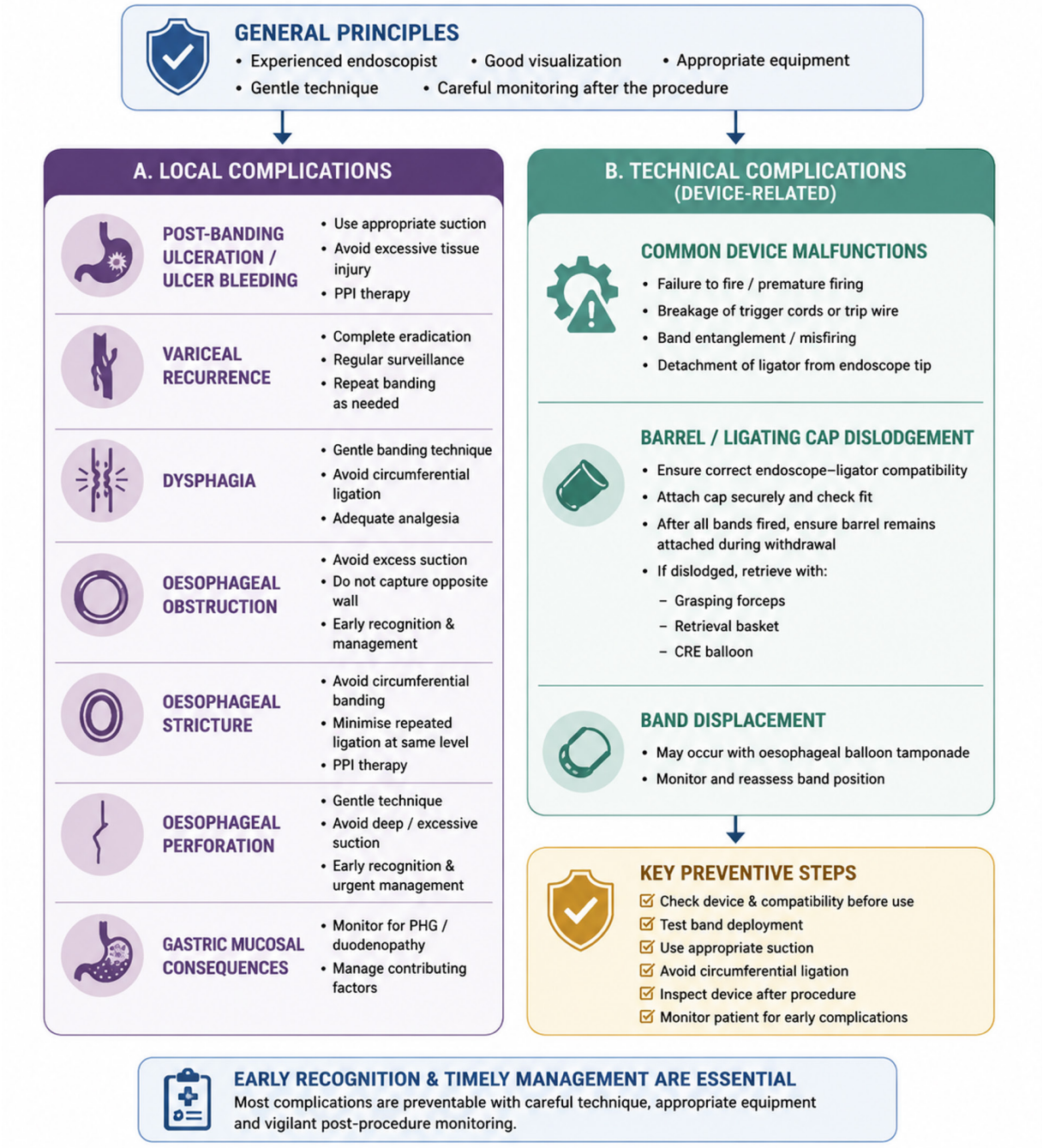

Figure 2: Local and technical complications following endoscopic variceal ligation: principles of prevention
PPI – proton pump inhibitor, PHG – portal hypertensive gastropathy

studies; however, uncommon complications were interpreted with caution because evidence was frequently limited to isolated case reports or small case series.

Incidence of complications after endoscopic therapy

There is no universally accepted definition or classification of complications following endoscopic treatment of oesophageal varices, and reported incidence rates therefore vary widely.[4] This variability reflects differences in study design, patient selection, operator experience, emergency versus elective treatment, duration of follow-up and inconsistent reporting of adverse events.[7] Patients undergoing endoscopic therapy frequently have advanced liver disease, making it difficult to distinguish procedure-related complications from those attributable to the underlying disease. Prospective studies with systematic data collection generally report higher complication rates than retrospective series, and outcomes are reported variably on a per-patient or per-procedure basis.[4,7] Despite these limitations, the best available evidence suggests that 10–15% of patients experience a procedure-related complication, whereas procedure-related mortality remains < 1%.[4]

Categorisation of EVL-related complications

Complications of EVL are grouped according to their anatomical location, pathophysiological mechanism and clinical impact. For the purposes of this review, adverse events have been grouped into two categories: (i) local and (ii) technical or device-related complications (Figure 2). Local complications occur at or adjacent to the site of endoscopic treatment and include ulceration, bleeding, obstruction, stricture and perforation. Technical complications relate to equipment malfunction, device failure or procedural factors. This practical categorisation provides a framework for discussing the incidence, mechanisms, prevention and management of adverse events. Not reviewed are the systemic and sedation-related risks associated with therapeutic variceal endoscopy which are beyond the remit of this analysis.

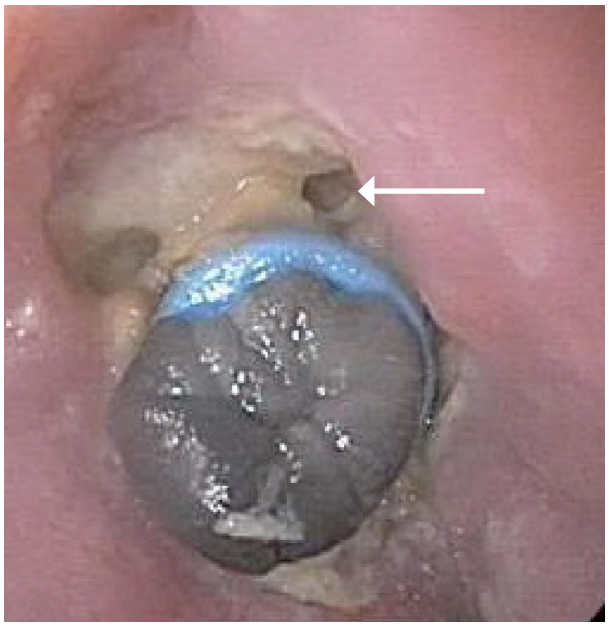

Figure 3: Necrotic banded varix and associated oesophageal ulceration (arrow)

EVL-induced ulceration

Post-ligation ulceration is an inevitable consequence of successful EVL and represents the normal healing response rather than a true complication. Following thrombosis and sloughing of the ligated varix, a superficial mucosal ulcer develops and usually heals within 2–3 weeks by granulation, re-epithelialisation and scar formation.[8-10] Although ulceration is universal, most ulcers remain asymptomatic or cause only mild retrosternal discomfort, odynophagia or transient dysphagia. The principal clinical significance is that the ulcers provide the substrate for post-banding ulcer bleeding. Ulcer healing may be impaired by advanced liver disease, persistent portal hypertension, coagulopathy, infection or continued acid exposure. In a randomised controlled trial, pantoprazole significantly reduced post-banding ulcer size, although ulcer number and symptoms were unchanged, suggesting that proton pump inhibitors may promote mucosal healing without proven benefit for clinically important outcomes.[11]

EVL-induced ulcer bleeding

Post-banding ulcer bleeding (PBUB) is the most serious local complication of EVL and is associated with substantial morbidity and mortality. Bleeding occurs when sloughing of the ligated tissue or premature band detachment exposes a patent underlying varix before complete thrombosis has occurred.[12] This may result from incomplete suction of the varix into the ligating cap or inaccurate band placement during emergency endoscopy.[13] Endoscopically, PBUB is defined as either active bleeding from an ulcer base with a patent underlying varix or bleeding from a post-ligation ulcer following premature band slippage or dislodgement.[14]The pathogenesis is multifactorial. Premature band slippage with incomplete variceal thrombosis is the principal mechanism, while delayed ulcer healing secondary to gastro-oesophageal reflux, coagulopathy, local infection, advanced liver disease and technical factors may further increase the risk.[15] Clinically significant PBUB occurs in 3.6–15% of patients and carries a reported mortality of up to 52%.[15] Although reported outcomes vary because of inconsistent definitions and heterogeneous study populations, endoscopic classification into Type A (spurting), Type B (oozing), Type C (adherent clot) and Type D (clean ulcer base) may assist therapeutic decision-making.[16]

Management depends on the severity of bleeding and available expertise. Endoscopic options include repeat EVL, cyanoacrylate or sclerosant injection, haemostatic powders, through-the-scope and over-the-scope clips, while rescue therapies include oesophageal self-expanding metal stents (SEMS), Sengstaken-Blakemore balloon tamponade and transjugular intrahepatic portosystemic shunt (TIPS).[12] In a retrospective series, SEMS achieved haemostasis in 82.1% of patients and served as an effective bridge to definitive portal decompression.[17] Proton pump inhibitors may accelerate ulcer healing and have been associated with improved bleeding-free survival, although definitive evidence for improved clinical outcomes remains limited.[18]

Variceal eradication and recurrence

Complete endoscopic eradication of oesophageal varices is the principal therapeutic endpoint of EVL and is recommended by current AASLD/ACG guidelines to reduce recurrent haemorrhage.[19] However, reported eradication rates vary from 55–95%, reflecting differences in treatment protocols, follow-up schedules and definitions of eradication.[5] Some studies considered residual varices too small for ligation as eradicated, whereas others required complete endoscopic disappearance. Variceal recurrence should be distinguished from persistent varices; recurrence refers to reappearance after documented eradication, whereas persistence reflects incomplete initial treatment. Failure to differentiate these entities contributes to the wide variation in reported recurrence rates.[5]

Recurrence reflects the limitations of EVL rather than treatment failure alone. Band ligation eradicates the intraluminal varix but does not obliterate the perforating veins connecting the submucosal varices to the extramural collateral circulation, allowing progressive redevelopment of varices.[20] In addition, residual varices become increasingly difficult to ligate because of their small size and progressive mucosal fibrosis following repeated treatment sessions.[5] These anatomical and technical limitations explain the need for repeated treatment and continued endoscopic surveillance after apparent variceal eradication.

Variceal rebleeding

Variceal rebleeding remains a major cause of morbidity and mortality following EVL. According to the Baveno VII consensus, rebleeding is classified as failure to control bleeding within 5 days of the index procedure or early rebleeding occurring within 6 weeks after initial haemostasis.[21] Early rebleeding occurs in 10–20% of patients and is associated with mortality approaching 40%.[21]

Early rebleeding comprises several distinct mechanisms, including persistent bleeding from incompletely ligated varices, premature band slippage with PBUB, recurrent haemorrhage from incompletely thrombosed varices, bleeding from untreated adjacent ("virgin") varices and non-variceal sources such as portal hypertensive gastropathy or peptic ulcer disease. Failure to distinguish between these mechanisms has contributed to the heterogeneity of published studies evaluating rebleeding after EVL.[7,22]

Risk factors include advanced liver disease, particularly Child-Pugh class C cirrhosis, active bleeding at index endoscopy, large varices, red wale signs, spontaneous bacterial peritonitis, severe ascites, hypoalbuminaemia, anaemia, elevated blood urea nitrogen, coagulopathy and a hepatic venous pressure gradient exceeding 16 mmHg.[23] Technical factors, including inadequate suction and premature band slippage related to variations in ligation-band retraction forces, may further increase the risk of recurrent haemorrhage.[24] Careful band placement, complete suction of the target varix, meticulous surveillance and appropriate secondary prophylaxis remain the principal strategies for preventing rebleeding.[25]

Dysmotility

The effects of EVL on oesophageal motility have been inadequately studied, and the true incidence and clinical significance of post-EVL dysmotility remain uncertain. Before treatment, patients with oesophageal varices often demonstrate impaired oesophageal motor function, characterised by reduced peristaltic amplitude, prolonged contractions and delayed oesophageal transit, while lower oesophageal sphincter (LOS) function is usually preserved. Gastro-oesophageal reflux disease is present in up to 64% of patients.[26]

Unlike IST, which significantly impairs oesophageal motility, EVL has little effect on oesophageal motor function. Manometric studies demonstrate no significant changes in LOS pressure or peristaltic amplitude, duration or propagation following ligation. Although transient impairment of oesophageal transit may occur immediately after treatment, it resolves as oedema subsides and ulcer healing progresses. Persistent dysmotility should therefore prompt investigation for alternative structural complications rather than being attributed to EVL itself.[26]

Dysphagia

Transient dysphagia is one of the most common symptoms following EVL. Although oesophageal motility is generally preserved, up to 75% of patients experience swallowing difficulty during the first 24–72 hours, probably because of local oedema, oesophageal spasm and temporary luminal narrowing from the ligated varices rather than permanent neuromuscular dysfunction.[26] Symptoms are usually mild and resolve spontaneously as oedema subsides and post-ligation ulcers heal, requiring only reassurance, dietary modification and simple analgesia.

Persistent or progressive dysphagia is not an expected consequence of EVL and should prompt endoscopic evaluation to exclude structural complications such as oesophageal obstruction, stricture or, rarely, perforation. The distinction between transient and persistent dysphagia is clinically important, as the latter usually indicates an underlying complication requiring further investigation and treatment.[26]

Oesophageal obstruction

Complete oesophageal obstruction is an uncommon but potentially serious complication of EVL. It results from excessive suction during band deployment, with inadvertent capture of the opposite oesophageal wall, producing circumferential luminal entrapment into a single elastic band. Only 12 cases have been reported.[27] Patients typically present within hours of EVL with severe dysphagia, odynophagia, inability to swallow saliva, retrosternal pain and regurgitation. Endoscopy confirms complete luminal occlusion. Although obstruction has been reported more frequently in women, elderly patients, those with large varices and after repeated ligation sessions, the limited number of cases precludes firm conclusions regarding risk factors.[28]

Most patients respond to conservative management with intravenous fluids, analgesia, proton pump inhibitors and temporary fasting, with spontaneous restoration of luminal patency after band sloughing. Endoscopic band removal has been described but should be undertaken cautiously because of the risk of precipitating haemorrhage. Surgical intervention is rarely required.[29]

Prevention depends on meticulous technique, avoiding excessive suction and ensuring that only the target varix and adjacent mucosa are captured within the ligation band. Early recognition and endoscopic assessment are essential

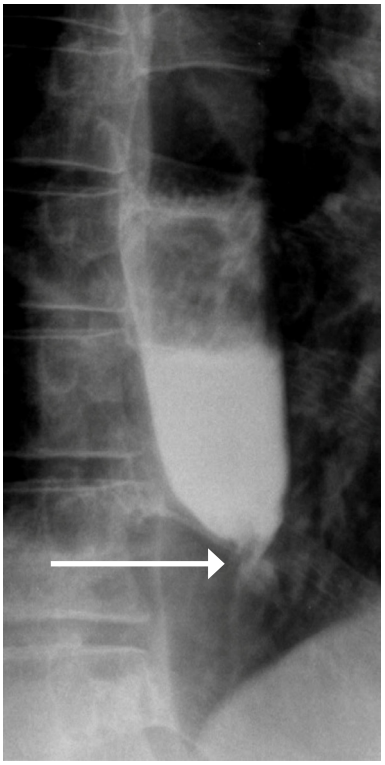

Figure 4: Gastrografin swallow showing complete distal oesophageal obstruction (arrow)

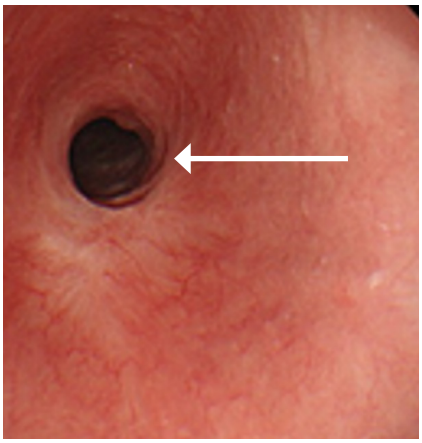

Figure 5: Distal oesophageal stricture after eradication of varices (arrow)

to prevent progression to pressure necrosis, perforation or subsequent stricture formation.[28,29]

Oesophageal stricture

Oesophageal stricture is an uncommon late complication of EVL resulting from excessive fibrosis during healing of post-ligation ulcers. Unlike IST, which causes deep mural inflammation and is strongly associated with stricture formation, EVL generally limits injury to the mucosa and submucosa, making clinically significant strictures uncommon.[30,31] Strictures usually develop several weeks after treatment and are associated with circumferential or overlapping band placement, repeated ligation at the same oesophageal level and healing of extensive post-banding ulceration. Previous endoscopic therapy, large varices and severe ulceration may further increase the risk.[31]

Patients typically present with progressive dysphagia, initially to solids and later to liquids, with or without odynophagia, weight loss or food bolus impaction. Persistent dysphagia beyond the expected post-EVL recovery period should prompt repeat endoscopy, which usually demonstrates a short fibrotic narrowing at the previous ligation site.[29-31]

Most strictures respond well to endoscopic dilatation using balloon or bougie dilators, although repeated treatment sessions may occasionally be required; however, dilatation should be undertaken cautiously in patients with persistent varices because of the risk of precipitating haemorrhage. Proton pump inhibitors are commonly prescribed to promote mucosal healing, while prevention depends on meticulous ligation technique, avoiding circumferential band placement and repeated banding at the same oesophageal level.[31]

Oesophageal perforation

Oesophageal perforation is a rare but serious complication of endoscopic of EVL. Unlike IST, where deep mural necrosis predisposes to perforation, tissue injury after EVL is usually confined to the mucosa and submucosa, making full-thickness perforation exceptionally uncommon.[24] Perforation may occur during band deployment because of excessive suction or traumatic instrumentation, or later as a consequence of deep ulceration, circumferential tissue injury, oesophageal obstruction or mural ischaemia. Previous endoscopic therapy and extensive fibrosis may further increase the risk.[24]

Patients typically present with severe retrosternal pain, dysphagia, odynophagia, fever and signs of mediastinitis or sepsis. Because early symptoms may resemble expected post-EVL discomfort, a high index of suspicion is essential. Contrast-enhanced CT with water-soluble oral contrast is the investigation of choice, while endoscopy should be undertaken cautiously when perforation is suspected.

Management depends on the size of the perforation and the patient's clinical condition. Initial treatment includes fasting, broad-spectrum antibiotics, proton pump inhibitors, nutritional support and drainage of infected collections when necessary. Selected contained perforations may be managed conservatively or with endoscopic therapies, including clips, covered self-expanding metal stents or endoscopic vacuum therapy, whereas extensive perforations, uncontrolled contamination or sepsis require urgent surgery. Early diagnosis and prompt multidisciplinary management are the principal determinants of outcome. Prevention relies on meticulous technique, avoiding excessive suction and circumferential banding. Oesophageal perforation should always be considered in patients who develop severe chest pain, persistent dysphagia or systemic toxicity after EVL.[32]

Gastric mucosal consequences

EVL is directed at oesophageal varices but may alter portal venous haemodynamics, raising concern that variceal eradication could contribute to the development or progression of portal hypertensive gastropathy (PHG) and portal hypertensive duodenopathy. The proposed mechanism is redistribution of portal blood flow following obliteration of oesophageal varices, although the available evidence remains limited and conflicting.[33]

In a prospective study of 60 patients undergoing variceal eradication with EVL or IST, the prevalence of both PHG and portal hypertensive duodenopathy increased after treatment, with no significant difference between the two modalities.[34] These findings suggest that the observed changes are more likely related to progression of the underlying portal hypertension than to the endoscopic technique itself. Most patients remain asymptomatic, although severe PHG may cause chronic iron-deficiency anaemia or, less commonly,



Figure 6: Wilson-Cook® multi-band ligation device demonstrating the vacuum-assisted cap and six-band delivery mechanism

acute gastric bleeding. Patients presenting with recurrent anaemia or upper gastrointestinal bleeding after successful variceal eradication should therefore be evaluated for gastric mucosal lesions as well as recurrent varices.[33,34]

Technical complications of multi-band ligation devices

Since the development of the original single-shot ligating device by Stiegmann in 1986,[35,36] numerous disposable and reusable multi-band ligators have been introduced. Although designs differ in the number of preloaded bands and deployment mechanisms, all operate on the same principles of vacuum-assisted tissue capture and elastic band release. Successful EVL depends not only on operator expertise but also on correct device assembly, compatibility and performance. Device malfunction may compromise haemostasis, prolong procedures and occasionally result in patient injury.[2,4]

Analysis of the United States Food and Drug Administration Manufacturer and User Facility Device Experience (MAUDE) database identified 3 531 reports describing 4720 device malfunctions and 258 patient-related adverse events between 2011 and 2021.[37] Common failures included unsuccessful or premature band deployment, trigger-cord or trip-wire breakage, component entanglement, device misfiring and detachment of the ligating cap. Reported patient complications included recurrent variceal bleeding, dysphagia, oesophageal laceration, perforation, haematoma and, rarely, death.[37]

An uncommon technical complication is dislodgement of the ligating barrel or cap within the oesophagus, usually resulting from incompatibility between the ligator and slimmer endoscopes or disengagement of the trigger cords after deployment of all bands.[38,39] The detached cap acts as an oesophageal foreign body and can usually be retrieved endoscopically using grasping forceps, retrieval baskets or a controlled radial expansion balloon.[40] Previously deployed bands may also be displaced during oesophageal balloon tamponade for uncontrolled bleeding.[41]

Most device-related complications are preventable. Before each procedure, compatibility between the ligator and endoscope should be confirmed, the cap securely attached and the deployment mechanism tested. Inspection of the device following ligation to ensure that the barrel remains attached to the endoscope is a simple but important safety measure.[25,40,41]

Strategies to prevent EVL-related complications

Prevention of complications after EVL begins with careful patient selection, meticulous endoscopic technique and early recognition of evolving adverse events. Although most complications are minor and self-limiting, serious events occur predominantly in patients with advanced liver disease, active bleeding or technically demanding procedures. Optimal outcomes therefore depend on technical proficiency, sound clinical judgement and prompt recognition of complications.[42]

Adequate resuscitation should precede emergency endoscopy, and procedures should be performed by experienced endoscopists with appropriate assistance and equipment. Good visualisation is essential for accurate band placement and complete identification of bleeding varices.[43] The target varix should be suctioned into the cap until a red-out is achieved, with suction maintained until band deployment. However, excessive suction with circumferential mucosal capture and repeated banding at the same level should be avoided to minimise the risk of stricture formation.[25,44] Careful inspection of the ligation device before and after deployment, including confirmation of endoscope compatibility, further reduces device-related complications.[43]

Following EVL, patients should be monitored for persistent chest pain, dysphagia, fever or recurrent bleeding, which may indicate PBUB, obstruction or perforation.[44] Early endoscopic reassessment and cross-sectional imaging should be undertaken when significant complications are suspected. Proton pump inhibitors may promote ulcer healing and reduce PBUB, although they do not prevent ulcer formation.[18] Persistent or recurrent bleeding despite appropriate endoscopic therapy should prompt consideration of rescue interventions such as TIPS.[25,44]

Meticulous technique, adequate training, appropriate device selection, vigilant post-procedure assessment and timely intervention remain the cornerstones of preventing EVL-related complications while maintaining the excellent efficacy of variceal ligation.[42]

Conclusion

Endoscopic variceal ligation remains the treatment of choice for oesophageal varices because of its high efficacy and favourable safety profile. Although most adverse events are minor and self-limiting, serious complications – including post-banding ulcer bleeding, obstruction, stricture, perforation and device-related failures – may occur and require early recognition and prompt management. Reported complication rates vary considerably because of inconsistent definitions and heterogeneous reporting, limiting meaningful comparison between studies. Greater standardisation of adverse event reporting, together with meticulous endoscopic technique, appropriate patient selection and familiarity with ligation devices, should further improve procedural safety. A better understanding of the mechanisms, prevention and management of EVL-related complications will enhance patient outcomes while

supporting continued refinement of endoscopic therapy for portal hypertension.

Conflict of interest

The authors declare no conflict of interest.

ORCID

JEJ Krige https://orcid.org/0000-0002-7057-9156
SR Thomson https://orcid.org/0000-0002-9485-997X

REFERENCES

1. Aggeletopoulou I, Konstantakis C, Manolakopoulos S, Triantos C. Role of band ligation for secondary prophylaxis of variceal bleeding. World J Gastroenterol. 2018;24(26):2902-17. https://doi.org/10.3748/wjg.v24.i26.2902.
2. Tait IS, Krige JE, Terblanche J. Endoscopic band ligation of oesophageal varices. Br J Surg. 1999;86(4):437-46. https://doi.org/10.1046/j.1365-2168.1999.01109.x.
3. Krige JE, Shaw JM, Bornman PC. The evolving role of endoscopic treatment for bleeding oesophageal varices. World J Surg. 2005;29(8):966-73. https://doi.org/10.1007/s00268-005-0138-2.
4. Krige JEJ, Bornman PC, Shaw JM, Apostolou C. Complications of endoscopic variceal therapy. S Afr J Surg. 2005;43(4):177-88, 190-4. PMID: 16440594.
5. Krige J, Jonas E, Kotze U, et al. Defining the advantages and exposing the limitations of endoscopic variceal ligation in controlling acute bleeding and achieving complete variceal eradication. World J Gastrointest Endosc. 2020;12(10):365-77. https://doi.org/10.4253/wjge.v12.i10.365.
6. Nass KJ, Zwager LW, van der Vlugt M, et al. Novel classification for adverse events in GI endoscopy: The AGREE classification. Gastrointest Endosc. 2022;95(6):1078-85.e8. https://doi.org/10.1016/j.gie.2021.11.038.
7. Krige JE, Jonas EG, Bernon MM. The safety profile of endoscopic variceal ligation in patients with oesophageal varices. Hepatol Int. 2024;18(3):1060-1. https://doi.org/10.1007/s12072-023-10619-5.
8. Nijhawan S, Rai RR. Does post-ligation oesophageal ulcer healing require treatment? Lancet. 1994 Jan 8;343(8889):116-7. https://doi.org/10.1016/S0140-6736(94)90844-3.
9. Arasu S, Liaquat H, Suri J, Ehrlich AC, Friedenberg FK. Incidence and risk factors of dysphagia after variceal band ligation. Clin Mol Hepatol. 2019;25(4):374-80. https://doi.org/10.3350/cmh.2019.0019.
10. Karki B, Shrestha R, Paudel BN, et al. Outcome of post EVL treatment with sucralfate and PPI versus PPI alone. Nepal Med J. 2019;2(1):25-9. https://doi.org/10.3126/nmj.v2i2.24930.
11. Shaheen NJ, Stuart E, Schmitz SM, et al. Pantoprazole reduces the size of post-banding ulcers after variceal band ligation: A randomised, controlled trial. Hepatology. 2005;41(3):588-94. https://doi.org/10.1002/hep.20593.
12. Tierney A, Toriz BE, Mian S, Brown KE. Interventions and outcomes of treatment of post-banding ulcer haemorrhage after endoscopic band ligation: A single-centre case series. Gastrointest Endosc. 2013 Jan;77(1):136-40.e1. https://doi.org/10.1016/j.gie.2012.08.031.
13. Tosetti G, Farina E, Caccia R, Dell'Era A, Primignani M. Post-banding ulcer bleeding in the elective setting: Are there any risk factors? Dig Liver Dis. 2021;53(5):658-60. https://doi.org/10.1016/j.dld.2021.01.016.
14. Young MF, Sanowski RA, Rasche R. Comparison and characterisation of ulcerations induced by endoscopic ligation of oesophageal varices versus endoscopic sclerotherapy. Gastrointest Endosc. 1993;39(2):119-22. https://doi.org/10.1016/S0016-5107(93)70049-8.
15. Vanbiervliet G, Giudicelli-Bornard S, Piche T, et al. Predictive factors of bleeding related to post-banding ulcer following endoscopic variceal ligation in cirrhotic patients: A case-control study. Aliment Pharmacol Ther. 2010;32(2):225-32. https://doi.org/10.1111/j.1365-2036.2010.04331.x.
16. Jamwal K, Kumar M, Maiwall R, et al. Post EVL ulcer bleeding: A new classification and outcomes. Gastroenterology. 2017;152(5):S908. https://doi.org/10.1016/S0016-5085(17)33101-3.
17. Elbahr O, Kamal A, Alsebaey A, et al. Self-expandable metallic stents (SEMS) in oesophageal varices post-band ulcer refractory bleeding: A retrospective study. Egypt Liver J. 2021;11(1):30. https://doi.org/10.1186/s43066-021-00100-z.
18. Kang SH, Yim HJ, Kim SY, et al. Proton pump inhibitor therapy is associated with reduction of early bleeding risk after prophylactic endoscopic variceal band ligation: A retrospective cohort study. Medicine (Baltimore). 2016;95(8):e2903. https://doi.org/10.1097/MD.0000000000002903.
19. Garcia Tsao G, Abraldes JG, Berzigotti A, Bosch J. Portal hypertensive bleeding in cirrhosis. Hepatology. 2017;65(1):310-35. https://doi.org/10.1002/hep.28906. Epub 2016 Dec 1. Erratum in: Hepatology. 2017;66(1):304. https://doi.org/10.1002/hep.29169.
20. Terblanche J, Stiegmann GV, Krige JE, Bornman PC. Long-term management of variceal bleeding: The place of varix injection and ligation. World J Surg. 1994;18(2):185-92. https://doi.org/10.1007/BF00294399.
21. De Franchis R, Bosch J, Garcia-Tsao G, Reiberger T, Ripoll C. Baveno VII: Renewing consensus in portal hypertension. J Hepatol. 2022;76(4):959-74. https://doi.org/10.1016/j.jhep.2021.12.022.
22. Krige JE, Jonas EG, Bernon MM. Quality indicators and the safety profile of endoscopic intervention in patients with bleeding oesophageal varices. Hepatology. 2025;81(2):E40-E41. https://doi.org/10.1097/HEP.0000000000001153.
23. Lee SW, Lee TY, Chang CS. Independent factors associated with recurrent bleeding. Dig Dis Sci. 2009;54(5):1128-34. https://doi.org/10.1007/s10620-008-0454-0.
24. Polski JM, Brunt EM, Saeed ZA. Chronology of histological changes after band ligation of oesophageal varices in humans. Endoscopy. 2001;33(5):443-7. https://doi.org/10.1055/s-2001-14259.
25. Krige JEJ, Thomson SR. Endoscopic therapy in the management of oesophageal and gastric varices. 7th ed. In: Nyhus R, Baker J, Fischer E, editors. Mastery of Surgery; 2015. p. 1616-29.
26. Fass R, Landau O, Kovacs TO, Ippoliti AF. Oesophageal motility abnormalities in cirrhotic patients before and after endoscopic variceal treatment. Am J Gastroenterol. 1997;92(6):941-6. PMID: 9177506.
27. Jalil A, Hammoud G, Ibdah JA, Samiullah S. Removal of oesophageal variceal bands to salvage complete oesophageal obstruction. Clin Endosc. 2018;51(5):491-4. https://doi.org/10.5946/ce.2018.011.
28. Zhang WS, Yao YR. Complete oesophageal obstruction after endoscopic variceal ligation. Br J Hosp Med (Lond). 2019;80(4):230-1. https://doi.org/10.12968/hmed.2019.80.4.230.

29. Nikoloff MA, Riley TR 3rd, Schreibman IR. Complete oesophageal obstruction following endoscopic variceal ligation. Gastroenterol Hepatol (NY). 2011;7(8):557-9. PMID: 22298995; PMCID: PMC3264943.
30. Hilmi I, Goh KL, Hadzri MH. A tight oesophageal stricture secondary to a misplaced band and its management. Acta Gastroenterol Belg. 2011;74(2):342-4.
31. Schmitz RJ, Sharma P, Badr AS, Qamar MT, Weston AP. Incidence and management of oesophageal stricture formation, ulcer bleeding, perforation, and massive hematoma formation from sclerotherapy versus band ligation. Am J Gastroenterol. 2001;96(2):437-41. https://doi.org/10.1111/j.1572-0241.2001.03460.x.
32. Schoonbroodt D, Zipf A, Jung M. Local necrosis and fatal perforation of oesophagus after endoscopic ligation. Lancet. 1994;344(8933):1365. https://doi.org/10.1016/S0140-6736(94)90723-4.
33. Elwakil R, Al Breedy AM, Gabal HH. Effect of endoscopic variceal obliteration by band ligation on portal hypertensive gastro-duodenopathy: Endoscopic and pathological study. Hepatol Int. 2016;10(6):965-73. https://doi.org/10.1007/s12072-016-9711-z.
34. Elnaser SS, El-Ebiary S, Bastawi MB, Shafei AL, Abd-Elhafee A. Effect of endoscopic injection sclerotherapy and variceal ligation on development of portal hypertensive gastropathy and duodenopathy. J Egypt Soc Parasitol. 2005;35(1):253-64. PMID: 15881011.
35. Stiegmann GV, Cambre T, Sun J. A new endoscopic elastic band ligating device. Gastrointest Endoscopy. 1986;32(3):230-3. https://doi.org/10.1016/S0016-5107(86)71815-4.
36. Stiegmann GV, Goff JS, Michaletz-Onody PA, et al. Endoscopic sclerotherapy as compared with endoscopic ligation for bleeding oesophageal varices. N Eng J Med. 1992;326(23):1527-32. https://doi.org/10.1056/NEJM199206043262304.
37. Tatro ES, Adler DG. Device failures and patient-related adverse events associated with endoscopic variceal ligation devices: A MAUDE database analysis. IGIE. 2023;2(3):319-23. https://doi.org/10.1016/j.igie.2023.05.002.
38. Syn WK, Skander MP, Ahmed MM. Variceal ligator cap dislodgment, and retrieval techniques. Endoscopy. 2003;35(9):796; author reply 796-7.
39. Leung CS, Chan CW, Chow WH, Chan KH, Kwan WK. A potentially serious disadvantage of multiband device over conventional ligation using an overtube. Endoscopy. 2003;35(2):190. https://doi.org/10.1055/s-2003-37006.
40. Tuncer K, Ozütemiz O. An unusual complication of oesophageal variceal band ligation: Iatrogenic oesophageal foreign body. Endoscopy. 2003;35(5):460. https://doi.org/10.1055/s-2003-38762.
41. Mogrovejo E, Manickam P, Polidori G, Cappell MS. Dislodgement of variceal bands after oesophageal balloon tamponade. Ann Hepatol. 2014;13(6):832-7. https://doi.org/10.1016/S1665-2681(19)30988-3.
42. Krige JEJ, Botha JF, Bornman PC. Endoscopic variceal ligation for bleeding oesophageal varices. Dig Endosc. 1999;11(4):315-20. https://doi.org/10.1111/j.1443-1661.1999.tb00015.x.
43. Krige JEJ, Terblanche J, Bornman PC. Complications of endoscopic variceal sclerotherapy. 2nd ed. In: Sivak MV, editor. Gastroenterologic Endoscopy. WB Saunders: New York; 1999.
44. Krige JEJ, Jonas E, Bernon MM. Endoscopic therapy in the management of oesophageal and gastric varices. 8th ed. In: Nyhus R, Baker J, Fischer E, editors. Mastery of Surgery; 2024.

S Afr J Surg. 2026;64:322-330. Online first
https://doi.org/10.36303/SAJS.05104

Open Access article distributed under the terms of the Creative Commons Attribution-Non-Commercial Works 4.0 South Africa License (CC BY NC)
https://creativecommons.org/licenses/by-nc/4.0/

S Afr J Surg
ISSN: 0038-2361 eISSN: 2078-5151
© 2026 The Author(s)
REVIEW

An analysis of adverse oesophageal events after endoscopic variceal ligation

Supplementary Table SI: Complications after endoscopic variceal banding for bleeding oesophageal varices – Search strategy

PubMed

Search	Query	Records retrieved
#1	"Esophageal and Gastric Varices/therapy"[Mesh]	7 792
#2	"varice"[All Fields] OR "variceal"[All Fields] OR "varicose veins"[MeSH Terms] OR ("varicose"[All Fields] AND "veins"[All Fields]) OR "varicose veins"[All Fields] OR "varices"[All Fields] OR ("oesophageal varices"[All Fields] OR "esophageal and gastric varices"[MeSH Terms] OR ("esophageal"[All Fields] AND "gastric"[All Fields] AND "varices"[All Fields]) OR "esophageal and gastric varices"[All Fields] OR ("esophageal"[All Fields] AND "varices"[All Fields]) OR "esophageal varices"[All Fields]) OR ("oesophageal varices"[All Fields] OR "esophageal and gastric varices"[MeSH Terms] OR ("esophageal"[All Fields] AND "gastric"[All Fields] AND "varices"[All Fields]) OR "esophageal and gastric varices"[All Fields] OR ("esophageal"[All Fields] AND "varices"[All Fields]) OR "esophageal varices"[All Fields])	40 369
#3	(("endoscope s"[All Fields] OR "endoscoped"[All Fields] OR "endoscopes"[MeSH Terms] OR "endoscopes"[All Fields] OR "endoscope"[All Fields] OR "endoscopical"[All Fields] OR "endoscopically"[All Fields] OR "endoscopy"[MeSH Terms] OR "endoscopy"[All Fields] OR "endoscopic"[All Fields]) AND ("varice"[All Fields] OR "variceal"[All Fields] OR "varicose veins"[MeSH Terms] OR ("varicose"[All Fields] AND "veins"[All Fields]) OR "varicose veins"[All Fields] OR "varices"[All Fields]) AND ("banded"[All Fields] OR "banding"[All Fields] OR "bandings"[All Fields])) OR (("endoscope s"[All Fields] OR "endoscoped"[All Fields] OR "endoscopes"[MeSH Terms] OR "endoscopes"[All Fields] OR "endoscope"[All Fields] OR "endoscopical"[All Fields] OR "endoscopically"[All Fields] OR "endoscopy"[MeSH Terms] OR "endoscopy"[All Fields] OR "endoscopic"[All Fields]) AND ("varice"[All Fields] OR "variceal"[All Fields] OR "varicose veins"[MeSH Terms] OR ("varicose"[All Fields] AND "veins"[All Fields]) OR "varicose veins"[All Fields] OR "varices"[All Fields]) AND ("ligate"[All Fields] OR "ligated"[All Fields] OR "ligates"[All Fields] OR "ligating"[All Fields] OR "ligation"[MeSH Terms] OR "ligation"[All Fields] OR "ligations"[All Fields])) OR (("endoscope s"[All Fields] OR "endoscoped"[All Fields] OR "endoscopes"[MeSH Terms] OR "endoscopes"[All Fields] OR "endoscope"[All Fields] OR "endoscopical"[All Fields] OR "endoscopically"[All Fields] OR "endoscopy"[MeSH Terms] OR "endoscopy"[All Fields] OR "endoscopic"[All Fields]) AND ("varice"[All Fields] OR "variceal"[All Fields] OR "varicose veins"[MeSH Terms] OR ("varicose"[All Fields] AND "veins"[All Fields]) OR "varicose veins"[All Fields] OR "varices"[All Fields]) AND ("band"[Journal] OR "band"[All Fields]) AND ("ligate"[All Fields] OR "ligated"[All Fields] OR "ligates"[All Fields] OR "ligating"[All Fields] OR "ligation"[MeSH Terms] OR "ligation"[All Fields] OR "ligations"[All Fields])) OR "EVL"[All Fields] OR "EL"[All Fields]	147 690
#4	#1 OR #2	40 369
#5	#4 AND #3	**2 085**

PMC

Search	Query	Records retrieved
#1	(("Esophageal and Gastric Varices/therapy"[Mesh]) OR (varices OR oesophageal varices OR esophageal varices)) AND (endoscopic variceal banding OR endoscopic variceal ligation OR endoscopic variceal band ligation OR "EVL" OR "EL")	3 917
#2	(complications OR side-effects OR adverse effects OR reaction OR reactions OR contra-indications OR treatment failure)	4 414 636
#3	#1 AND #2	**3 524**

Web of Science

Search	Query	Records retrieved
#1	ALL=(varices OR oesophageal varices OR esophageal varices)	14 960
#2	ALL=(endoscopic variceal banding OR endoscopic variceal ligation OR endoscopic variceal band ligation OR "EVL" OR "EL")	651 202
#3	#1 AND #2	**1 304**

SCOPUS

Search	Query	Records retrieved
#1	ALL(varices OR "oesophageal varices" OR "esophageal varices")	53 250
#2	ALL("endoscopic variceal banding" OR "endoscopic variceal ligation" OR "endoscopic variceal band ligation")	2 845
#3	#1 AND #2	**2 614**

PRIMO

Search	Query	Records retrieved
#1	*ANY FIELD* varices OR (oesophageal varices) OR (esophageal varices)	48 983
#2	*ANY FIELD* (endoscopic variceal banding) OR (endoscopic variceal ligation) OR (endoscopic variceal band ligation)	6 659
#3	#1 AND #2	**6 053**
	Apply filter to include only articles, conference proceedings, reports	**5 845**