*S Afr J Surg.* 2025;63:118-119. Online first
https://doi.org/10.36303/SAJS.02252

Open Access article distributed under the terms of the Creative Commons Attribution-Non-Commercial Works 4.0 South Africa License (CC BY NC)
http://creativecommons.org/licenses/by-nc-nd/4.0

S Afr J Surg
ISSN 038-2361
© 2025 The Author(s)

CASE REPORT

# A rare condition that may be confused with testicular torsion in children – testicular band

**A Hanbeyoglu, T Tartar, U Bakal, T Akkuş, A Kazez**

*Department of Paediatric Surgery, Faculty of Medicine, Firat University, Turkey*

***Corresponding author, email:*** *tugaytartar@gmail.com*

**Summary**
Testicular torsion (TT) is the most important cause of acute scrotum in children, which can lead to testicular loss and requires emergency surgery. Fibrotic bands around the epididymis/spermatic cord that can cause severe testicular ischemia are extremely rare. The origin of these bands is unknown. Although scrotal colour doppler ultrasonography (CDUS) has an important place in the diagnosis of TT, it may be insufficient in the diagnosis of the bands. We aimed to present two rare cases in which a band was detected surrounding the distal spermatic cord and causing testicular ischemia in patients who had no previous scrotal pathology and emergency surgery was performed considering TT.
**Keywords:** child, testicular torsion, testicular band, acute scrotum, testicular surgery

## Case reports

### *Case 1*

A two-year-old male patient was admitted with complaints of pain and swelling in the left testicle for one day. His past medical history was unremarkable. Physical examination revealed left testicular tenderness, swelling and thickening of the inguinal canal. The testicle was located at a high scrotal position and there was no cremasteric muscle reflex. Routine laboratory tests were unremarkable. On scrotal colour doppler ultrasonography (CDUS), bilateral testicular parenchyma was seen as a homogeneous echo. The left epididymis was increased in size, and normal vascular flow. A non-communicating hydrocele in the left scrotum was also identified. Epididymo-orchitis and partial torsion were considered in the preliminary diagnosis. Physical examination and radiological suspicion led to scrotal exploration. On exploration, a band extending from the inguinal canal to the intravaginal space was seen to make a full turn around the distal spermatic cord and compress the pampiniform plexus (Figure 1). The band was excised, and testicular blood supply was restored. There was no inguinal hernia or bell clapper anomaly. No complications were encountered during the 30-month follow-up period.

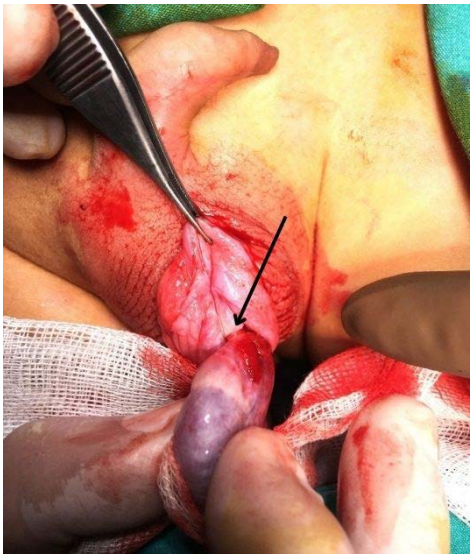

*Figure 1: Band surrounding the pampiniform plexus on scrotal exploration (black arrow).*

### *Case 2*

A 13-day-old male patient was admitted with a three-day history of bruising and swelling in the left scrotum. His past medical history was unremarkable. Physical examination revealed swelling in the left testicle and ecchymosis in the scrotum. There was no skin or subcutaneous oedema. Routine laboratory tests were unremarkable. On scrotal CDUS, the left testicular parenchyma had decreased echogenicity, heterogeneous appearance and no vascular

*Figure 2: Compression area formed by the band on the pampiniform plexus (forceps tip indicated by black arrow).*

flow could be seen. On scrotal exploration, the testicle had an ischemic appearance due to a fibrotic band but there was no torsion. After excision of the fibrotic band ring that disrupted the blood supply in the upper part of the testicle, testicular reperfusion was achieved (Figure 2). There was no inguinal hernia but there was bell clapper anomaly. No complications were encountered during the two-year follow-up period.

## Discussion

Testicular torsion (TT) is the most important cause of acute scrotum in children, which may lead to testicular loss and requires emergency surgery. Clinical findings include testicular swelling and sudden scrotal pain. It is frequently observed in the neonatal and adolescent age group.[1] Scrotal CDUS is important in the diagnosis. Fibrotic bands around the spermatic cord or epididymis are very rare and may cause ischemia.[2] The aetiology of fibrotic bands is not clear.

Acute scrotum is defined as an emergency condition characterised by sudden painful swelling of the scrotum with nausea and vomiting. TT requiring urgent surgical intervention should be differentiated in a patient presenting with acute scrotum. Usually, the hallmark of TT on physical examination is a testicle that is "elevated" due to shortening of the spermatic cord. The characteristic feature of TT in children is the absence of cremasteric muscle reflex.[3] In the first case presented, since no cremasteric muscle reflex was obtained, it was evaluated in favour of torsion.

The differential diagnosis of acute scrotum includes various conditions including TT, epididymitis, orchitis, trauma, idiopathic scrotal oedema, inguinal hernia, hydrocele, varicocele, tumour and torsion of testicular appendages.[4]

The most important diagnostic method of an acute scrotum is a well-performed scrotal US and/or scrotal CDUS. Reports have stated the sensitivity and specificity of scrotal CDUS, performed in patients with acute scrotum at 88% and 98%, respectively.[5,6] However, scrotal CDUS was insufficient in the two cases presented to identify the bands causing ischemia around the spermatic cord or epididymis.

One publication described a case in which the band was identified by preoperative ultrasonography and testicular reperfusion was achieved by excision of the band at surgery. This patient had a history of epididymitis eight years previously, but it could not be explained whether the pathological band was formed due to epididymitis or a congenital structure.[2] There was no history of any inflammatory disease in the medical history of both patients we presented. During the operation, the vascular circulation of the testicles returned to normal with the excision of the bands, but no tissue sample could be obtained for pathological examination. Intraoperative pictures clearly show the fibrotic band around the distal cord. Since these bands were regular shaped and there was no history of inflammatory disease in the scrotum in both cases, we conclude these bands were congenital.

In conclusion, bands around the epididymis/spermatic cord are extremely rare and can cause severe testicular ischemia. Since the aetiology of these bands is unclear, intraoperative sampling for histopathologic examination is recommended. Although scrotal CDUS has an important place in the diagnosis of TT today, it may be insufficient in the diagnosis of bands. Emergency surgery should be performed in suspicious cases.

### *Conflict of interest*

The authors declare no conflict of interest.


### *Funding source*

No funding was required.


### *Ethical approval*

This article did not require ethical approval of any kind. Written informed consent was obtained from the parent of the patient who participated in this study.


### *ORCID*

A Hanbeyoglu https://orcid.org/0009-0004-9101-0411
T Tartar https://orcid.org/0000-0002-7755-4736
U Bakal https://orcid.org/0000-0002-5140-8618
T Akkuş https://orcid.org/0000-0002-2481-9614
A Kazez https://orcid.org/0000-0003-0440-3555


### REFERENCES


1. Chanchlani R, Acharya H. Acute scrotum in children: A retrospective study of cases with review of literature. Cureus. 2023;15(3):e36259. https://doi.org/10.7759/cureus.36259.
2. Artul S, Fahoum B, Nseir W, Habib G. Testicular ischemia due to a band around the spermatic cord. J Clin Imaging Sci. 2015;5:36. https://doi.org/10.4103/2156-7514.157856.
3. Rabinowitz R. The importance of the cremasteric reflex in acute scrotal swelling in children. J Urol. 1984;132(1):89-90. https://doi.org/10.1016/S0022-5347(17)49476-6.
4. Liu CC, Huang SP, Chou YH, et al. Clinical presentation of acute scrotum in young males. Kaohsiung J Med Sci. 2007;23(6):281-6. https://doi.org/10.1016/S1607-551X(09)70410-3.
5. Baker LA, Sigman D, Mathews RI, Benson J, Docimo SG. An analysis of clinical outcomes using colour doppler testicular ultrasound for testicular torsion. Paediatrics. 2000;105(3 Pt 1):604-7. https://doi.org/10.1542/peds.105.3.604.
6. Sharp VJ, Kieran K, Arlen AM. Testicular torsion - diagnosis, evaluation and management. Am Fam Physician. 2013;88:835-40.