African Journal of Laboratory Medicine
ISSN: (Online) 2225-2010, (Print) 2225-2002

Should bilateral (versus unilateral) bone marrow biopsies be routine in paediatric classical Hodgkin Lymphoma where PET-CT is unavailable?

Authors:
Stephanie J. Kennedy[1,2]
Mampoi T. Jonas[3,4]
Anne-Cecilia van Marle[1,2]
Jan du Plessis[3,4]

Affiliations:
[1]Department of Haematology and Cell Biology, School of Pathology, Faculty of Health Sciences, University of the Free State, Bloemfontein, South Africa

[2]Department of Haematology, National Health Laboratory Service, Universitas Academic Laboratory, Bloemfontein, South Africa

[3]Department of Paediatric Haematology-Oncology, Faculty of Health Sciences, University of the Free State, Bloemfontein, South Africa

[4]Department of Paediatric Haematology-Oncology, Universitas Academic Hospital, Bloemfontein, South Africa

Corresponding author:
Stephanie Kennedy
stephanie.kennedy@nhls.ac.za

Dates:
Received: 11 Nov. 2025
Accepted: 23 Feb. 2026
Published: 31 July 2026

Read online:
Scan this QR code with your smart phone or mobile device to read online.

Introduction: Paediatric classical Hodgkin Lymphoma (cHL) can be treated successfully with modern therapeutic regimens. In the context of risk-adapted treatment strategies, accurate staging and risk stratification are crucial to improve outcomes. Although fluorodeoxyglucose positron emission tomography-computed tomography (PET-CT) detects bone marrow (BM) involvement accurately in cHL and is recommended over BM biopsies in the staging of paediatric cHL, this imaging modality is not widely available in most African countries, and BM biopsies continue to be performed.

Case presentation: An 8-year-old HIV-negative boy from Lesotho was referred to the Universitas Academic Hospital Paediatric Oncology Unit, South Africa, in March 2024, with a 2-year history of a progressively enlarging neck mass, fever, loss of appetite, hepatosplenomegaly, and cytopenias. Bilateral BM aspirate and trephine biopsies revealed discrepant results: The right-sided biopsy showed only reactive features, whereas the left side confirmed a diagnosis of stage 4 cHL.

Management and Outcome: The child was initiated on the high-risk arm of the South African cHL treatment protocol. Owing to availability and cost constraints, a PET-CT could neither be done at diagnosis nor to evaluate his initial therapeutic response. Instead, repeat bilateral BM and CT investigations were performed to guide management as per the protocol. He completed all treatment and remains in complete remission 2 years later.

Conclusion: Delayed referral and diagnosis of paediatric cancers remain a problem in Africa and may contribute to advanced disease at presentation. In this child, correct staging and risk stratification of cHL ensured optimal treatment selection and a favourable outcome.

What this study adds: Bilateral, rather than unilateral BM biopsies should be considered for cHL staging where PET-CT is unavailable.

Keywords: bilateral bone marrow biopsies; paediatric classical Hodgkin Lymphoma staging; PET-CT; risk-adapted treatment; response assessment.

Introduction

Classical Hodgkin Lymphoma (cHL) is a common childhood cancer that can be treated successfully with modern therapeutic regimens.[1] In contrast with early-stage disease, which commonly responds to less toxic combinations of chemotherapy and involved field radiation, advanced-stage cHL requires extended cytotoxic therapy.[1] In the context of risk-adapted treatment strategies, accurate staging and risk stratification at diagnosis and follow-up are crucial to improve outcomes.[1]

Detection of bone marrow (BM) involvement assigns patients to Lugano stage 4, which influences treatment and prognosis.[1,2] Fluorodeoxyglucose positron emission tomography-computed tomography (PET-CT) has become the most valuable tool to assess the extent of cHL at diagnosis, assist with optimal treatment selection, and assess response to treatment, replacing the need for histopathological analysis for BM involvement.[2,3,4] However, in resource-restricted settings, access to PET-CT remains limited, and assessment of BM biopsies remains an important staging strategy.[2,4,5,6] Unlike PET-CT, which examines the entire BM, histopathological analysis is limited

How to cite this article: Kennedy SJ, Jonas MT, Van Marle A-C, Du Plessis J. Should bilateral (versus unilateral) bone marrow biopsies be routine in paediatric classical Hodgkin Lymphoma where PET-CT is unavailable? Afr J Lab Med. 2026;15(1), a3111. https://doi.org/10.4102/ajlm.v15i1.3111

Copyright: © 2026. The Authors. Licensee: AOSIS. This work is licensed under the Creative Commons Attribution 4.0 International (CC BY 4.0) license (https://creativecommons.org/licenses/by/4.0/).

to the small portion of the BM that was biopsied, and may miss focal involvement.[1,2] However, compared with unilateral biopsies, bilateral BM biopsies may improve the detection of BM involvement by cHL by up to 22%.[7,8]

Anecdotally, bilateral diagnostic and staging BM biopsies for cancers are performed routinely in paediatric oncology units in South Africa. To illustrate the value of bilateral BM biopsies in the diagnosis and staging of paediatric cHL where PET-CT is unavailable, we report a case of stage 4 cHL with discrepant bilateral BM results following a 2-year diagnostic delay.

Ethical considerations

Ethics approval for this case study was obtained from the Health Science Research Ethics Committee of the University of the Free State (UFS-HSD2025/0278/2608). The child's mother provided written informed consent, while the child provided written informed assent for publication of this case study.

Case presentation

An 8-year-old HIV-negative boy from Lesotho was referred to the Universitas Academic Hospital Paediatric Oncology Unit, Bloemfontein, South Africa, in March 2024, with a 2-year history of a progressively enlarging neck mass, fever, loss of appetite, and massive hepatosplenomegaly. Histology from an excision lymph node biopsy performed in Lesotho revealed morphologic features suggestive of cHL: partial replacement of nodal architecture by large tumour cells with prominent eosinophilic nucleoli and ample amophilic cytoplasm, surrounded by an inflammatory cell infiltrate. However, no immunohistochemistry was performed, and a definitive diagnosis could not be confirmed. Upon arrival in Bloemfontein, the child's full blood count showed anaemia (haemoglobin 9.6 g/dL) and thrombocytopenia (platelet count 65×10^9/L) with a normal white cell count (3.67×10^9/L). The cytopenias were suggestive of BM metastasis, and bilateral diagnostic and staging BM aspirate and trephine biopsies were performed subsequently over the left and right superior iliac crests; both good quality with minimal trauma in the form of plasma extravasation and intramedullary bleeding. The right-sided trephine biopsy (25 mm in length) showed reactive features with no evidence of neoplasm (Figure 1a). In contrast, the left-sided biopsy (15 mm long) showed a distinct localised area of fibrohistiocytic change (Figure 1b). Embedded in this inflammatory background were several large lymphoma cells with prominent eosinophilic nucleoli, confirmed to be Hodgkin-Reed-Sternberg cells with immunohistochemistry (CD30+/CD45-/PAX5+/CD15+/EBER-ISH+/CD20-/CD3-) (Figure 1b inserts). A diagnosis of stage 4 cHL was made on this BM biopsy.

Management and outcome

Based on his advanced stage and high-risk presentation, the patient was initiated on the high-risk arm of the South African cHL treatment protocol. Until the end of 2025, Universitas Academic Hospital did not have a PET-CT scanner and, owing to cost constraints, a limited number of private referrals were permitted for PET-CT at a given interval. Consequently, a PET-CT could neither be done at diagnosis nor after two induction cycles of doxorubicin, bleomycin, vinblastine, and dacarbazine (ABVD) to evaluate response. Instead, repeat bilateral BM investigations and surveillance computerised tomography (CT) were performed, demonstrating no residual BM involvement, but CT showed < 50% shrinkage of measurable disease. As per the protocol, a partial response with < 50% reduction of measurable disease in any one axis or Deauville score 4 or 5 was defined as a 'slow early response'.[5] Accordingly, the patient, being high-risk, received four cycles of cyclophosphamide, vincristine sulphate, prednisone and dacarbazine, and involved field radiotherapy.[5] At this stage, an interim PET-CT could be obtained for revaluation, and demonstrated no evidence of active lymphoma. The child completed all treatment and remains in complete remission 2 years later.

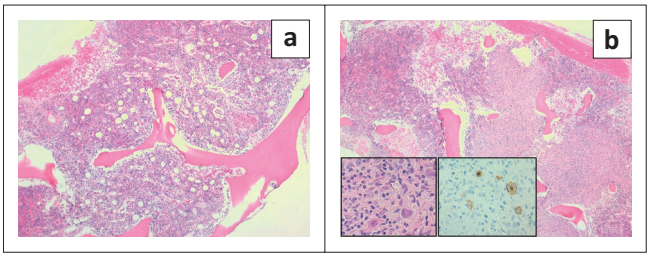

FIGURE 1: Bilateral diagnostic and staging bone marrow trephine biopsies of an 8-year-old boy, in whom stage 4 classical Hodgkin Lymphoma was diagnosed on the left-sided biopsy, while the right-sided biopsy did not demonstrate the lymphoma. Bone marrow biopsies were performed by the Paediatric Oncology Unit, Universitas Academic Hospital, Bloemfontein, South Africa, on 06 March 2024 and microscopically evaluated by the National Health Laboratory Service Universitas Academic Laboratory Haematology Department, Bloemfontein, South Africa. (a) The right-sided trephine biopsy showed reactive features but no evidence of neoplasm. (b) The left-sided trephine biopsy demonstrated a distinct localised area of fibrohistiocytic change containing Hodgkin-Reed-Sternberg cells (insert left) that were CD30 positive with Golgi accentuation (insert right). (Haematoxylin and Eosin, 5x objective; inserts in (b), 50x objective. Axiocam ERc 5 s [Zeiss®]).

Discussion

This case highlights the value of bilateral over unilateral BM biopsies in the diagnosis and staging of cHL where PET-CT is unavailable. In addition, it provides insight into some of the diagnostic and treatment challenges of paediatric cHL in South Africa.

Standardised cHL guidelines have been shown to improve survival in paediatric cHL.[9] However, these guidelines were created for use in high-income countries with adequate access to resources such as imaging modalities, salvage therapies, and excellent supportive care, but are used frequently without adaptation in low- and middle-income countries.[5,9]

Bilateral versus unilateral BM biopsies in cHL where PET-CT is unavailable

Geel et al.[5] recently demonstrated improved survival of children and adolescents with cHL in South Africa, an upper middle-income country, who were treated on a harmonised

protocol that encouraged risk-stratified, response-adapted treatment. The authors acknowledged that BM biopsies are no longer required for paediatric cHL when PET-CT is available for staging and response assessment.[2,4,5] However, since most African countries do not have access to PET-CT, they continue to recommend BM biopsies and surveillance CT in resource-restricted settings.[5] No specific recommendation was made regarding bilateral BM biopsies.

The Lugano classification, which omits routine BM biopsy staging in cHL, recommends a unilateral 25 mm BM biopsy where this is required in the absence of PET-CT.[4] International Council for Standardization in Hematology guidelines for the standardisation of BM specimens and reports recommend a minimum biopsy length of 20 mm, and suggest that bilateral BM biopsies may be performed to increase the yield of detecting focal lesions.[10] In this patient, the right-sided biopsy, which had an adequate length of 25 mm, showed only reactive features. The left-sided biopsy (15 mm) did not meet the recommended biopsy length requirements. Nevertheless, focal BM involvement by cHL was demonstrated on this side. These findings suggest that not only biopsy length, but also laterality may increase the yield of detecting focal BM lesions, and provides anecdotal support for the International Council for Standardization in Hematology suggestion to perform bilateral BM biopsies.

In addition to the anecdotal nature of a single case report, the lack of comparator data in the form of a PET-CT at initial staging limits the definitive value and generalisability of our observations. However, the value of bilateral BM biopsies in the staging of cancers has been demonstrated in several studies, including a local study by Van Marle et al.[7,8,11,12] Of the 118 paediatric cancer patients included in this study, 28 patients had BM metastases, of which five (17.8%) had discrepant left and right BM involvement.[11] Two of the five discrepant cases (40%) were children with cHL.[11] Larger studies have documented discrepant BM involvement by lymphoma in 39% – 43% of cHL, and 9% – 22% of NHL.[7,8] Wang et al.[8] included 362 patients with cHL in their study. Of the 36 BM specimens (9.9%) that demonstrated involvement by cHL, 22/36 specimens (61%) showed bilateral involvement, while 14/36 specimens (39%) showed only unilateral involvement. Of the 97 patients with cHL included in the study by Brunning et al.,[7] seven patients had BM involvement and in three patients (43%) tumour was detected on only one side. In contrast with these studies, unilateral BM involvement was less frequent in a single-centre retrospective South African study by Phillips and Opie[6]: 10.7% of cHL with BM involvement (3.8% of all cHL; $n = 6$) and 7.2% of NHL with BM involvement (3.2% of all NHL; $n = 19$). Another interesting observation from this study was the rate of BM involvement (35.7%) in newly diagnosed cHL ($n = 157$), which far exceeded the developed world rate of 5%.[6] Late presentation at diagnosis and initial misdiagnosis as tuberculosis were proposed as possible explanations.[6]

Ultimately, larger prospective studies are needed to validate current recommendations about BM biopsy length and laterality in the setting of paediatric cHL where PET-CT is unavailable.

Diagnostic and treatment challenges of paediatric cHL in South Africa

The late and advanced stage of presentation of our patient is not unique in the South African context. Geel et al.[5] reported that 87/132 (66%) of the children with cHL in South Africa presented with high-risk disease and advanced clinical stage. These observations may, in part, be explained by the delayed diagnosis of paediatric cancers in resource-restricted settings.[13]

Prospective data on cHL survival from other African countries are minimal.[5] Disparities in survival rates in childhood cancer are wide, ranging from 30% in low- and middle-income countries to 80% in high-income countries.[13] In this context, the World Health Organization's Global Initiative for Childhood Cancer focuses on six index cancers, including cHL.[14] Factors that contribute to the global differences in cancer outcomes in children include access to diagnostics or therapeutics, human resources, financial barriers, lack of supportive care, and more advanced stages at diagnosis in low- and middle-income countries.[15] Cotache-Condor et al.[13] found the barriers to timely childhood cancer care to be multifactorial across the continuum of care, with key determinants including geographic, social, financial, health system, and health policy factors. All of these factors were barriers that contributed to the 2-year delay between symptom onset and referral of our patient from rural Lesotho to a paediatric oncology unit in South Africa. However, correct staging and risk stratification at diagnosis and follow-up ensured optimal treatment selection and a favourable outcome.

Teaching points

- Multifactorial barriers to timely childhood cancer care in Africa may contribute to advanced stage, including BM involvement, at presentation.
- Accurate staging and risk stratification is crucial to optimise outcomes in paediatric cHL.
- Bilateral BM biopsies should be considered where PET-CT is not available for staging of cHL.
- In addition to an adequate biopsy length (20 mm – 25 mm), bilateral over unilateral BM biopsies may increase the yield of detecting focal lesions in cHL.

Conclusion

Delayed diagnosis of paediatric cancers remains a problem in Africa and may contribute to advanced disease stage, including BM involvement, at diagnosis. Although PET-CT detects BM involvement accurately in cHL and is recommended over BM biopsies in the staging of paediatric cHL, this imaging modality is not available widely in most African countries, and BM biopsies continue to be

performed. This case suggests that bilateral BM biopsies may increase the yield of detecting focal lesions in cHL and should be considered in children, especially where advanced-stage cHL is suspected. However, the anecdotal nature of our case report and lack of comparator data in the form of a PET-CT at initial staging limits the definitive value and generalisability of our results. Further studies are needed to guide optimal strategies for the diagnosis, staging, and restaging of cHL in resource-restricted settings, with particular focus on the value of bilateral versus unilateral BM biopsies.

Acknowledgements

Competing interest

The authors declare that they have no financial or personal relationships that may have inappropriately influenced them in writing this article.

Author contributions

Stephanie J. Kennedy: Conceptualisation, Data curation, Formal analysis, Investigation, Methodology, Project administration, Resources, Validation, Visualisation, Writing – original draft, Writing – review & editing. Mampoi T. Jonas: Data curation, Writing – original draft, Writing – review & editing. Anne-Cecilia van Marle: Writing – review & editing. Jan du Plessis: Data curation, Writing – original draft, Writing – review & editing. All authors reviewed the article, contributed to the discussion of results, approved the final version for submission and publication, and take responsibility for the integrity of its findings.

Sources of support

This research received no specific grant from any funding agency in the public, commercial, or not-for-profit sectors.

Data availability

Data that support this case study are available from the corresponding author, Stephanie J. Kennedy, upon reasonable request.

Disclaimer

The views and opinions expressed in this article are those of the author and are the product of professional research. It does not necessarily reflect the official policy or position of any affiliated institution, funder, agency, or that of the publisher. The author is responsible for this article's findings, and content.

References

1. Voltin CA, Goergen H, Baues C, et al. Value of bone marrow biopsy in Hodgkin lymphoma patients staged by FDG PET: Results from the German Hodgkin Study Group trials HD16, HD17, and HD18. Ann Oncol. 2018;29(9):1926–1931. https://doi.org/10.1093/annonc/mdy250
2. Li Z, Li C, Chen B, et al. FDG-PET/CT versus bone marrow biopsy in bone marrow involvement in newly diagnosed paediatric lymphoma: A systematic review and meta-analysis. J Orthop Surg. 2021;16(1):482. https://doi.org/10.1186/s13018-021-02521-3
3. Hines-Thomas MR, Howard SC, Hudson MM, et al. Utility of bone marrow biopsy at diagnosis in pediatric Hodgkin's lymphoma. Haematologica. 2010;95(10):1691–1696. https://doi.org/10.3324/haematol.2010.025072
4. Cheson BD, Fisher RI, Barrington SF, et al. Recommendations for initial evaluation, staging, and response assessment of Hodgkin and Non-Hodgkin Lymphoma: The Lugano classification. J Clin Oncol. 2014;32(27):3059–3067. https://doi.org/10.1200/JCO.2013.54.8800
5. Geel J, Van Zyl A, Du Plessis J, et al. Improved survival of children and adolescents with classical Hodgkin lymphoma treated on a harmonised protocol in South Africa. Pediatr Blood Cancer. 2024;71(1):e30712. https://doi.org/10.1002/pbc.30712
6. Phillips L, Opie J. The utility of bone marrow sampling in the diagnosis and staging of lymphoma in South Africa. Int J Lab Hematol. 2018;40(3):276–283. https://doi.org/10.1111/ijlh.12782
7. Brunning RD, Bloomfield CD, McKenna RW, Peterson L. Bilateral trephine bone marrow biopsies in lymphoma and other neoplastic diseases. Ann Intern Med. 1975;82(3):365–366. https://doi.org/10.7326/0003-4819-82-3-365
8. Wang J, Weiss LM, Chang KL, et al. Diagnostic utility of bilateral bone marrow examination. Cancer. 2002;94(5):1522–1531. https://doi.org/10.1002/cncr.10364
9. Mauz-Körholz C, Metzger ML, Kelly KM, et al. Pediatric Hodgkin Lymphoma. J Clin Oncol. 2015;33(27):2975–2985. https://doi.org/10.1200/JCO.2014.59.4853
10. Lee SH, Erber WN, Porwit A, Tomonaga M, Peterson LC, Hematology ICSI. ICSH guidelines for the standardization of bone marrow specimens and reports. Int J Lab Hematol. 2008;30(5):349–364. https://doi.org/10.1111/j.1751-553X.2008.01100.x
11. Van Marle A-C, Coetzee I, Britz W, et al. The necessity of bilateral staging bone marrow examinations for paediatric solid tumours. S Afr J Oncol. 2022;6:a242. https://doi.org/10.4102/sajo.v6i0.242
12. Menon NC, Buchanan JG. Bilateral trephine bone marrow biopsies in Hodgkin's and non-Hodgkin's lymphoma. Pathology (Phila). 1979;11(1):53–57. https://doi.org/10.3109/00313027909063538
13. Cotache-Condor C, Kantety V, Grimm A, et al. Determinants of delayed childhood cancer care in low- and middle-income countries: A systematic review. Pediatr Blood Cancer. 2023;70(3):e30175. https://doi.org/10.1002/pbc.30175
14. World Health Organization. CureAll framework: WHO Global Initiative for Childhood Cancer. Increasing access, advancing quality, saving lives [homepage on the Internet]. Licence: CC BY-NC-SA 3.0 IGO. Geneva: World Health Organization; 2021 [cited 2025 Sep 08]. Available from: https://creativecommons.org/licenses/by-nc-sa/3.0/igo/
15. Atun R, Bhakta N, Denburg A, et al. Sustainable care for children with cancer: A Lancet Oncology Commission. Lancet Oncol. 2020;21(4):e185–e224. https://doi.org/10.1016/S1470-2045(20)30022-X