Wits Journal of Clinical Medicine, 2025, 7(3) 151–152 http://dx.doi.org/10.18772/26180197.2025.v7n3a10

Images in Medicine

Cyst in time: capturing the unique imaging of pulmonary hydatidosis

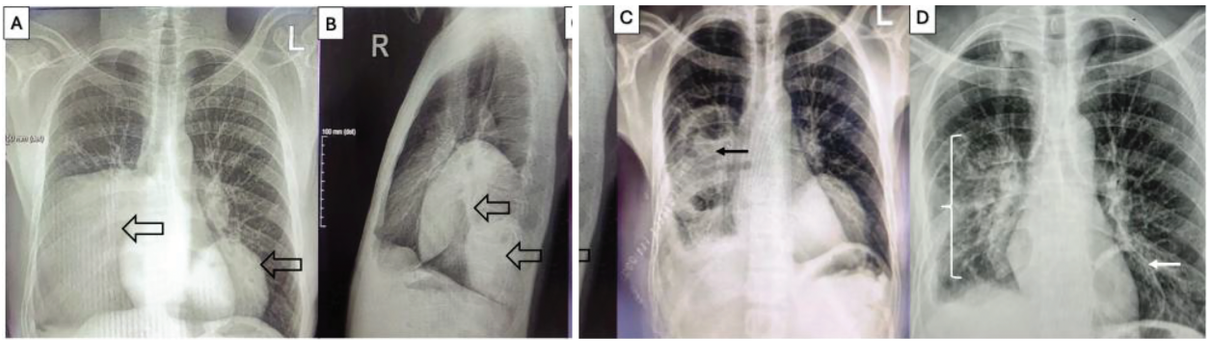

Zahra Kalla[1], Ismail S Kalla[1], Vivendra A Naidoo[1]

[1]Division of Pulmonology, Department of Internal Medicine, Faculty of Health Sciences, University of Witwatersrand

DESCRIPTION

A 31-year-old man presented with three months of pleuritic right-sided chest pain, exertional dyspnoea, dry cough, and low-grade fever. He reported prior travel to a rural farming area in the Eastern Cape two years earlier. Examination revealed decreased right basal breath sounds with stony dullness and normal vital signs. Preoperative chest radiography (CXR) demonstrated two solitary, smooth, well-circumscribed, homogeneous, rounded opacities in the right and left lower lobes, consistent with an intact pulmonary hydatid cyst (Panel A and Panel B, open arrows). He underwent cystectomy via thoracotomy, complicated by intraoperative cyst rupture, precipitating anaphylaxis with bronchospasm and hypotension. He required intubation, ventilation, and treatment with adrenaline, bronchodilators, and intravenous glucocorticoids in the intensive care unit. He stabilised and was extubated within 24 hours. Postoperative CXR demonstrated the classic water-lily sign, resulting from floating endocyst membranes, confirming the rupture (Panel C, black arrow). Echinococcus granulosus serology was positive, and cyst contents revealed hooklets and laminated membrane. Albendazole 400 mg twice daily was prescribed for three months, with liver function monitoring. He was discharged on day 7 and remained asymptomatic at six weeks, with radiographs showing resolving parenchymal changes from the ruptured cyst (Panel D, curly bracket), remnants of the cyst wall from the aspirated cyst (Panel D, white arrow), and no new cysts on abdominal ultrasound. Standard management of pulmonary hydatid disease includes surgical cystectomy combined with albendazole therapy, while PAIR (Puncture, Aspiration, Injection, Re-aspiration) may be used in selected cases. Preventive measures include personal hygiene, dog deworming, and safe livestock handling. This case illustrates the risk of intraoperative rupture and highlights the importance of meticulous surgical technique and preparedness for anaphylaxis.

Kalla.indd 151 22-10-2025 11:20:35

Kalla.indd 152 22-10-2025 11:20:35