*Wits Journal of Clinical Medicine,* 2025, 7(3) 117–122 http://dx.doi.org/10.18772/26180197.2025.v7n3a3

Research Article

# Patients with Anorectal malformations managed at a paediatric colorectal clinic in South Africa and requiring transition to adult care

Leila Hartford*, Giulia Brisighelli

Department of Paediatric Surgery and Johannesburg Paediatric Colorectal Clinic, School of Clinical Medicine, Faculty of Health Sciences, University of the Witwatersrand

***Corresponding Author:*** *leilahartford@gmail.com*

## ABSTRACT

**Background:** Anorectal malformations (ARMs) are congenital defects requiring lifelong management, including surgeries and bowel management strategies. Transitioning from pediatric to adult care presents challenges, especially in low- and middle-income countries (LMICs) like South Africa, where fragmented healthcare systems complicate the process. This study examines the management of ARM patients transitioning to adult care at a Paediatric Colorectal Clinic in South Africa, emphasizing the need for structured transition programs.

**Methods:** We reviewed the demographics, anatomical anomalies, surgical interventions, and outcomes of patients aged 9 years and older at the Johannesburg Paediatric Colorectal Clinic. Data was extracted from patient files and the clinic's database. Seventy patients met the inclusion criteria, and descriptive statistics were used for analysis.

**Results:** Of 277 ARM patients, 70 (25%) met the inclusion criteria. The majority were male (64%), with a median age of 13 years (range: 10 to 32). Common malformations included recto-vestibular fistula (15.7%) and cloaca (12.9%). A total of 315 procedures were performed, with a mean of 4.5 operations per patient. Functional outcomes showed 89% achieved voluntary bowel control; however, 64% of patients aged 16 or older required antegrade continence enema. Forty percent of these patients needed ongoing nephrology and urology care.

**Conclusion:** The findings highlight the complexity of ARM management, underscoring the need for a structured transition program to ensure continuity of care. Such programs are vital in low- and middle-income countries to improve long-term outcomes and quality of life for patients.

**Keywords:** Paediatric anorectal malformations, Transition from paediatric to adult care

## INTRODUCTION

Anorectal malformations (ARMs) represent a diverse group of congenital defects affecting the rectum and anus, with varying degrees of complexity. These conditions result from abnormal development during embryogenesis. They can range from relatively simple anomalies with a good prognosis to complex defects, which require multiple surgical interventions and lifelong bowel management.(1) ARMs are classified according to the anatomical type of the malformation, and they may involve associated anomalies affecting multiple organ systems, including the genitourinary, cardiac, skeletal, and spinal systems.(2,3) The occurrence of associated anomalies has been reported to be as high as 70% in this population of patients, further complicating their management.(4,5)

The management of ARMs typically begins in infancy, but continues through childhood, adolescence, and indeed into adulthood, with a combination of surgical interventions and bowel management strategies to establish social continence.(6) In the early stages, the surgical management generally involves either an initial colostomy followed by posterior sagittal anorectoplasty (PSARP) and ostomy closure or a primary PSARP procedure. Following this, social continence is achieved in most patients with bowel management strategies such as laxatives or washouts. In some patients, techniques like antegrade continence enema (ACE) are used to address long-term functional issues and maintain social continence.(7) The primary aim of these interventions is to restore functional anatomy and ensure the patient can achieve social continence and lead a good quality of life.(8)



Hartford.indd 117 22-10-2025 11:31:26

As patients with ARMs transition from paediatric to adult care, they face unique challenges due to the chronic and multi-system nature of their condition. This transition period is critical because, although most individuals with ARMs survive into adulthood, the move from paediatric to adult services often results in fragmentation of care and a lack of continuity, which can negatively impact both medical outcomes and quality of life.(9) A structured transition process is essential to address these challenges, as it helps coordinate ongoing care across multiple specialties, such as colorectal surgery, urology, nephrology, gastroenterology, and gynaecology.(10) Furthermore, healthcare systems in low- and middle-income countries (LMICs) are often less equipped to manage the long-term needs of these patients, placing additional strain on healthcare providers and complicating the process of transitioning care.(11)

Patients with ARMs typically require lifelong management. While the severity of the condition varies, many individuals face persistent issues with bowel and bladder control, necessitating multiple interventions and ongoing management well into adulthood. A significant proportion of patients with the more severe forms of ARMs may require multiple surgeries throughout their lifetime, such as ACE procedures or urological procedures, to manage the long-term sequelae of the condition.(12) The need for multidisciplinary involvement becomes even more pressing as patients transition through adolescence and into adulthood, where their medical and psychosocial needs may change.

Moreover, the limited number of specialised centres for ARMs in LMICs further complicates the transition process. In many countries, including South Africa, paediatric care is often provided in specialised paediatric hospitals or paediatric wards within general hospitals. In contrast, adult care is provided in separate adult-focused hospitals or departments. Within South Africa, this is further complicated by the dual healthcare system, where care is provided in both public and private facilities. These divisions of care can create a gap in continuity, especially for patients who have chronic conditions that require long-term management.(12) There is a growing recognition that transitioning ARM patients from paediatric to adult care should be a well-coordinated, patient-centered process, ensuring that these individuals receive the appropriate medical care tailored to their evolving needs as they age.

In recent years, the concept of a "transition program" has gained attention in the healthcare community, particularly in chronic disease management. These programs aim to provide a structured approach to transitioning patients by involving both paediatric and adult healthcare providers in the process, ensuring that patients receive consistent care across the lifespan.(6) Studies from both high-income and LMIC settings have shown that formalised transition programs can help reduce the gaps in care, improve patient outcomes, and enhance the quality of life for individuals with chronic conditions like ARMs.(13,14) However, challenges such as resource constraints, lack of trained personnel, and inadequate infrastructure continue to hinder the implementation of such programs, particularly in resource-limited settings.(11,15)

## METHODS

We conducted a review investigating the demographics, anatomical anomalies, surgical interventions, current management strategies, and outcomes of patients aged 9 years and older with ARMs treated at the Johannesburg Paediatric Colorectal Clinic (JPCC) at a large urban public hospital (Chris Hani Baragwanath Academic Hospital) in Soweto, South Africa. Although there is no consensus on the age at which transition to adult care should occur, it has been established that early identification of patients requiring transition of care is crucial to the long-term success of these programs.(6) In addition, identifying patients before puberty allows the healthcare team to prepare the patient for adolescence and the unique physical and psychosocial challenges these patients may face. Before commencement of this study, ethical clearance was obtained from the University of the Witwatersrand Human Research Ethics Committee (M190508). Data was extracted from patient files and the JPCC database. Descriptive statistics were performed in RedCap and Microsoft Excel.

## RESULTS

Out of 277 patients with ARMs that were assessed at JPCC, 70 (25%) met criteria for inclusion in the study. The majority (63%) were male, with a median age of 13 years, ranging from 9 to 32 years (Figure 1).

The most frequent types of malformations were recto-vestibular fistula (15.7%), cloaca (12.9%), recto-perineal fistula (11.4%), and imperforate anus with no fistula (11.4%) (Figure 2).

For 19 patients (27.1%), the anatomical type of ARM remains unknown, either because it was not documented or because the child was operated on at a different facility. The most common associated anomalies were renal (34%), followed by cardiac (17%) and spinal (16%) (Figure 3).

A total of 315 procedures were performed on 70 patients, with a mean of 4.5 operations per patient (range 1 to 13). These operations included 61 stomas (57 colostomies, two re-do colostomies, two ileostomies), 56 posterior sagittal anorectoplasties, 52 stoma closures, two posterior sagittal anorectal vaginal urethral plasties, 3 PSARP and total urogenital mobilsations, two anterior sagittal transrectal approach, 21 antegrade continence enema (ACE), six re-do ACE, 4 Mitrofanoffs, 13 other urological procedures, 32 examination under anaesthesia (11 with calibration/dilatation and 2 with stricturoplasty), and 29 cystoscopy and/or genitoscopy. (Figure 4)

In terms of functional outcomes, 19 of the 70 patients or their caregivers had completed a follow-up questionnaire on bowel function. 89% (17/19) of these had voluntary

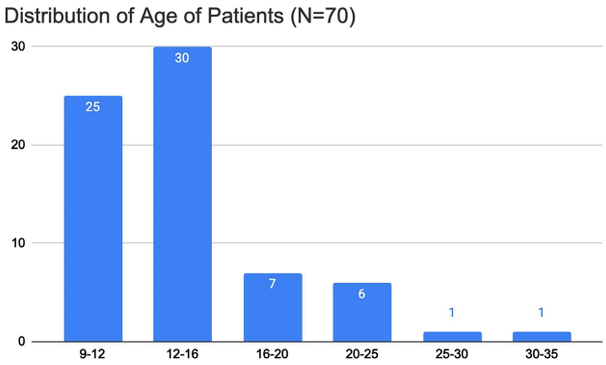


**Figure 1:** Distribution of age of patients at JPCC requiring transition to adult care (N=70)

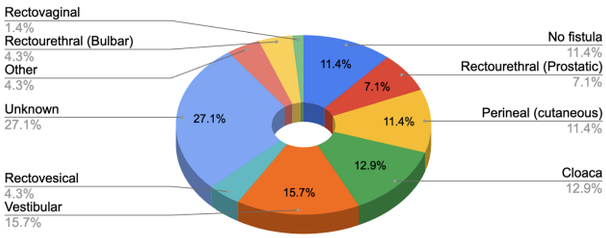


**Figure 2:** Distribution of anatomical types of anorectal malformation (N=70)

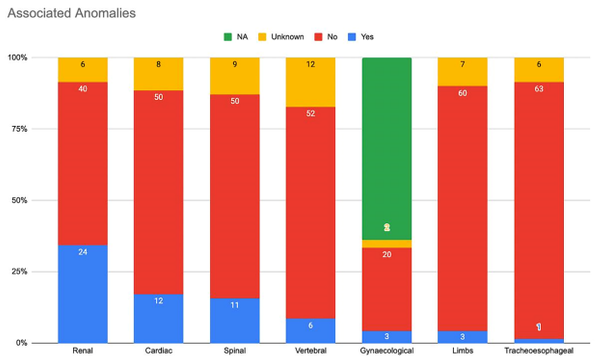


**Figure 3:** Distribution of associated anomalies (N=70)

bowel control. In terms of soiling, 6 (31.6%) never soiled themselves, 10 (52.6%) occasionally soiled themselves, and 3 (15.8%) soiled themselves constantly. For constipation, seven patients (36.8%) were not constipated, 4 (21%) managed their condition with diet alone, 3 (15.8%) required laxatives, and 5 (26.3%) needed washouts.

Of particular interest was the subgroup of patients who were 16 years and older, as these patients should, according to the hospital policy, be managed by adult services. A total of 15 patients were included and are summarised in Figure 5. Amongst these patients, the mean number of operations per patient was 7 (N=11, four missing data), 64% (7/11)

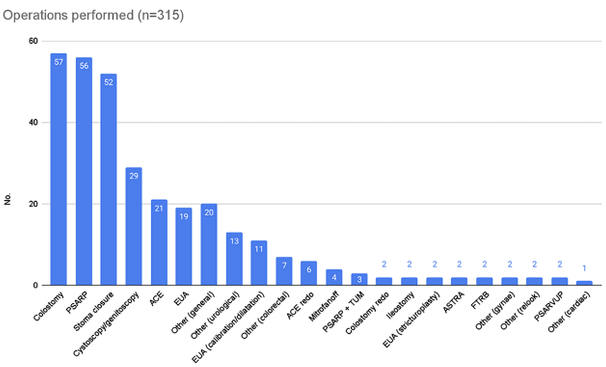


**Figure 4:** Operations performed (N=70)
*PSARP: Posterior Sagittal Anorectoplasty, ACE: Antegrade Continence Enema, EUA: Examination Under Anaesthesia, TUM: Total Urogenital Mobilisation, ASTRA: Anterior Sagittal Transrectal Approach, FTRB: Full Thickness Rectal Biopsy, PSARVUP: Posterior Sagittal Anorectal Vaginal Urethral Plasty

required an ACE procedure for bowel management, one had a permanent colostomy, one had a temporary ileostomy, and one was reliant on washouts. Of these patients, 40% (6/15) required ongoing specialised care by nephrology and urology. Other disciplines (besides adult colorectal surgery) that need continuing management include infectious diseases, gastroenterology, and genetics (Figure 5).

## DISCUSSION

This study presents a comprehensive overview of patients with anorectal malformations, particularly those requiring transition from paediatric to adult care, managed at a paediatric colorectal clinic of a large public hospital in South Africa. Given the chronic nature of ARMs, the management of these patients extends well beyond childhood, posing significant challenges during the transition phase. The results from this cohort of patients highlight the complexity of ARM management, the burden of associated anomalies, and the operational difficulties in transitioning patients to adult services. These findings are consistent with the growing body of literature emphasizing the challenges inherent in transitioning paediatric patients with chronic conditions to adult care.(6,13)

### Demographics and Types of ARMs

The distribution of anatomical malformations within this cohort differs from the incidence in the general population.(1,13) Notably, there was a higher proportion of cloacal malformations (12.9%) in comparison to 2.7% reported in a previous study in South Africa by Theron et al.(16) These malformations often require a higher number of surgical interventions. The fact that a significant portion of patients (27.1%) had an unknown anatomical type underscores the challenges in obtaining comprehensive clinical histories,

| Age | Sex | Type of Malformation | No. of operations | Bowel management | Bladder management | Additional follow-up required |
|---|---|---|---|---|---|---|
| 25 | F | Vestibular fistula | 4 | ACE | | |
| 21 | M | Unknown | 8 | ACE | | Nephrology<br>Urology |
| 32 | F | Vestibular fistula | 7 | ACE | | |
| 18 | M | Unknown | 6 | Washouts | | |
| 22 | M | Unknown | Unknown | Unknown | | Nephrology<br>Urology |
| 16 | M | Imperforate anus without fistula | 7 | ACE | | |
| 18 | M | Unknown | 13 | Permanent Stoma | | Gastroenterology |
| 16 | M | Bladder Neck fistula | 10 | Unknown | | |
| 24 | M | Unknown | 10 | ACE | Mitrofanoff | Nephrology<br>Urology |
| 17 | M | Bulbar fistula | 3 | ACE | Mitrofanoff | Nephrology<br>Urology |
| 20 | M | Unknown | Unknown | Unknown | | Neurology<br>Infectious disease |
| 23 | F | Cloaca | Unknown | Unknown | | Nephrology<br>Urology |
| 19 | M | Unknown | 7 | ACE | | |
| 20 | M | Unknown | Unknown | Unknown | | Nephrology<br>Urology<br>Genetics |
| 17 | M | Unknown | 4 | Temporary ileostomy | | |

**Figure 5:** Summary of patients aged 16 years and older who still utilise paediatric services (n=15)

particularly when surgeries are conducted at different institutions or without adequate documentation. This highlights a gap in record-keeping, which is a known issue in transitioning healthcare services.

## Associated Anomalies

The high prevalence of associated anomalies (66%) is a notable finding. Renal malformations (34%) were the most common, followed by cardiac and spinal anomalies, which reflect the multi-system nature of ARMs. This differs from the distribution of anomalies previously reported in the general population of ARMs in South Africa, where renal anomalies were only found in 11.7% of patients.(16) Of note, this is in line with findings from other LMIC countries, where associated anomalies are frequently encountered and contribute to the complexity of care.(15) The need for multidisciplinary care, including urology, nephrology, and cardiology, is critical in managing these patients. This multidisciplinary approach, as highlighted in our study, is also consistent with international guidelines, which emphasize the necessity of ongoing, integrated care for these individuals.(6)

## Surgical Interventions and Long-term Care

A significant number of patients in our study underwent multiple procedures, with a mean of 4.5 operations per patient. The fact that many patients required multiple interventions, such as stoma formation, PSARP, ACE, and urological procedures, is consistent with the findings of other studies that have documented the long-term need for surgical and non-surgical interventions in these patients.(7,10)

The high proportion (64%) of patients requiring ACE for bowel management further emphasizes the ongoing nature of care for these patients. As ARMs patients transition into adulthood, the continuation of ACE or stoma care becomes essential for maintaining quality of life, as voluntary bowel control is not always achieved in all patients. The variability in bowel management strategies employed (laxatives, washouts, ACE) also highlights the individualized nature of care and the importance of tailoring interventions to the specific needs of each patient.(13)

## Transitioning to Adult Care

The subgroup of patients aged 16 years and older presents the most pressing challenge in this study. According to the hospital policy, these patients should transition to adult services. However, despite being of adult age, many of them remain under the care of paediatric surgery due to the ongoing need for complex, multidisciplinary care and the lack of an adult service to which they can be referred. This phenomenon is consistent with findings from other studies, which show that the transition from paediatric to adult care for ARM patients is often delayed due to the specialised nature of their care and the lack of readiness of adult care facilities to manage such chronic conditions.(7)

The need for a structured transition process is therefore paramount to ensure continuity of care. As suggested by previous studies, such programs should involve both paediatric and adult healthcare providers, ensuring that adult services are prepared for the complex, long-term needs of these patients.(6) A successful transition can improve both health outcomes and the overall quality of life for these patients.

## CONCLUSION

The transition to adult care for patients with ARMs is a significant challenge, especially in resource-limited settings like South Africa. The findings from this study highlight the high prevalence of associated anomalies, the substantial surgical burden, and the ongoing need for multidisciplinary management. While patients aged 16 years and older technically meet the age criteria for adult care, many continue to require paediatric care due to the complexity of their condition and the fragmented nature of healthcare services. A formalised transition program, alongside coordinated multidisciplinary care, is essential to ensure optimal long-term outcomes for these patients.

## AUTHOR CONTRIBUTIONS

- **Leila Hartford:** Conceptualisation, Methodology, Data Cleaning, Formal Analysis, Writing: Original Draft Preparation, Review & Editing, Project Administration.
- **Giulia Brisighelli:** Conceptualisation, Methodology, Supervision, Writing: Review & Editing.

## REFERENCES


1. Levitt MA, Peña A. Anorectal malformations. Orphanet J Rare Dis. 2007; 2(1):33.
2. Peña A, Bischoff A. Surgical treatment of colorectal problems in children. Berlin: Springer; 2015.
3. Levitt MA, Peña A. Anorectal malformations. In: Mattei P, editor. Fundamentals of pediatric surgery. New York, NY: Springer; 2011: 499–512.
4. Moore SW. Associations of anorectal malformations and related syndromes. Pediatr Surg Int. 2013; 29:665–676.
5. Mittal A, Airon RK, Magu S, Rattan KN, Ratan SK. Associated anomalies with anorectal malformation (ARM). Indian J Pediatr. 2004; 71:509–514.
6. Giuliani S, Grano C, Aminoff D, et al. Transition of care in patients with anorectal malformations: consensus by the ARM-net consortium. J Pediatr Surg. 2017; 52(11):1866–1872.
7. Cairo SB, Gasior A, Rollins MD, Rothstein DH. Challenges in transition of care for patients with anorectal malformations: a systematic review and recommendations for comprehensive care. Dis Colon Rectum. 2018; 61(3):390–399.
8. Chen JC, Gasior AC. After anoplasty for anorectal malformations: issues continue in adolescence and adulthood. In chief of *Seminars in colon and rectal surgery* is Matthew Mutch. Amsterdam: Elsevier; 2023: 100989.
9. Violani C, Grano C, Fernandes M, et al. The transition of care for patients with anorectal malformations and Hirschsprung disease: a European survey. Eur J Paediatr Surg. 2023; 33(3):191–197.
10. Cairo SB, Chiu PP, Dasgupta R, et al. Transitions in care from pediatric to adult general surgery: evaluating an unmet need for patients with anorectal malformation and Hirschsprung disease. J Pediatr Surg. 2018; 53(8):1566–1572.
11. Brisighelli G, Etwire V, Lawal T, Arnold M, Westgarth-Taylor C. Treating pediatric colorectal patients in low- and middle-income settings: creative adaptation to the resources available. In chief of *Seminars in Pediatric Surgery* is Daniel J Ostlie. Amsterdam: Elsevier; 2020: 150989.
12. Springford LR, Connor MJ, Jones K, Kapetanakis VV, Giuliani S. Prevalence of active long-term problems in patients with anorectal malformations: a systematic review. Dis Colon Rectum. 2016; 59(6):570–580.
13. Bokova E, Elhalaby I, Svetanoff WJ, et al. Global strategies for postoperative care and bowel management in patients with anorectal malformations: varied practices and barriers. J Pediatr Surg. 2024; 59(12):161697.
14. Chu PY, Maslow GR, von Isenburg M, Chung RJ. Systematic review of the impact of transition interventions for adolescents with chronic illness on transfer from pediatric to adult healthcare. J Pediatr Nurs. 2015; 30(5):e19–e27.
15. vd Merwe E, Cox S, Numanoglu A. Anorectal malformations, associated congenital anomalies and their investigation in a South African setting. Pediatr Surg Int. 2017; 33:875–882.
16. Theron AP, Brisighelli G, Theron AE, Leva E, Numanoglu A. Comparison in the incidence of anorectal malformations between a first- and third-world referral center. Pediatr Surg Int. 2015; 31(8):759–764.

S4

# Daglif

DAPAGLIFLOZIN

5mg
10mg

## Navigate Type 2 Diabetes
## Improve Quality of life

## Why DAGLIF?

- **DAGLIF** is indicated for patients with Type 2 diabetes to improve glycaemic control as mono and add-on combination therapy
- Easy dosing with or without meals
- 5mg **DAGLIF** for patients at risk for volume depletion due to co-existing conditions or concomitant medications
- 10mg **DAGLIF** is the recommended dose

**MOST COST-EFFECTIVE**






S4 **DAGLIF 5 film-coated tablets.** Each film-coated tablet contains 5 mg dapagliflozin. Reg No. A55/21.2/0049
S4 **DAGLIF 10 film-coated tablets.** Each film-coated tablet contains 10 mg dapagliflozin. Reg No. A55/21.2/0050

Zydus Healthcare SA (Pty) Ltd. Block B, Southdowns Office Park, 22 Karee Street, Centurion, 0157. Tel: +27 (0)12 748 6400.
For full prescribing information please refer to the professional information leaflet as approved by SAHPRA (South African Health Products Regulatory Authority)

zydus
Dedicated To Life