Arthroscopic and radiographic findings at the time of Latarjet screw removal

Rimon T du Plessis,[1]* Jean-Pierre du Plessis,[2] Ntambue Kauta,[3] Wybrand de Kock,[1] Roopam Dey,[1] Stephen Roche[1]

[1] Department of Orthopaedic Surgery, Groote Schuur Hospital, University of Cape Town, Cape Town, South Africa
[2] Department of Orthopaedic Surgery, New Somerset Hospital, Cape Town, South Africa
[3] Department of Orthopaedic Surgery, Mitchells Plain Hospital, Cape Town, South Africa

**Corresponding author: rimonduplessis@gmail.com*

Citation: du Plessis RT, du Plessis J-P, Kauta N, de Kock W, Dey R, Roche S. Arthroscopic and radiographic findings at the time of Latarjet screw removal. SA Orthop J. 2026;25(3):136-141. http://dx.doi.org/10.17159/2309-8309/2026/v25n3a5

Editor: Dr Cameron Anley, Stellenbosch University, Cape Town, South Africa

Received: July 2025

Accepted: November 2025

Published: August 2026

Copyright: © 2026 du Plessis RT. This is an open-access article distributed under the terms of the Creative Commons Attribution Licence, which permits unrestricted use, distribution and reproduction in any medium, provided the original author and source are credited.

Funding: No funding was received for this study.

Conflict of interest: The authors declare they have no conflicts of interest that are directly or indirectly related to the research.

Abstract

Background

The Latarjet procedure is a well-described method to stabilise anterior shoulder instability. There are concerns of high complication rates, one of these being a painful shoulder without instability due to screw irritation. The arthroscopic changes in the shoulder at screw removal compared to those at index Latarjet have not been described in the literature.

Methods

We conducted a retrospective review of arthroscopic videos between 2015 and 2022 of 17 patients at the time of their Latarjet screw removal, and, where available (n = 13), compared them to arthroscopic findings at the time of index Latarjet. The operative notes were reviewed. Postoperative instability was an exclusion criterion. X-rays prior to screw removal were assessed independently by two observers blinded to patient details for resorption of the graft. Arthroscopic assessment of the anatomy and pathological changes were made by two shoulder surgeons via mutual consensus. An intraclass correlation coefficient (ICC) was analysed as a measure of the interobserver reliability of the radiographs.

Results

Our cohort had a mean age of 21.5 ± 7.7 years, and a mean period of 16.2 ± 13.1 months between Latarjet and screw removal. At screw removal, all patients had an inflamed subscapularis muscle, and 15 had intrasubstance fraying at the musculotendinous junction. Abnormal humeral (n = 11) and glenoid cartilage (n = 9) was noted. Ten had an abnormal posterior labrum. Thirteen patients had comparisons made to their pre-Latarjet arthroscopes which showed worsening in the condition of the subscapularis muscle (n = 10), glenoid (n = 5), humeral cartilage (n = 4), and posterior labrum (n = 6). Graft resorption was documented in all patients after reviewing X-rays and operative notes. Excellent inter-rater reliability was observed with an ICC value of 0.82.

Conclusion

This study shows a high rate of subscapularis change in patients undergoing screw removal for pain following a previous Latarjet. Progression of damage and new pathological changes were also noted in the labrum and cartilage on both sides of the joint. This study highlights possible shoulder pathological changes that may be the origin of the pain in the patient with a stable shoulder following a Latarjet procedure.

Level of evidence: 4

Keywords: Latarjet, complications, pain, screw removal

Introduction

Recurrent instability after a shoulder dislocation is a common problem and often requires surgical intervention. Recurrent instability may be associated with glenoid or humeral bone loss, and when present, soft tissue repair alone is associated with high failure rates.[1-3] The Latarjet operation was first described by the French surgeon Michel Latarjet in 1954, and is the procedure of choice when substantial bone loss is present. It has also been suggested for patients with hyperlaxity and contact sportspeople.[1,2,4,5] Scoring systems such as the Instability Severity Index Score, have been proposed to guide the surgeon in deciding between the Latarjet procedure or an arthroscopic soft tissue repair.[6]

Concerns have been raised regarding the high complication rate in the Latarjet procedure as highlighted by Griesser et al. in their systematic review. The complication rate was reported to be 30%, with 7.5% of patients requiring reoperation, and 35% of reoperations being for symptomatic hardware.[7] Patients may have ongoing shoulder pain despite having a stable shoulder.[8,9]

Godenèche et al. reported that 21 of the 461 (4.6%) Latarjet procedures performed by a single surgeon at their institute experienced anterior shoulder pain without instability. Pain scores

improved in all these patients with removal of the screws, with complete resolution of pain in 67% of patients.[9] Similar reports of resolution of pain with screw removal have been published but are limited to a few case reports.[10-13] Understanding the potential causes of shoulder pain after a Latarjet procedure and the reported patient response to screw removal will help to guide the management of these challenging patients when other causes such as instability and graft non-union have been excluded.

To our knowledge, there is only one study briefly reporting on the arthroscopic findings at the time of screw removal, and no study that compares arthroscopic videos at the time of screw removal to those at the time of index Latarjet.[9]

This study aimed to assess the arthroscopic findings of the glenohumeral joint at the time of Latarjet screw removal in patients with pain after the Latarjet procedure but with no instability.

Methods

This study is a retrospective case series consisting of patients with shoulder pain but with no instability after their index Latarjet procedure, and who had subsequent screw removal for the pain. We reviewed operative notes, arthroscopic videos and X-rays of patients who underwent surgery between January 2015 and September 2022. This timeline was chosen as no arthroscopic video recordings were available prior to 2015. Patients who had screw removal were identified from the databases of two fellowship-trained shoulder surgeons in Cape Town, and only those with an arthroscopic evaluation at the same time were included. We routinely perform an arthroscopic evaluation at screw removal to ensure no other pathologies are missed. Magnetic resonance imaging (MRI) evaluation in Latarjet patients is often suboptimal due to interference from screw artifact, and other possible causes of pain need to be excluded.[14] A total of 17 patients met the inclusion criteria. Thirteen of these also had arthroscopic video footage available from the index Latarjet. Our cohort had a mean age of 21.5 ± 7.7 years (range 15–40 years), and the mean period between index Latarjet and screw removal was 16.2 ± 13.1 months (range 4 months–7 years).

All Latarjet procedures were performed as open procedures using an anterior axillary incision and deltopectoral approach. A horizontal split of the subscapularis and a vertical capsulotomy were performed. Surgeon preference varied for capsular repair. The capsule was either sutured to the coracoacromial (CA) stump with Vicryl 1 sutures or repaired to the glenoid rim using bone anchors. The method of fixation of the coracoid graft also varied between the surgeons. These variations are demonstrated in *Table I*.

Screws were removed via an open procedure and not arthroscopically to maintain the integrity of the anterior capsule. This has been demonstrated to be an important factor in reducing postoperative instability.[15] Arthroscopic screw removal also potentially carries the risk of axillary and musculocutaneous nerve injury.[16]

Table I: Surgical technique at index Latarjet

Observation	n = 17
Screw type	
Fully threaded solid	2
Partial threaded solid	2
Cannulated and partially threaded	13
Screw adjunct	
Plate	3
Washers	1
Capsular repair to coracoacromial stump	2
Capsular repair with anchors to glenoid rim	12
No surgical record of capsular repair	3

Exclusion criteria were those patients who had recurrent instability, fractured or non-united coracoid grafts, broken screws, rotator cuff tears that required repair, and those who required further surgery other than screw removal. These exclusions were implemented to isolate the subset of patients with a painful but stable Latarjet procedure from those with pain and an unstable shoulder. Patients who had shoulder sepsis requiring screw removal were also excluded from this study. The study was granted ethics approval.

Arthroscopic evaluation

Arthroscopic videos were retrospectively reviewed in a single sitting by two shoulder surgeons blinded to patient details. The 15-point system of a diagnostic shoulder arthroscopy described by the Southern California Orthopaedic Institute (SCOI) was used to assess the shoulder anatomy.[17] The observers were given categories to classify each anatomical landmark (*Table II*). The Outerbridge grading system for cartilage change and Ellman classification for partial rotator cuff tears were used.[18-20]

Table II: Arthroscopic findings at the time of screw removal

Observation	n = 17
Biceps tendon	
Normal	16
Inflamed	1
Anterior labrum	
Intact	2
Frayed	3
Torn (detached from glenoid)	12
Posterior labrum	
Intact	7
Frayed (*Figure 1*)	8
Torn	2
Glenoid cartilage	
Normal	8
Fibrillation/fraying (Outerbridge 1–2)	5
Full thickness defect (Outerbridge 4)	4
Supraspinatus	
Normal	17
Infraspinatus and teres minor	
Normal	17
Inferior humeral head osteophyte < 3 mm	3
Humerus cartilage damage	
Normal	6
Fibrillation/fraying (Outerbridge 1–2)	5
Partial thickness defect (Outerbridge 3)	2
Full thickness defect (Outerbridge 4)	4
Subscapularis from intra-articular aspect	
Inflamed	17
Partial articular sided tear < 25%	1
Subscapularis from open approach	
Fraying at MT junction	15
Capsule synovitis	15
GLAD	1
Screw head visible in the joint	
Superior screw visible	1
Both screws visible	1
Capsulolabral repair	
Intact	14
Loose anchor sutures	1
Anchor pullout	2

MT: musculotendinous junction; GLAD: glenolabral articular disruption

Table III: X-ray findings prior to screw removal

Observation	n = 17
Graft resorption (measured from base of screw head)	
< 2 mm	8
≥ 2 mm (all around superior screws)	3
No lysis	3
Interobserver agreement not reached	3
Resorption around both screws	4
Resorption around superior screw only	4
Resorption around inferior screw only	3
Surgical record of graft resorption at screw removal	17
Osteoarthritis on AP X-ray – Samilson–Prieto grade 1	1

Table IV: Progression of change from the original arthroscopic findings to the follow-up arthroscopy at the time of screw removal

Comparison	n = 13
Normal to inflamed biceps tendon	1
Deterioration of posterior labrum	
Normal to torn	1
Normal to frayed	2
Worsening of fraying	3
Deterioration of glenoid cartilage	
Outerbridge grade 2 to full thickness defect (grade 4)	2
Normal to grade 2	3
Development of inferior humeral head osteophyte	1
Deterioration of humeral head cartilage	
Normal to full thickness defect (Outerbridge 4)	1
Grade 2 to full thickness	1
Normal to grade 2	1
Normal to grade 3	1
Subscapularis change	
Normal to inflamed	10
Normal to synovitic capsule	7

The observers came to a joint consensus about the anatomical changes that had occurred in the shoulder joint. All videos were assessed for adequacy in demonstrating the entire shoulder anatomy. All videos were deemed adequate. At the time of screw removal, arthroscopies were additionally assessed for the status of the capsular repair and whether the screw heads were visible without debridement of the anterior capsule.

The state of the subscapularis was documented not only arthroscopically but also during the open part of the procedure. The subscapularis was split through the previous incision and any changes were documented. The screws were exposed and the changes in the subscapularis were noted in relation to the screw heads.

Radiographic evaluation

Anteroposterior (AP), scapular Y, and axillary view X-rays of the shoulder were routinely obtained before Latarjet screw removal. Graft resorption was classified as < 2 mm or ≥ 2 mm from the base of the screw head, and osteoarthritis was assessed using the Samilson–Prieto classification.[21,22] The X-rays were assessed for graft position in the coronal and axial plane using parameters described by Hovelius et al. and Bouju et al.[23,24] These X-rays were reviewed separately by two orthopaedic registrars who were given categories to classify the findings accordingly (*Table III*). They were blinded to patient details and there was no correspondence between them.

Statistical analysis

The mean and standard deviation for age and time between index Latarjet and screw removal were calculated. In 13 patients who had arthroscopic videos available from the index Latarjet procedure, findings were compared to the follow-up arthroscopy at the time of screw removal (*Table IV).* The categorical data were described by the frequency of observations made.

The interobserver reliability for radiographic evaluation was assessed using an intraclass correlation coefficient (ICC). It was considered excellent with values above 0.7, good with values between 0.4–0.7, and poor with values less than 0.4.

Results

Arthroscopic findings at the time of Latarjet screw removal

Table II summarises the arthroscopic findings at the time of Latarjet screw removal. Ten patients had a pathological posterior labrum (*Figure 1*). Five had both humeral and glenoid cartilage changes.

There was one glenolabral articular disruption (GLAD) lesion noted with no video at index Latarjet to compare to. No patients had a humeral avulsion of the glenohumeral ligament (HAGL).

All patients had an inflamed subscapularis when viewed from inside the joint and one had a partial articular-sided tear less than 25% thickness. Fifteen had intrasubstance fraying at the musculotendinous (MT) junction of the subscapularis during the open approach to screw removal (*Figure 2*). There were no complete tears. Three patients had a failure of capsulolabral repair when suture anchors were used (*Figure 3*). Two of these patients had one anchor used for repair. None of these three were clinically unstable.

Radiographic findings prior to screw removal

Table III summarises the X-ray findings at the time of screw removal. There were no broken or bent screws, and no coracoid grafts were assessed as being placed lateral to the glenoid articular surface. All coracoid grafts were adequately positioned. Eleven had graft resorption, which was agreed upon by both observers. The three patients with graft resorption ≥ 2 mm were around the superior screws (*Figure 4*). ICC was excellent at 0.82.

Comparing arthroscopic findings at index Latarjet to those at the time of screw removal

Table IV summarises the comparisons that were made for the 13 patients who had arthroscopic videos available from the index Latarjet and at screw removal. Six had deterioration of the



Figure 1. Frayed posterior labrum of the right shoulder viewed from the posterior portal in a 22-year-old male four months after his index Latarjet

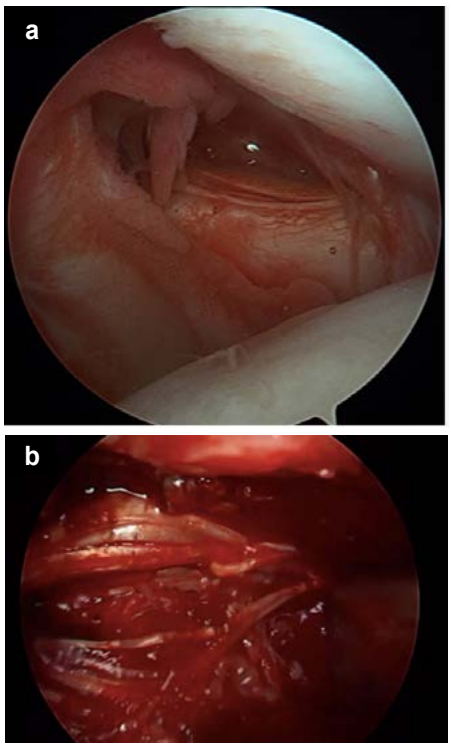

Figure 2. a) Inflamed subscapularis noted in the same arthroscopic video as *Figure 1* from the posterior portal; b) intrasubstance fraying at the MT junction of subscapularis in the same patient's right shoulder during the open approach to remove screws



Figure 3. View of the right shoulder from the posterior portal; anchor pullout noted in the same arthroscopic video as shown in *Figures 1* and *2*. Only one anchor was used for the capsulolabral repair in this case.

posterior labrum. Anterior labral comparisons were not made as all had defects at the time of Latarjet.

Four had worsening of their humeral cartilage with two progressing to full-thickness defects (Outerbridge grade 4), which were both less than 10% of the humeral head (*Figure 5*). There were five that had worsening of their glenoid cartilage with two patients progressing to a full thickness defect, which was less than 10% of the glenoid. There were no changes in the supraspinatus, infraspinatus and teres minor.

The one patient that had Samilson–Prieto grade 1 changes on X-ray had progression to a full-thickness cartilage defect at the humeral and glenoid aspect at screw removal.

Ten patients had progression to an inflamed subscapularis. The other three had inflammation documented at both index Latarjet and at the time of screw removal. One patient had a partial articular-sided tear less than 25% thickness of the subscapularis documented at the index Latarjet and again, without progression at screw removal.

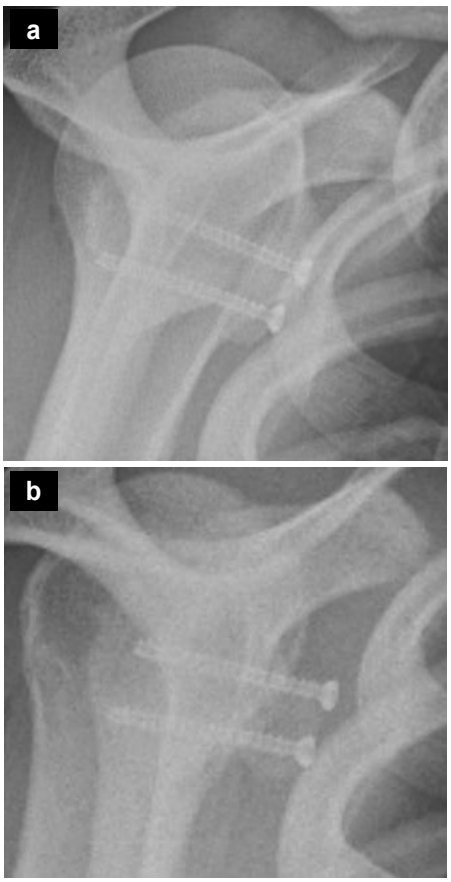

Figure 4. a) Scapular Y view of a right shoulder day 1 post-index Latarjet and b) six months later showing graft resorption around the superior screw of > 2 mm in a 19-year-old male



Figure 5. New full-thickness cartilage loss of the right humeral head (Outerbridge 4) viewed from the posterior portal seven months after index Latarjet in a 17-year-old male

Discussion

Our review of the arthroscopic findings at the time of Latarjet screw removal demonstrates a high incidence of pathology in the shoulder, which conflicts markedly with the paper by Godenèche et al. who report a single partial tear of the supraspinatus and no glenoid or humeral head cartilage lesions in their arthroscopic evaluation. They do not report on the extra-articular condition of the subscapularis during their open approach to remove the screws. We cannot explain the significant disparity except perhaps they did not do their arthroscopic evaluation as rigorously and detailed as described by SCOI 15-point evaluation that we used. They also did not compare their arthroscopic findings to those at the time of the index Latarjet. In contrast, we had an opportunity to compare

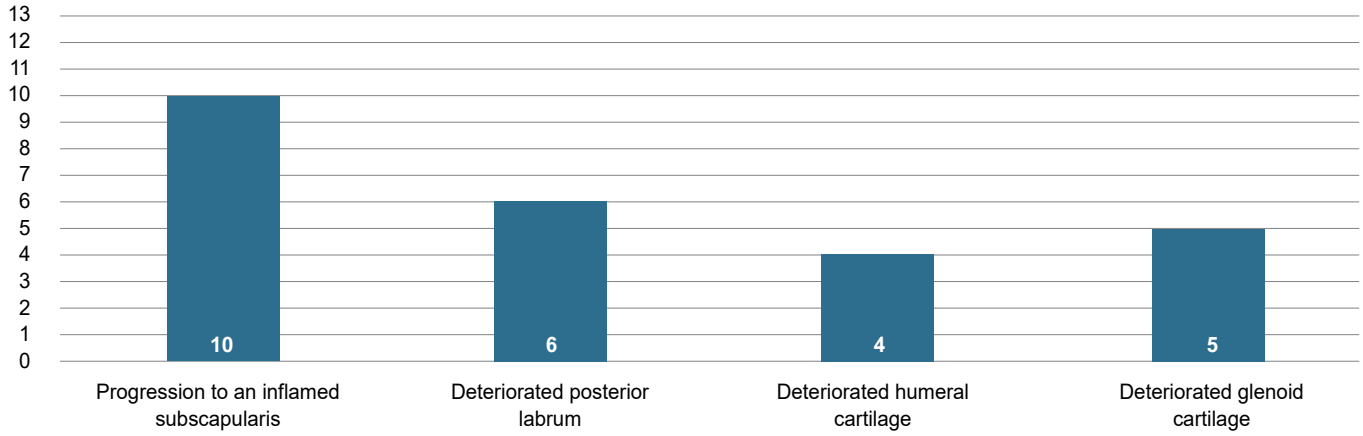

Figure 6. Comparison of arthroscopic findings at the time of index Latarjet to those at the time of screw removal (n = 13)

the findings of 13 out of 17 patients who had an arthroscopy at the time of the index Latarjet and could therefore document new or progression of findings.[9] We observed significant new pathology and deterioration of existing pathologies when compared with the arthroscopic findings at the time of Latarjet. The subscapularis muscle, glenoid and humeral cartilage, and the posterior labrum showed deterioration (*Figure 6*).

Godenèche et al. removed screws in 21 patients with painful, stable shoulders after a Latarjet procedure with the resolution of pain in 67% of patients. They suggest that, in this group of patients, the screws were causing the pain.[9] Similar reports of resolution of pain with screw removal have been published.[10-13] In our study, we did not include a clinical follow-up of the patients to determine their response to screw removal but the uniform inflammation of the subscapularis and high rate of intrasubstance fraying of the subscapularis supports Godenèche's theory that a possible pain generator in these stable shoulders is soft tissue impingement against the screws.[9] This hypothesis is shared by other authors.[11,16]

Our X-ray findings differ from those described by Godenèche et al. They report that two out of 21 had evidence of graft resorption on X-ray and computed tomography (CT) scans.[9] We observed higher rates as demonstrated in *Table III* in keeping with the literature by Zhu et al. who showed graft resorption in 90% of their patients.[25] We observed higher grade resorption of ≥ 2 mm in the superior screws (*Figure 4*), which is in keeping with the study by Di Giacomo et al. who attribute this to various biological and biomechanical factors.[26] Three of our patients did not have graft resorption observed and three where the observers could not agree. X-ray assessment of graft resorption has been described as less accurate compared to CT scans and may under-represent the degree of graft resorption.[25-27] When reviewing the operative notes of our cohort, it was noted that there was graft resorption in all cases despite not being able to document this on X-rays.

The high rate of subscapularis inflammation and intrasubstance fraying we observed would suggest that, as the screw heads become more prominent with graft resorption, they cause mechanical damage to the subscapularis tendon and cause pain. The clinical effects of coracoid graft resorption and hardware prominence are controversial in the literature. Some studies have shown that major resorption of the coracoid graft was not associated with shoulder pain or instability.[24,26] Surprisingly the pathology we demonstrated was not limited to the subscapularis. The high rate of pathology in the glenoid and humeral cartilage, and posterior labrum could also be pain generators and may explain why not all patients in the study by Godenèche had resolution of their pain after screw removal.[9] We did not include a clinical follow-up in our study and cannot comment on the resolution of pain after screw removal in our cohort.

There is minimal literature regarding the state of the glenoid labrum in the painful but stable Latarjet procedure. The high rate of labral pathology we observed is concerning and should be further investigated. The labral changes we observed do not seem to be associated with instability. All patients were clinically stable and reported no subjective symptoms of instability; this was one of our inclusion criteria. Possibly, the changes are early signs of glenohumeral joint degeneration.

A significant number of patients showed worsening in the condition of their humeral and glenoid cartilage despite all grafts being assessed as being stable and adequately positioned. Studies have suggested that prominent screws may result in articular cartilage damage.[10,11] Other potential causes of damage to the glenohumeral cartilage are a prominent, or laterally positioned graft.[11,24] None of the coracoid grafts in our patients were seen to be laterally positioned on X-ray or at arthroscopy. Most of our patients had capsulolabral repair using anchors to the glenoid rim. Capsular overtightening after anchor fixation of the capsulolabral complex has been associated with arthropathy and may be another cause of the pathological changes we observed in the cartilage and posterior labrum.[28] Two patients had capsule repair to the coracoacromial ligament stump but still showed degenerative changes. Three patients had failure of their anchor fixation, with one of these patients having new pathology of the humeral (Outerbridge 2) and glenoid cartilage (Outerbridge 3). None of these three were deemed unstable.

The high rate of arthroscopic findings of joint degeneration did not correlate with X-ray review. One patient had a Samilson–Prieto grade 1 inferior humeral head osteophyte observed on X-ray indicative of glenohumeral arthritis. A possible reason for this low rate could be the relatively short period (mean 16.2 ± 13.1 months) between index Latarjet and screw removal, with radiographic evidence of arthritis occurring later than arthroscopic findings of degenerative cartilage. Hurley et al. reported arthritic changes on X-ray in 38% of patients in their systematic review but this was at a ten-year follow-up.[8]

There are several limitations of this study such as the retrospective nature, small cohort size, and varying length of time between screw removal. Four of the patients did not have arthroscopies at index Latarjet; therefore, the progression of injury could not be documented in these four. X-ray assessment of graft resorption has been described as less accurate compared to CT scans.[25-27] In our cohort, only two patients had CT scans available prior to screw removal. Two had MRIs but were suboptimal for interpretation due to interference from screw artifact. The lack of clinical follow-up clearly limits the correlation of the pathologies to the cause of the pain.

Conclusion

This study shows a high rate of subscapularis change in patients undergoing screw removal for pain following a previous Latarjet. Progression of damage and new pathological changes were also noted in the labrum and cartilage on both sides of the joint. This study highlights possible shoulder pathological changes that may be the origin of the pain in the patient with a stable shoulder following a Latarjet procedure.

Ethics statement

The authors declare that this submission is in accordance with the principles laid down by the Responsible Research Publication Position Statements as developed at the 2nd World Conference on Research Integrity in Singapore, 2010.
Prior to the commencement of the study ethical approval was obtained from the following ethical review board: University of Cape Town Human Research Ethics Committee (HREC ref: 436/2022.) All procedures were in accordance with the ethical standards of the responsible committee on human experimentation (institutional and national) and with the Helsinki Declaration of 1975, as revised in 2008. For this study formal consent was not required.

Declaration

The authors declare authorship of this article and that they have followed sound scientific research practice. This research is original and does not transgress plagiarism policies.

Author contributions

RTdP: contributed to the study conceptualisation, design, data collection and manuscript preparation
SR: contributed to the study conceptualisation, design, data collection and manuscript preparation
NK: contributed to the study design and manuscript preparation
J-PdP: contributed to the study conceptualisation, design, data collection and manuscript preparation.
WdK: contributed to the study design and data collection
RD: contributed to the study design and data analysis

ORCID

du Plessis RT https://orcid.org/0009-0003-3872-7846
Roche S https://orcid.org/0000-0002-3878-5873
Kauta N https://orcid.org/0000-0002-7099-2506
du Plessis J-P https://orcid.org/0000-0001-6469-7765
de Kock W https://orcid.org/0009-0001-3878-423X
Dey R https://orcid.org/0000-0002-3616-1995

References

1. Boileau P, Villalba M, Héry JY, et al. Risk factors for recurrence of shoulder instability after arthroscopic Bankart repair. J Bone Joint Surg Am. Aug 2006;88(8):1755-63. https://doi.org/10.2106/jbjs.E.00817
2. Burkhart SS, de Beer JF. Traumatic glenohumeral bone defects and their relationship to failure of arthroscopic Bankart repairs: significance of the inverted-pear glenoid and the humeral engaging Hill-Sachs lesion. Arthroscopy. Oct 2000;16(7):677-94. https://doi.org/10.1053/jars.2000.17715
3. Itoi E, Lee SB, Berglund LJ, et al. The effect of a glenoid defect on anteroinferior stability of the shoulder after Bankart repair: a cadaveric study. J Bone Joint Surg Am. Jan 2000;82(1):35-46. https://doi.org/10.2106/00004623-200001000-00005
4. Zhang M, Liu J, Jia Y, et al. Risk factors for recurrence after Bankart repair: a systematic review and meta-analysis. J Orthop Surg Res. Feb 20 2022;17(1):113. https://doi.org/10.1186/s13018-022-03011-w
5. Latarjet M. [Technic of coracoid preglenoid arthroereisis in the treatment of recurrent dislocation of the shoulder]. Lyon Chir. Jul 1958;54(4):604-607.
6. Balg F, Boileau P. The instability severity index score. A simple pre-operative score to select patients for arthroscopic or open shoulder stabilisation. J Bone Joint Surg Br. Nov 2007;89(11):1470-77. https://doi.org/10.1302/0301-620x.89b11.18962
7. Griesser MJ, Harris JD, McCoy BW, et al. Complications and re-operations after Bristow-Latarjet shoulder stabilization: a systematic review. J Shoulder Elbow Surg. Feb 2013;22(2):286-92. https://doi.org/10.1016/j.jse.2012.09.009
8. Hurley ET, Jamal MS, Ali ZS, et al. Long-term outcomes of the Latarjet procedure for anterior shoulder instability: a systematic review of studies at 10-year follow-up. J Shoulder Elbow Surg. Feb 2019;28(2):e33-e39. https://doi.org/10.1016/j.jse.2018.08.028
9. Godenèche A, Merlini L, Roulet S, et al. Screw removal can resolve unexplained anterior pain without recurrence of shoulder instability after open Latarjet procedures. Am J Sports Med. May 2020;48(6):1450-55. https://doi.org/10.1177/0363546520916171
10. Young DC, Rockwood CA, Jr. Complications of a failed Bristow procedure and their management. J Bone Joint Surg Am. Aug 1991;73(7):969-81.
11. Gupta A, Delaney R, Petkin K, Lafosse L. Complications of the Latarjet procedure. Curr Rev Musculoskelet Med. Mar 2015;8(1):59-66. https://doi.org/10.1007/s12178-015-9258-y
12. du Plessis JP, Lambrechts A, McGuire D, Roche S, Vrettos BC. Early and medium-term complications of the modified Latarjet procedure. SA Orthop J. 2014;13(3):50-56.
13. Bach BR, Jr. Arthroscopic removal of painful Bristow hardware. Arthroscopy. 1990;6(4):324-26. https://doi.org/10.1016/0749-8063(90)90065-l
14. Beltran LS, Duarte A, Bencardino JT. Postoperative imaging in anterior glenohumeral instability. AJR Am J Roentgenol. Sep 2018;211(3):528-37. https://doi.org/10.2214/ajr.17.19304
15. Hovelius L, Sandström B, Olofsson A, et al. The effect of capsular repair, bone block healing, and position on the results of the Bristow-Latarjet procedure (study III): long-term follow-up in 319 shoulders. J Shoulder Elbow Surg. May 2012;21(5):647-60. https://doi.org/10.1016/j.jse.2011.03.020
16. Lafosse T, Amsallem L, Delgrande D, et al. Arthroscopic screw removal after arthroscopic Latarjet procedure. Arthrosc Tech. Jun 2017;6(3):e559-e566. https://doi.org/10.1016/j.eats.2016.12.002
17. Wallace AL. Shoulder Arthroscopy, Third edition. Shoulder Elbow. 2014 Dec 21;7(1):72.
18. Outerbridge RE. The etiology of chondromalacia patellae. J Bone Joint Surg Br. Nov 1961;43-b:752-57. https://doi.org/10.1302/0301-620x.43b4.752
19. Noyes FR, Stabler CL. A system for grading articular cartilage lesions at arthroscopy. Am J Sports Med. Jul-Aug 1989;17(4):505-13. https://doi.org/10.1177/036354658901700410
20. Ellman H. Diagnosis and treatment of incomplete rotator cuff tears. Clin Orthop Relat Res. May 1990;(254):64-74.
21. Kerr R, Resnick D, Pineda C, Haghighi P. Osteoarthritis of the glenohumeral joint: a radiologic-pathologic study. AJR Am J Roentgenol. May 1985;144(5):967-72. https://doi.org/10.2214/ajr.144.5.967
22. Samilson RL, Prieto V. Dislocation arthropathy of the shoulder. J Bone Joint Surg Am. Apr 1983;65(4):456-60.
23. Hovelius L, Körner L, Lundberg B, et al. The coracoid transfer for recurrent dislocation of the shoulder. Technical aspects of the Bristow-Latarjet procedure. J Bone Joint Surg Am. Sep 1983;65(7):926-34.
24. Bouju Y, Gadéa F, Stanovici J, et al. Shoulder stabilization by modified Latarjet-Patte procedure: results at a minimum 10 years' follow-up, and role in the prevention of osteoarthritis. Orthop Traumatol Surg Res. Jun 2014;100(4 Suppl):S213-8. https://doi.org/10.1016/j.otsr.2014.03.010
25. Zhu YM, Jiang CY, Lu Y, et al. Coracoid bone graft resorption after Latarjet procedure is underestimated: a new classification system and a clinical review with computed tomography evaluation. J Shoulder Elbow Surg. Nov 2015;24(11):1782-88. https://doi.org/10.1016/j.jse.2015.05.039
26. Di Giacomo G, Costantini A, de Gasperis N, et al. Coracoid graft osteolysis after the Latarjet procedure for anteroinferior shoulder instability: a computed tomography scan study of twenty-six patients. J Shoulder Elbow Surg. Sep 2011;20(6):989-95. https://doi.org/10.1016/j.jse.2010.11.016
27. Boileau P, Gendre P, Baba M, et al. A guided surgical approach and novel fixation method for arthroscopic Latarjet. J Shoulder Elbow Surg. Jan 2016;25(1):78-89. https://doi.org/10.1016/j.jse.2015.06.001
28. Waterman BR, Kilcoyne KG, Parada SA, Eichinger JK. Prevention and management of post-instability glenohumeral arthropathy. World J Orthop. Mar 18 2017;8(3):229-41. https://doi.org/10.5312/wjo.v8.i3.229