CASE REPORT

Pilomatrixoma of bone

Ncana W Ncana,[1] Thomas Hilton,[1] Henrik CF Bauer,[2] Ali MO Nasar,[1] Jennifer Hauptfleisch[3]

[1] Department of Orthopaedic Surgery, Groote Schuur Hospital, University of Cape Town, Cape Town, South Africa
[2] Department of Molecular Medicine and Surgery, Karolinska Institute, Stockholm, Sweden; Visiting Professor in the Faculty of Medicine and Health Sciences, Department of Surgery, Division of Orthopaedics, University of Cape Town, Cape Town, South Africa
[3] Morton and Partners Radiologists, Cape Town, South Africa

Corresponding author: wazibancana@gmail.com

Citation: Ncana NW, Hilton T, Bauer HCF, Nasar AMO, Hauptfleisch J. Pilomatrixoma of bone. SA Orthop J. 2026;25(3):152-154. http://dx.doi.org/10.17159/2309-8309/2026/v25n3a8

Editor: Prof. Theo le Roux, University of Pretoria, Pretoria, South Africa

Received: September 2025

Accepted: November 2025

Published: August 2026

Copyright: © 2026 Ncana NW. This is an open-access article distributed under the terms of the Creative Commons Attribution Licence, which permits unrestricted use, distribution and reproduction in any medium, provided the original author and source are credited.

Funding: No funding was received for this study.

Conflict of interest: The authors declare they have no conflicts of interest that are directly or indirectly related to the research.

Abstract

Pilomatrixoma is a benign skin tumour, arising from hair follicle cells. While typically localised to the skin, aggressive cases with deep tissue involvement, including bone, may occur. Pilomatrixoma carcinoma is a known malignant variant, but direct bone involvement in this malignant variant has not been described in the literature. This case report presents a unique case of a large pilomatrixoma carcinoma invading the proximal tibia.

A 54-year-old male known with benign pilomatrixomas and a background of hypertension, non-insulin-dependent diabetes and morbid obesity (BMI 51 kg/m^2) presented in 2024 to a plastic surgeon with what was thought to be a benign pilomatrixoma over his anterior leg just below the knee. A resection of the lesion was attempted; however, it was discovered intraoperatively that the lesion involved the proximal tibia. The procedure was abandoned, a vacuum-assisted closure (VAC) dressing placed, and the patient referred to the local oncology unit where further work-up of the patient was carried out. Plain radiography showed a large lytic lesion of the anterolateral aspect of proximal tibia with a narrow, non-sclerotic zone of transition of the margin of the lesion in the bone. Magnetic resonance imaging (MRI) showed an expansile, infiltrative proximal tibial lesion, with perilesional marrow oedema and extension anteriorly into the soft tissue. Joint-sparing surgery was not considered feasible, and a wide en bloc resection of the proximal tibia was performed. The knee joint and proximal tibia were reconstructed with a proximal tibia megaprosthesis, covered by a medial gastrocnemius flap and split skin graft.

Histopathological examination confirmed a pilomatrixoma carcinoma measuring 145 × 95 mm with a mix of atypical basaloid cells, ghost cells, and areas of new bone formation. No tumour necrosis was observed, but mitotic figures numbered up to 7 per 10 high-power field, indicating moderate proliferative activity. The patient recovered well from the surgery and went on to receive postoperative radiation therapy after discussion at a multi-disciplinary team (MDT) meeting. This is the only case of pilomatrixoma carcinoma reported with bone involvement. Resection of the tumour including the proximal tibia with reconstruction and postoperative radiation therapy has been successful in the short term.

Level of evidence: 4

Keywords: pilomatrixoma carcinoma, bone

Introduction

Pilomatrixoma, or calcifying epithelioma of Malherbe, is a common benign skin appendage tumour exhibiting hair matrix and a normal hair follicle inner sheath, as well as hair cortex differentiation.[1] It presents as a firm, non-tender subcutaneous mass adherent to the skin but not fixed to the underlying tissue.[2] Generally, the tumour ranges in size from 0.5 to 3 centimetres (cm), but may be as large as 5 cm.[3] Pilomatrixomas occur mostly in children and the most common location is the head and neck region, but can develop anywhere on the body where there are hair follicles.[4] Recurrences after excision are reported in some rare instances,[5] and distant metastases are extremely rare.[6]

A rare malignant variant of pilomatrixoma called 'pilomatrixoma carcinoma' or 'calcified epithelial carcinoma of Malherbe' was first reported by Lopansri and Mihm in 1980.[7] This is a locally aggressive tumour with a tendency to recur.[8] Distant metastases have been



Figure 1. Intraoperative anterior tibial wound after initial resection and prior to VAC dressing application

DOI 10.17159/2309-8309/2026/v25n3a8

reported, with pulmonary lesions being the most frequent manifestation.[9] Similar to pilomatrixoma, pilomatrixoma carcinoma typically presents as a non-tender, firm dermal swelling[8] and is found most commonly in the head and neck region.[10] Pilomatrixoma carcinoma commonly occurs in the fifth to the seventh decade, with a male to female ratio of 4:1.[10]

According to our review, invasion of bone by benign pilomatrixoma has only been described in two articles. Ishida et al.[11] reported a case of intraosseous pilomatrixoma associated with Gardner syndrome. A second case was described by Wickremaratchi & Collins who reported an aggressive pilomatrixoma invading the tibia.[3] We were not able to find any evidence of a pilomatrixoma carcinoma of bone.

Case report

The patient is a 54-year-old male with hypertension, non-insulin-dependent diabetes and morbid obesity (BMI 51 kg/m^2). The patient is known to have benign pilomatrixomas and has undergone previous resections. He presented with a large cutaneous lesion involving his right proximal leg anteriorly, just below the knee joint. His plastic surgeon performed the initial resection; intraoperatively it became apparent that there was intraosseous extension of the lesion, and the procedure was abandoned (*Figure 1*). A vacuum-assisted closure (VAC) dressing was placed, and the patient referred to a local orthopaedic oncology unit. On assessment, a large wound with superficial infection was found. Plain film radiography (*Figure 2*) showed a large lytic bone lesion with destruction of the anterolateral aspect of the proximal tibia. The lesion had a narrow, non-sclerotic zone of transition at the margin of the lesion. No pre-surgical magnetic resonance imaging (MRI) was performed, but a post-initial surgery MRI showed an expansile, infiltrative proximal tibial lesion measuring 7 × 7 × 11 cm with destruction of the anterolateral cortex, peri-lesional marrow oedema and anterior soft tissue extension (*Figure 3*). The patient was referred to a radiation oncologist and staged with a whole-body positron emission tomography (PET) CT scan which showed no evidence of metastatic disease. Joint-sparing surgery was not considered feasible, and a wide en bloc resection of the proximal tibia was performed. The knee joint and proximal tibia were reconstructed with a proximal tibia megaprosthesis (*Figure 4*), covered by a medial gastrocnemius flap and split skin graft.



Figure 2. Plain film X-rays showing the destruction of the proximal tibia

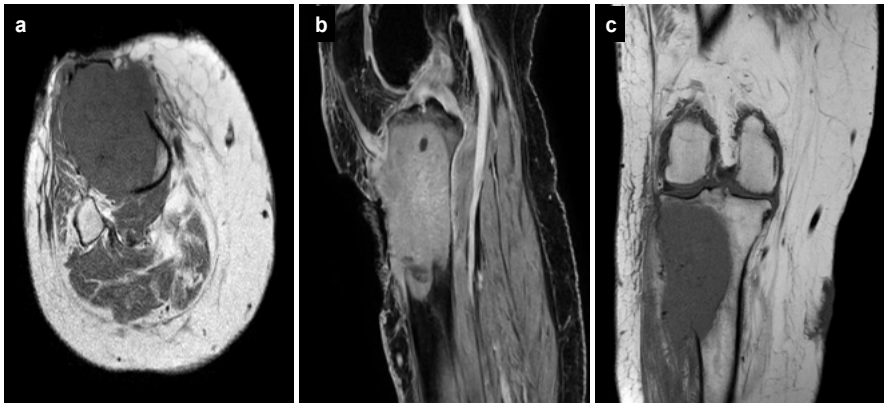

Figure 3. a) T1-weighted axial cut of proximal tibia; b) T2-weighted sagittal cut; and c) T1-weighted coronal MRI images

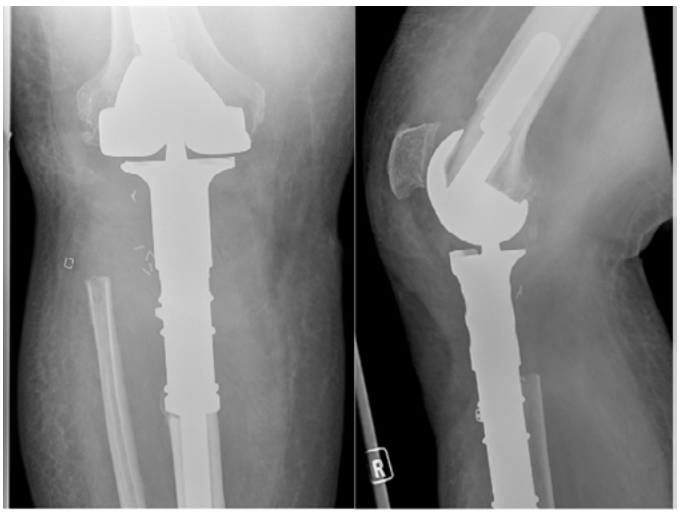

Figure 4. Postoperative X-rays showing proximal tibial replacement

Pathologic histology findings

Macroscopically the overlying skin and soft tissue showed an ulcerating specimen measuring 14.5 × 9.5 cm invading the proximal tibia (*Figure 5*). Microscopically the tumour comprised a variable proportion of atypical basaloid cells, ghost cell outlines and areas of reactive new bone formation (*Figure 6*). Mitoses numbered up to 7 per 10 high power fields, there was no tumour necrosis present, and the soft tissue and distal bone resection margins were clear of tumour.



Figure 5. Macroscopic excised proximal tibia lesion

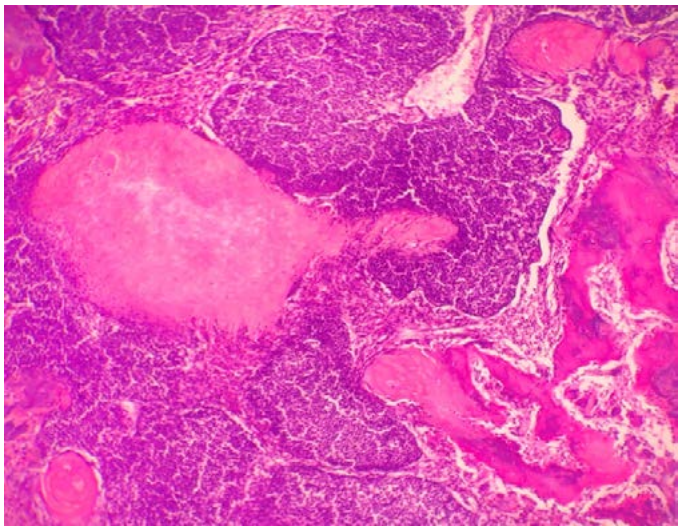

Figure 6. Histology showing variable proportion of atypical basaloid cells and ghost cell outlines, invading between bony trabeculae

There were no postoperative complications, and the wounds healed well. The patient then had postoperative radiation dose 66 Gy treatment which caused minor superficial wound breakdown and which was treated conservatively with conventional dressings. The patient is currently disease free and walks with a single crutch.

Discussion

While pilomatrixomas are benign tumours of the skin, certain cases can demonstrate aggressive characteristics, such as deep tissue invasion and even bone invasion. Malignant pilomatrixomas, however, are rare, with fewer than 100 cases reported in the literature.[6] There has been no pilomatrixoma carcinoma of bone described to our knowledge.

The transformation of pilomatrixoma into a malignant form remains poorly understood, but theories suggest a possible link to genetic mutations affecting hair follicle differentiation pathways. In this case, despite extensive bone invasion, no distant metastasis was observed, consistent with prior studies indicating that metastasis in pilomatrixoma carcinoma is extremely rare.[6] Some intraosseous pilomatrixomas have been associated with Gardner syndrome,[11] but this patient had no identifiable genetic syndrome.

Histopathological analysis is crucial for distinguishing benign from malignant pilomatrixomas. Key features include basaloid cells, ghost cells, and areas of calcification. In this case, the presence of a sheet-like growth pattern and invasion into the tibia, along with a high mitotic index, confirmed the diagnosis of pilomatrixoma carcinoma. The absence of necrosis and a high mitotic count are typical of pilomatrixoma carcinomas but may vary with tumour aggressiveness.[4] The large size of the lesion was also a concerning factor indicating malignancy. To our knowledge it is the largest reported pilomatrixoma carcinoma invading not only deep soft tissues, but also bone.

The management of pilomatrixoma carcinoma, particularly in cases with bone invasion, necessitates a multidisciplinary approach. In this case, a wide local excision of the skin and bone lesion was performed to ensure clear surgical margins, as incomplete excision is linked to recurrence.[3] This approach aligns with strategies used in other aggressive soft tissue and bone tumours, where surgical resection is paired with reconstruction to preserve limb functionality.[3]

Radiation and chemotherapy are typically of limited benefit in treating pilomatrixoma carcinoma due to its low metastatic potential. Most cases are successfully treated with surgery alone, with recurrence usually localised rather than systemic.[5] For this patient, we considered that postoperative radiotherapy was indicated as a local recurrence would probably lead to an amputation, and the previous 'whoops' procedure added further risk to local recurrence, in our opinion. Long-term follow-up is necessary to ensure early detection of any recurrence.

Conclusion

This case of pilomatrixoma carcinoma with extensive invasion into the proximal tibia is a rare and noteworthy finding. It highlights the need for a high index of suspicion when treating large pilomatrixomatous lesions and consideration for preoperative imaging. Aggressive surgical intervention, including bone resection, in managing large or recurrent pilomatrixomas is advised. Although metastasis is rare, continuous monitoring is essential to detect any recurrence. This case contributes valuable insights into the management of pilomatrixoma carcinomas, particularly those with atypical presentations such as bone involvement.

Ethics statement

The authors declare that this submission is in accordance with the principles laid down by the Responsible Research Publication Position Statements as developed at the 2nd World Conference on Research Integrity in Singapore, 2010.

Prior to the commencement of the study ethical approval was obtained from the following ethical review board: University of Cape Town Human Research Ethics Committee (UCT HREC REF: 124/2025).

All procedures were in accordance with the ethical standards of the responsible committee on human experimentation (institutional and national) and with the Helsinki Declaration of 1975, as revised in 2008.

Informed written consent was obtained from the patient for being included in the study.

Declaration

The authors declare authorship of this article and that they have followed sound scientific research practice. This research is original and does not transgress plagiarism policies.

Author contributions

NWN: data capture, data analysis, first draft preparation, manuscript preparation, manuscript revision

TH: study conceptualisation, data analysis, study design, design of testing set-up, manuscript revision

HCFB: data analysis, manuscript revision

AMON: first draft preparation, manuscript preparation

JH: data capture, data analysis, manuscript revision

ORCID

Ncana NW https://orcid.org/0009-0002-2314-6849
Hilton T https://orcid.org/0000-0002-6178-5062
Bauer HCF https://orcid.org/0009-0002-7010-4545
Nasar AMO https://orcid.org/0000-0002-2328-7660
Hauptfleisch J https://orcid.org/0009-0007-1322-4301

References

1. Hurt M, Kaddu S, Kutzner H, et al. Benign tumours with follicular differentiation in Pathology and Genetics of Skin. 2006;152-63 tumours. Lyon: IARC Press.
2. Rozeta S, Lazar T, Biljana A, et al. Treatment of pilomatrixoma in pediatric population–our experience. Acta morphologica 2021;18(2):60-63.
3. Wickremaratchi T, Collins C. Pilomatrixoma or calcifying epithelioma of Malherbe invading bone. Histopathology 1992;21(1):79-81.
4. Kim YS, Na YC, Huh WH, Kim JM. Malignant pilomatricoma of the cheek in an infant. Arch Craniofac Surg. 2018;19(4):283.
5. Forbis R, Helwig EB. Pilomatrixoma (calcifying epithelioma). Arch Dermatol. 1961;83(4):606-18.
6. Gould E, Kurzon R, Kowalczyk AP, Saldana M. Pilomatrix carcinoma with pulmonary metastasis. Report of a case. Cancer. 1984;54(2):370-72.
7. Jones C, Twoon M, Ho W, et al. Pilomatrix carcinoma: 12-year experience and review of the literature. J Cutan Pathol. 2018;45(1):33-38.
8. Nishioka M, Tanemura A, Yamanaka T, et al. Pilomatrix carcinoma arising from pilomatricoma after 10-year senescent period: immunohistochemical analysis. J Dermatol. 2010;37(8):735-39.
9. Tselis N, Heyd R, Vogt H-G, Zamboglou N. Pilomatrix carcinoma with lymph node and pulmonary metastases. Strahlenther Onkol. 2006;182(12):727.
10. Pauly M, Subramanian K, Anantharaman G, Anthony E. Pilomatrix carcinoma of the eyebrow. Ophthalmic Plast Reconstr Surg. 2015;31(1):e9-e10.
11. Ishida T, Abe S, Miki Y, Imamura T. Intraosseous pilomatricoma: a possible rare skeletal manifestation of Gardner syndrome. Skelet Radiol. 2007;36:693-98.