CURRENT CONCEPTS REVIEW

Decision making in trimalleolar ankle fracture management: a current concepts review

Fred M Louw*

Department of Orthopaedics, University of Cape Town and Groote Schuur Hospital; Chris Barnard Netcare Hospital; New Somerset Hospital, Cape Town, South Africa

**Corresponding author: fredlouw@icloud.com*

Citation: Louw FM. Decision making in trimalleolar ankle fracture management: a current concepts review. SA Orthop J. 2026;25(3):155-160. http://dx.doi.org/10.17159/2309-8309/2026/v25n3a9

Editor: Prof. Nando Ferreira, Stellenbosch University, Cape Town, South Africa

Received: July 2025

Accepted: February 2026

Published: August 2026

Copyright: © 2026 Louw FM. This is an open-access article distributed under the terms of the Creative Commons Attribution Licence, which permits unrestricted use, distribution and reproduction in any medium, provided the original author and source are credited.

Funding: No funding was received for this study.

Conflict of interest: The author declares he has no conflicts of interest that are directly or indirectly related to the research. He is a consultant to orthopaedics company Paragon Orthopaedic Products; however, no financial remuneration, sponsorship, funding or support from Paragon was received in relation to this study.

Abstract

Decision making regarding the management of trimalleolar and more so, posterior malleolar ankle fractures, elicits much debate. The concerns relate to the poorer outcomes seen in ankle fractures with associated posterior malleolar fractures due to articular incongruity, syndesmotic instability as well as the increased risk of post-traumatic arthritis. Opinions differ as to which posterior malleolar fractures (PMF) to fix, surgical approaches, fracture fixation methods, fracture fragment size, and if the posterior malleolar fracture may be fixed indirectly from the front. Historical management limitations include reliance on posterior malleolus fragment size alone, if the fracture can be fixed by indirect AP screw, as well as the absence of computed tomography (CT)-based assessment.

Advances in CT scans have led to them, in addition to standard ankle X-rays, being recommended for all trimalleolar ankle fractures. These are essential for adequate preoperative evaluation as well as surgical planning of these complex injuries.

In the absence of a specific trimalleolar ankle fracture classification, a combination approach using the CT-based posterior malleolar fracture classifications with existing ankle fracture classifications (OTA and Herscovici) are recommended to best assess and plan management.

Direct surgical approach with accurate anatomical reduction and stabilisation of these complex fractures is recommended and associated with optimal outcomes. The posterior surgical approach to the ankle has become the standard of care for PMF fixation. Here both posteromedial and posterolateral or combined approaches are recommended to address both posteromedial and posterolateral fracture fragments. More prospective studies regarding trimalleolar ankle fracture outcomes and classification are required.

Contemporary evidence-based studies confirm that posterior malleolus (PM) fracture morphology, articular congruity, syndesmotic stability and posteromedial fracture extension are more important than fracture size alone regarding decision making and outcomes.

This review summarises the evolution in current management strategies, including the latest classification systems, while discussing the evidence supporting direct PM fixation techniques. A treatment algorithm is proposed using CT assessment, fracture morphology, and ankle stability to enhance surgical planning and optimal patient outcomes.

Level of evidence: 5

Keywords: trimalleolar ankle fracture, posterior malleolus, syndesmotic injury, decision making, operative management

Introduction

Trimalleolar fractures represent the most complex of ankle fractures. These injuries elicit much debate. They are a combination of posterior, medial and lateral malleolar fractures with associated ligamentous injury and instability.[1] Anatomical knowledge of both bony and ligamentous ankle stabilising structures is essential to understanding these injuries. Further concerns are related to their increasing incidence.[2-4] Most debate is directed toward the posterior malleolar fracture (PMF) component of the injury.[5-9] These are avulsion fractures representing an injury to the posterior inferior tibiofibular ligament (PITFL) insertion, where the fracture frequently extends into the posterolateral plafond, incisura fibularis and/or weight-bearing surface involving both the syndesmosis and articular surface and subsequent instability.[2,5] Debate persists regarding the posterior malleolar fragment size, classification, surgical approach, fixation and management. PMF are independently associated with poorer outcomes, as well as trimalleolar fractures.[6,10-14] CT scans in addition to X-rays are essential in understanding the fracture complexity and tailoring of the management plan.[1,5,7,8] This is due to the great variation displayed in PMF presentation and complexity.[8] This article intends to bring clarity to these debated topics and provide guidelines for decision making in the management of these complex ankle injuries.

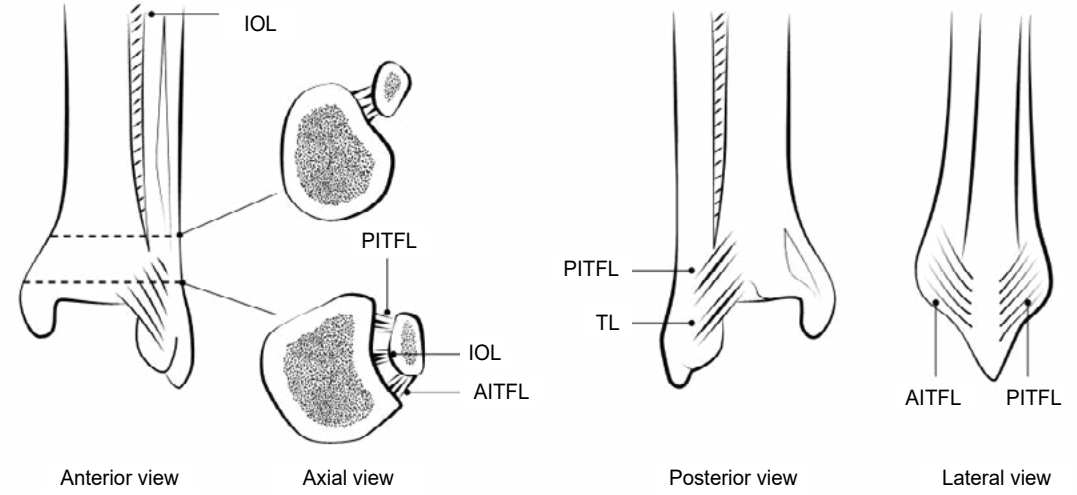

Figure 1. Ankle syndesmosis anatomy

AITFL: anterior inferior tibiofibular ligament; IOL: interosseus ligament; PITFL: posterior inferior tibiofibular ligament; TL: transverse ligament

Anatomy

Both bony and ligamentous anatomical knowledge of the ankle is essential to understanding and managing trimalleolar ankle fractures.[3,5,15] Bony stability is created by the three-bone ankle comprising the tibia and fibula forming the ankle mortise which includes the three malleoli (posterior, medial and lateral malleoli) covering the talus. The posterior malleolus (PM) forms the posterior lip of the plafond which contributes to its concave shape, giving congruency and stability to the ankle joint.[16] The PM provides the origin for the PITFL, the major contributing stabilising ligament of the syndesmosis. The PM is key to ankle loadbearing, preventing posterior talus dislocation and providing stability as well as the insertion of the PITFL.[17]

Ligamentous stability between the distal tibia and fibula is provided by the syndesmotic complex (*Figure 1*). This three-part complex connecting the distal tibia and fibula consists of the anterior inferior tibiofibular ligament (AITFL) in front, the interosseus ligament in between, and the PITFL at the back being the strongest of the three (*Figure 1*). These three ligaments resist axial, translational and rotational forces attempting the separate the tibia and fibula.[15] Accurate knowledge of the syndesmotic ligament insertions go a long way to explaining trimalleolar fracture fragments, as many of these are avulsion fractures (*Figure 1*). Reducing these fractures anatomically allows for perfect reduction of intra-articular fragments as well as balancing these essential ankle-stabilising ligaments. Failure to do so may result in instability and subluxation of the ankle, leading to pain, disability and arthritis.[16,18]

Assessment and radiology

Standard emergency assessment and reduction of fractures is essential. The management of open fractures and compartment syndrome is beyond the scope of this review and hence omitted.

After the closed trimalleolar ankle fracture has been reduced and held with cast, radiological assessment should follow. X-rays and CT scans are mandatory (*Figure 2*). Controversy as to whether to CT scan or not has been laid to rest.[1,5,7,8] These complex fractures cannot be adequately assessed without a CT scan. PMFs are complex, with great variation, and may have comminution, intercalary fragments, tibial plafond impactions/dye punch impactions and AITFL avulsion fractures, which may be missed on standard X-rays. X-rays unfortunately fail to adequately evaluate the complexity of PMF.[8,19,20] Medial and lateral malleolar fracture (MMF, LMF) complexity is also best evaluated by CT



Figure 2. Trimalleolar ankle fracture X-rays

scan.[21] MMFs may extend to posteromedial, and LMFs may be fragmented or have often missed AITFL avulsion fragments (Wagstaffe–Le Fort fracture) seen only on CT scan. CT scans are essential for complete understanding of the trimalleolar fracture patterns, surgical planning as well as all PMF classification systems being CT based.[8,22] CT scanning of all trimalleolar fractures is the standard of care and hence strongly advised.

Classification

No comprehensive all-encompassing classification system exists for trimalleolar fractures.[1,22] In the absence thereof the classifications are subdivided into medial, lateral and posterior malleolar fracture classification.[1,23] These systems help guide surgical decision making and approaches.

MMF classification

The Herscovici classification[24] is the most used in literature (*Figure 3*). Herscovici type A–C fractures are associated with screw/hook plate fixation, while the more vertically oriented type D fracture pattern is managed with plate fixation (anti-glide). This is despite the Herscovici classification not being associated with type of fixation.[23,24] Interobserver reliability is moderate, whereas intraobserver reliabilities showed substantial agreement.[1] The weakness of this classification relates to being based on an anteroposterior (AP) X-ray view only. Furthermore, it cannot assess sagittal medial malleolar fragments or PMFs with posteromedial fragments extending into the medial malleolus.[21] Other medial

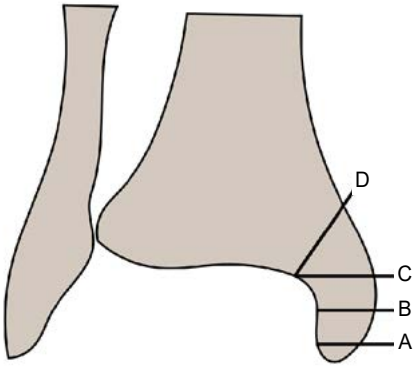

Figure 3. Herscovici et al. medial malleolus fracture classification 2007[24]
A - Type A: avulsion of tip of the medial malleolus
B - Type B: fracture between the tip and the level of the tibial plafond
C - Type C: fracture at the level of the tibial plafond
D - Type D: vertical fracture extending above the tibial plafond

malleolar classification systems (AO/OTA, Lauge-Hanson[25,26]) combine medial malleolar classification with ankle fractures but unfortunately also fail to assess medial malleolar complexity and sagittal fracture fragments.[1] CT scan assessment is hence recommended for best medial malleolar fracture assessment.[21]

LMF classification

Lateral malleolus AO/OTA classification as per Muller[25] from AO is based on LMF and MMF patterns based on an anteroposterior ankle X-ray (*Figure 4*). This gives good information by classifying and dealing with medial and lateral malleolar fractures.[1,3] This classification is lacking on posterior malleolar classification as it relies only on an anteroposterior X-ray.

PMF classification

The original X-ray PMF fragment size-based classification by Nelson et al.[27] from a publication in 1940 based on only eight cases has been thoroughly debunked and strongly advised not to be used.[1,2,7,8,28] X-rays give insight into medial and lateral malleoli fractures, as well as assessing fracture reduction, but are inadequate when evaluating PMFs.[23,28,29] CT scans are essential for PMF evaluation and surgical planning.[1,8,23]

Three CT scan-based classifications are commonly used.[5,7,8,22] All three have their advantages:

a. Haraguchi classification (*Figure 5a*). This was the first CT-based PMF classification from 2006 and the simplest.[8] The classification is based on axial CT views. There are three types: type 1 pure PMF; type 2 PMF extension to medial malleolus; type 3 extra-articular fragment of PMF (*Figure 5a*). Criticism involves that there is no severity basis and hence it is not outcome based. Medial injuries are also not evaluated, and the classification may not cover all fracture types.[23]
b. Mason and Malloy classification (*Figure 5b*) is a simple and easy to interpret modification of the Haraguchi classification, as well as being a good surgical guide as to where and in which sequence to fix PMF fragments.[7,30] This classification further looks at injury mechanism, absent in Haraguchi's classification. The advantage pertains to planning of the surgical approach as well as sequence of fixation.[30]
c. Type 1 small shell-like PMF fragments (type 1) are not fixed, rather fixing both medial and lateral malleoli (*Figure 6*). These are small, unfixable PMFs.
d. Type 2 posterior fragments are divided into pure posterior (type 2a) requiring a posterolateral approach for surgical fixation versus fragments with *both* posterolateral and posteromedial fracture fragments (type 2b).

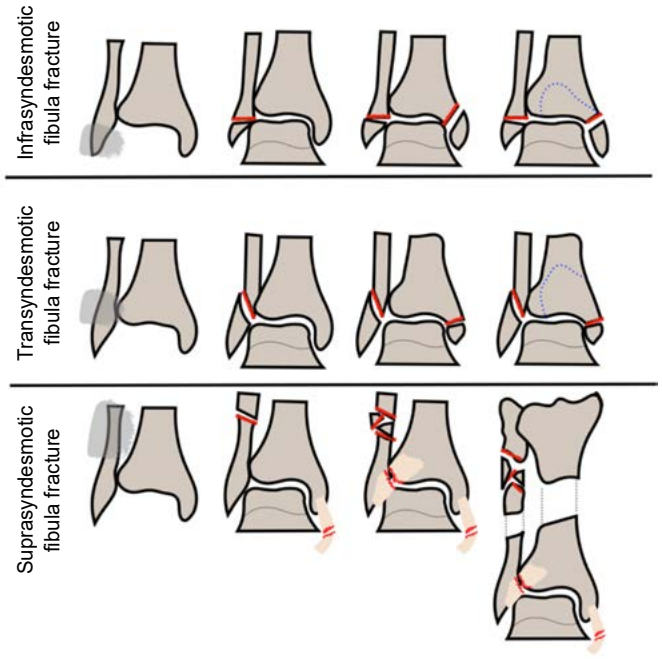

Figure 4. AO/OTA ankle fracture classification

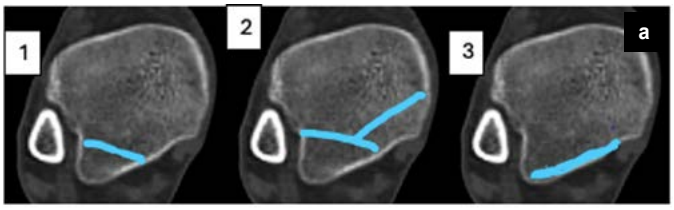

Figure 5a. Haraguchi PMF classification

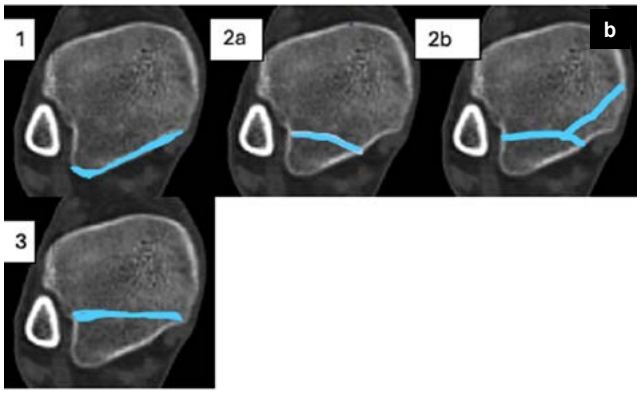

Figure 5b. Mason and Malloy PMF classification

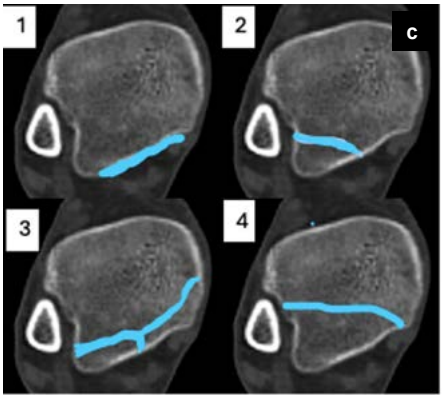

Figure 5c. Bartoniček and Rammelt PMF classification

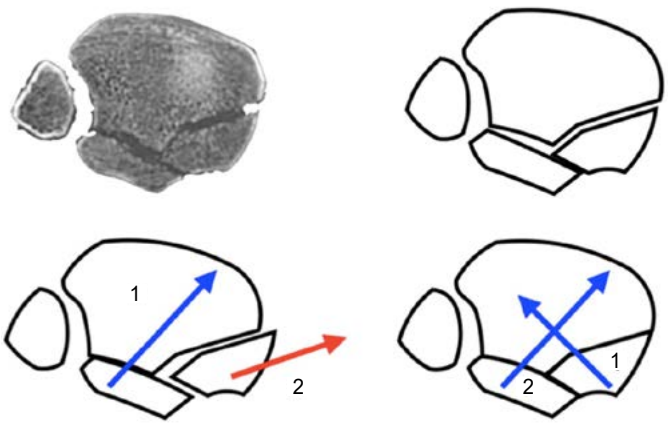

Figure 6. Mason and Malloy sequence of fixation approach to type 2b fracture:[7] posteromedial fragment fixation first through separate incision, followed by posterolateral fragment fixation. This prevents displacement of fragments during fixation (used with permission from authors).

e. Type 3 are large posterior fragments with extension medially beyond the posterolateral fragment with associated involvement of the weight-bearing articular surface. Pure posterior malleolar fragments (type 2a and 3) are fixed with a posterolateral approach and fixation. The two-part PMFs (type 2b) are recommended to be fixed separately through a posteromedial or medial posteromedial incision *first* and a second posterolateral incision (*Figures 6 and 7*). Should this sequence not be followed, malreduction of the fragments is likely (*Figure 6*). This classification offers this added benefit with surgical planning.
f. Bartoníček and Rammelt et al. (*Figure 5c*) have the most differentiated PMF classification, with stability of the ankle joint as well as fibular notch integrity being assessed.[5] A recent review article has recognised this classification which has the greatest potential with its treatment algorithm.[23] This classification follows a worsening severity from types 1–4 and suggests treatment methods thereof. There is correlation between worse outcomes and fracture severity. As both Mason et al. and Bartonićek et al. are later modifications of Haraguchi, the use of either is advised.[22] The literature, however, seems to prefer Bartonićek.[1,22,23]

Conservative management?

Trimalleolar fractures are mostly treated operatively. There are concerns with poorer surgical outcomes in non-operatively treated fractures.[2,31-33] It is also difficult to assess these fractures with standard X-rays to determine if the fractures have displaced.[1,6,20,24,25] Non-operative treatment is generally reserved for undisplaced fractures (confirmed on CT) or patients unfit for surgery.[30]

Surgical management of closed trimalleolar ankle fractures: when and how

When?

Closed trimalleolar fractures require surgery sooner rather than later, post urgent fracture reduction, CT scan and planning. The literature is inconclusive on when it is safest to operate but several studies show no difference in post-surgical wound site infection or wound breakdown between cases done earlier rather than later.[3,4,34,35] These surgeries may be done earlier (within one to five days) as long as swelling is not overt. Earlier surgery may have added benefits of easier reduction of fracture, decreased hospital stay, and shorter surgery. That being said, these are complex surgical cases and are best managed in daylight hours by appropriate and experienced specialists.

Fracture blisters and severe ankle swelling would delay surgery.

Does PMF size matter?

Several recent studies refute the age-old PMF size,[18] and further, confirm poorer outcomes with unfixed displaced PMFs.[6,7,13,36] These are complex and unstable fractures and most require surgical fixation. The only PMFs not requiring fixation are small (unfixable), shell-type fractures or non-operatively managed undisplaced PMFs (*Figures 5a-3, 5b-1, 5c-1*). Accurate anatomical reduction and fixation is associated with the best bony congruity and ligamentous stability and long-term outcomes.[2,33]

Positioning

Both prone and lateral positioning are used commonly to fix these fractures,[37,38] and the optimal recovery positioning for surgical access is determined by the surgeon. Both positions give good posterior access to the PMFs and LMFs. Ankle rotation allows access to the MMF in lateral positioning cases. Turning the case to supine from prone helps with medial malleolar access.[38] Both approaches have advantages and disadvantages. The positioning the surgeon is most comfortable with is recommended. Further discussion is beyond the scope of this article

Surgical approach

The surgical approach depends on the PMF size and morphology (*Figure 7*).

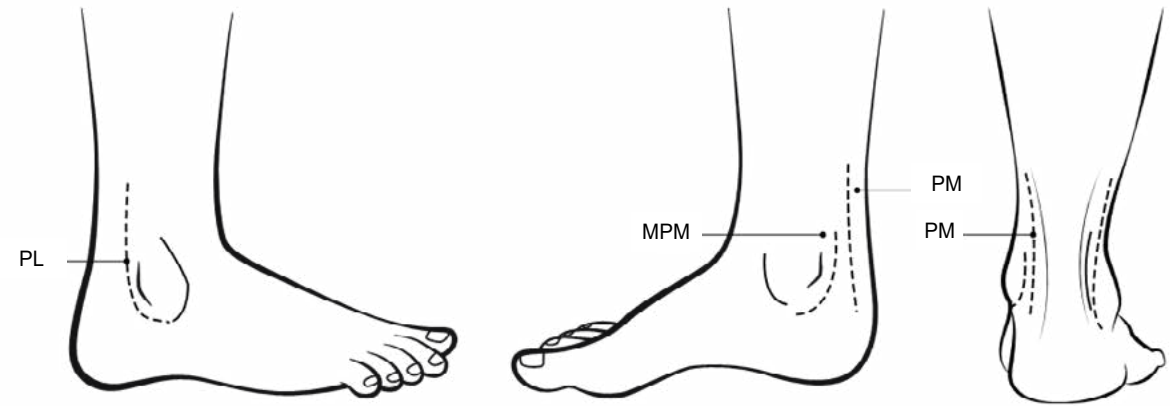

Figure 7. Posterior ankle surgical approaches

PL: posterolateral approach; MPM: medial posteromedial approach; PM: posteromedial approach

Most PMFs require fixation, depending on the CT scan evaluation of the PMF. Accurate anatomical reduction and fixation of the PMF involving the incisura recreates the fibula notch and helps with reduction of the fibula.[2,5,7] This step is essential as malreduction will result in a poor result.[2,4] The surgical approach aims to *directly address* the posterior fracture fragments from a posterolateral or combined posteromedial and posterolateral approach. The posterolateral approach will allow for both PMF and LMF reduction and fixation. Added to this, a standard medial surgical approach for anteromedial malleolar fracture fixation or posteromedial/medial posteromedial approach for posteromedial and medial fracture fixation is recommended (*Figure 7*). Careful management of peripheral nerves and meticulous care with soft tissues are essential with these approaches.[4] The posterolateral approach may present difficulty with posteromedial fragment access while anteromedial and anterolateral fragment access may be problematic with the posterior approach.[37,38]

Which PMFs do not require fixation?

Only small shell-type extra-articular PMF fragments do not require fixation as they are too small to fix.[5,7,36] Simply fix medial and lateral malleolus with added syndesmosis fixation. These cases may be operated supine following standard bimalleolar ankle fracture fixation techniques.[36]

Sequence of trimalleolar fracture fixation

Fix the PMF *first* and always before lateral malleolus.

Fixing the lateral malleolus first leads to an inability to assess the PMF reduction on fluoroscopy due to lateral hardware overlying the joint and obstructing assessment of PMF reduction.[2,39] The surgical approach is to go directly to where the fracture is posteriorly first, carefully and accurately reduce and fix it. Axial CT scan is invaluable in preoperative planning.[1,5,8,29] In most cases the standard posterolateral approach will suffice for fixation. The exception to this approach is PMFs with both posteromedial and posterolateral fragments (Mason and Malloy type 2b, Bartonićek type 3, *Figure 5*). These PMFs require a *sequence of surgical fixation*, with each fragment fixed separately (*Figure 6*). First up is fixation of the posteromedial fragment, through a posteromedial or medial posteromedial approach. The reason, as explained by Mason and Malloy (*Figure 6*): fixation of the lateral fragment first leads to malreduction of the medial fragment and hence posteromedial fragment fixation first is advised.[7] This is followed by fixation of the posterolateral fragment through a posterolateral approach.

Once the PMF is fixed, the LMF may be fixed (through same posterolateral surgical approach) with added syndesmosis fixation as required. The LMF may be fixed with a posterior or standard lateral plate. Take care in reducing any AITFL anterior fibula avulsion fragments. This may be done through the posterolateral or direct lateral/anterolateral approach.

And lastly, the MMF fixation is addressed. Screw fixation is used in most cases, except for small avulsion fractures, which require a hook plate, and vertical fractures requiring a buttress plate.[24]

Fixation of fractures

PMFs require direct fixation from posterior and preferably a small anti-glide buttress plate or a cannulated screw with washer once anatomically reduced.[40] Posterior-based direct plating is biomechanically stronger than screw fixation.[4,40,41]

Posterior plating is associated with better radiological outcomes and stability, while posterior-to-anterior (PA) screw fixation provides better functional and pain scores. Posterior-based plating is associated with greater implant issues, and tissue scarring due to increased soft tissue dissection.[17] Smaller PMF fragments do better with screw fixation, while larger fragments are likely to benefit more from plating.[17]

With this in mind, it is recommended to choose between screw versus plate fixation on a case-by-case basis.

The LMF may be plated from posterior or lateral using the posterolateral approach.

The MMF is fixed from a medial posteromedial (MPM) or anteromedial approach (*Figure 6 and 7*) with screws, hook or buttress plate as mentioned before.

Assessment of PMF reduction

PMF reduction is difficult to assess as you cannot visualise intra-articular reduction of fragments directly from the posterior approach. Accurate reduction of a PMF is associated with better surgical outcomes.[2,6,17,33] Lateral fluoroscopy is best done before lateral malleolus fixation for best PMF reduction visualisation. Lateral plates will likely obscure your visualisation of PMF reduction.

'Look twice and feel' approach

My approach is to first *look* confirming accurate reduction of the proximal (non-articular) PMF edges. Second, *look* and confirm fracture reduction on lateral ankle view fluoroscopy.

Lastly *feel*, confirming a smooth feel to the proximal edges of the fracture with your finger holding the fracture helps with assessing accurate reduction. Any irregular feel confirming a step to fracture edge proximally is a guide to inadequate reduction. Difficulty in reduction may be due to an unrecognised or small intercalary fracture fragment, or an impacted tibial plafond fracture. Once the fracture is reduced with your thumb or clamp, the fracture may be fixed with K-wires and checked with fluoroscopy before definitive fixation. Intraoperative CT scanning, if available, is another option to assess reduction of the PMF as well as syndesmotic alignment and articular congruity.[42-44]

Intercalary PMF fragments, impacted plafond and cartilage fragments

These need to be found and reduced accurately if displaced or impacted. They are associated with a poorer surgical outcome if not addressed or properly reduced.[2,5,7,10,12,45] Preoperative CT scan is an invaluable guide as to where these fragments are for surgical planning. These fragments are often difficult to access and reduce. Take care while doing so. The fragments are addressed looking downward from proximal to the ankle joint. Open and separate the PMF carefully (so as not to break the fracture fragment edge), carefully disimpact, and reduce using fluoroscopy to aid assessment of reduction. Only very small, irreducible intercalary fragments may be removed or washed out – so too removal of irreparably damaged cartilage fragments as these fragments may block fracture reduction. All other intercalary fragments require accurate reduction. Do not over-reduce these fragments as it will lead to a step in the joint. The transfibular fracture approach of Weber[2,46] to intercalary fragments or impacted plafond fractures may be considered to access and reduce these fragments, while using the posterior approach should they be irreducible from the standard posterior approach.

Indirect PMF fixation from anterior?

PMFs are avulsion or shear-type fractures. Accurate reduction of these fractures is required to reduce the articular surface as well as restoring the anatomical alignment and PITFL tension and stability.[5] Indirect fixation from the front is associated with poor reduction of the fragments, poorer biomechanical fixation, as well as having limited ability to assess reduction other than fluoroscopy.[2,40,41] Poor reduction of PMFs is associated poor surgical outcomes.

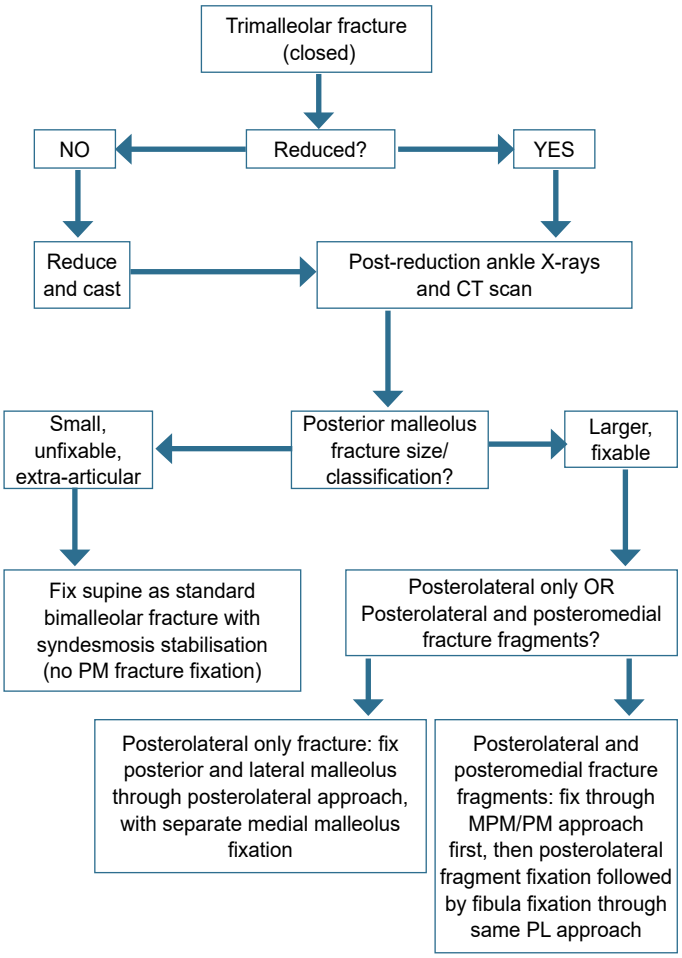

Figure 8. A proposed management algorithm for trimalleolar ankle fractures incorporating posterior malleolar fracture morphology and CT assessment

Furthermore, intra-articular fragments cannot be addressed if fixed from the front. This approach is hence not advised.

Syndesmosis fixation

Anatomical reduction and fixation of the trimalleolar fractures reestablishes the correct PITFL tension and subsequently the syndesmosis stability requires intraoperative assessment. Standard hook or external rotation stress testing with fluoroscopy is advised. The posterolateral approach unfortunately does not allow for direct visualisation of the distal tibiofibular syndesmotic reduction. There is a risk of malreduction with indirect syndesmosis fixation, and modified direct open exposure of syndesmosis is advised to visualise and address this issue.[47-49] Should this fail, intraoperative CT scan to assess syndesmotic reduction, if available, is advised.[42-44] Stable syndesmosis post fixation will not require a transfibula-to-tibia syndesmotic fixation.[18] If there is any doubt as to syndesmotic stability, standard fibula-to-tibia fixation is advised. Fixation choices vary from screw fixation (one versus two screws), suture button fixation (one or two buttons) or hybrid fixation (screw and suture button). Multiple meta-analyses and randomised trials suggest at least similar if not superior outcomes and lower repeat operation rates with hybrid constructs using screws and suture buttons or suture buttons alone.[50-55]

Learning points

Urgent reduction of ankle fracture and temporary cast immobilisation is advised.

CT scans are essential for preoperative evaluation and trimalleolar fracture assessment, so too classification and operative planning. No classification system exists to classify all three fractures; the use of at least two classifications is advised when deciding on definitive management (OTA, Herscovici, PMF classification[1,22,23]).

Early planned surgery is preferable (unless there are blisters or severe swelling).

Be comfortable with surgical positioning and the posterior ankle surgical approaches.

Direct posterior approach ankle surgery and fixation to PMFs provides more accurate PMF reduction and better outcomes and is strongly recommended.

Indirect fixation of PMFs is *not* advised.

Following a sequence of trimalleolar ankle fracture fixation is advised, starting with the PMF.

Intercalary PMF fragments and plafond impaction fragments require careful reduction.

Anatomical restoration of the ankle bony anatomy and ligamentous stability is associated with the best outcomes.[56] A proposed management algorithm for trimalleolar ankle fractures incorporating PMF morphology and CT classification is given in *Figure 8*.

Conclusion

Trimalleolar fractures are complex injuries, requiring stepwise preoperative assessment and planning. Early urgent closed reduction of these unstable fractures with casting and CT scanning is mandatory. Surgical planning with CT scan guidance allows for the best surgical management. There is a need for one classification system that encompasses all three fractures and assesses severity with outcome measures guiding treatment. Surgeons should be comfortable with posterior surgical approaches to the ankle, as these are required in most cases. Following a sequence of fixation is advised, addressing the PMF reduction first. Meticulous surgical care should be taken with soft tissues and accurate anatomical reduction, and stable fixation of bone allows for best clinical outcomes. Intercalary fracture fragments and complex PMFs are associated with poorer outcomes. More studies regarding trimalleolar fracture classification and outcomes are required.

Ethics statement

The author declares that this submission is in accordance with the principles laid down by the Responsible Research Publication Position Statements as developed at the 2nd World Conference on Research Integrity in Singapore, 2010.
Informed written consent was not necessary for this review as it does not contain any studies with human or animal subjects.

Declaration

The author declares authorship of this article and that they have followed sound scientific research practice. This research is original and does not transgress plagiarism policies.

Author contributions

FML: performed all aspects of this work including conceptualisation, study design, literature review, data capture, data analysis, first draft preparation, manuscript revision and final manuscript preparation

ORCID

Louw FM https://orcid.org/0000-0002-0542-3497

References

1. Pflüger P, Harder F, Müller K, et al. Evaluation of ankle fracture classification systems in 193 trimalleolar ankle fractures. Eur J Trauma Emerg Surg. 2022 Oct 1;48(5):4181-81.
2. Rammelt S, Bartoníček J. posterior malleolar fractures: a critical analysis review. JBJS Rev. 2020 Aug;8(8):e19.00207. https://doi.org/10.2106/JBJS.RVW.19.00207
3. Pflüger P, Braun KF, Mair O, et al. Current management of trimalleolar ankle fractures. EFORT Open Rev. 2021 Aug;6(8):692-703.

4. Neumann AP, Kroker L, Beyer F, Rammelt S. Complications following surgical treatment of posterior malleolar fractures: an analysis of 300 cases. Arch Orthop Trauma Surg. 2023 Jun;143(6):3129-36.
5. Bartoníček J, Rammelt S, Kostlivý K, et al. Anatomy and classification of the posterior tibial fragment in ankle fractures. Arch Orthop Trauma Surg. 2015 Apr 1;135(4):505-16.
6. Odak S, Ahluwalia R, Unnikrishnan P, et al. Management of posterior malleolar fractures: a systematic review. J Foot Ankle Surg. 2016 Jan-Feb;55(1):140-45.
7. Mason LW, Marlow WJ, Widnall J, Molloy AP. Pathoanatomy and associated injuries of posterior malleolus fracture of the ankle. Foot Ankle Int. 2017 Nov 1;38(11):1229-35.
8. Haraguchi N, Haruyama H, Toga H, Kato F. Pathoanatomy of posterior malleolar fractures of the ankle. J Bone Joint Surg Am. 2006 May;88(5):1085-929.
9. Stringfellow TD, Walters ST, Nash W, Ahluwalia R. Management of posterior malleolus fractures: A multicentre cohort study in the United Kingdom. Foot Ankle Surg. 2021 Aug 1;27(6):629-35.
10. De Vries JS, Wijgman AJ, Sierevelt IN, Schaap GR. Long-term results of ankle fractures with posterior malleolar fragment. J Foot Ankle Surg. 2005 May;44(3):211-17.
11. McDaniel WJ, Wilson FC. Trimalleolar fractures of the ankle. An end result study. Clin Orthop Relat Res. 1977 Jan-Feb:(122):37-45.
12. Verhage SM, Krijnen P, Schipper IB, Hoogendoorn JM. Persistent postoperative step-off of the posterior malleolus leads to higher incidence of post-traumatic osteoarthritis in trimalleolar fractures. Arch Orthop Trauma Surg. 2019 Mar 12;139(3):323-29.
13. Veltman ES, Halma JJ, de Gast A. Longterm outcome of 886 posterior malleolar fractures: A systematic review of the literature. Foot Ankle Surg. 2016 Jun;22(2):73-714.
14. Solan MC, Sakellariou A. Posterior malleolus fractures worth fixing. Bone Joint J. 2017;(11):99-1413.
15. Golanó P, Vega J, de Leeuw PAJ, et al. Anatomy of the ankle ligaments: A pictorial essay. Knee Surg Sports Traumatol Arthrosc. 2010;18(5):557-69.
16. Nasrallah K, Einal B, Shtarker H. Trimalleolar fracture: The endless posterior malleolus fracture debate, to repair or not to repair? Orthop Rev (Pavia). 2021 Mar 30;13(1).
17. Su YC, Wang YY, Fang CJ, et al. Insights into optimal surgical fixation for posterior malleolar fractures. Bone Jt Open. 2024 Mar 18;5(3):227-35.
18. Gardner MJ, Brodsky A, Briggs SM, et al. Fixation of posterior malleolar fractures provides greater syndesmotic stability. Clin Orthop Relat Res. 2006 Jun;447:165-71.
19. Verhage SM, Hoogendoorn JM, Krijnen P, Schipper IB. When and how to operate the posterior malleolus fragment in trimalleolar fractures: a systematic literature review. Arch Orthop Trauma Surg. 2018 Sep 1;138(9):1213-22.
20. Ferries JS,DeCoster TA, Firoozbakhsh KK etal. Plain radiographic interpretation in trimalleolar ankle fractures poorly assesses posterior fragment size. Journal of Orthopaedic Trauma. 1994;8(4):328-331
21. Liu Y, Lu H, Xu H, et al. Characteristics and classification of medial malleolar fractures. Bone Joint J. 2021;103(5):931-38.
22. Rashid MS, Islam R, Marsden S, et al. Validation of three classification systems for posterior malleolus fractures of the ankle. Eur J Orthop Surg Traumatol. 2023 Aug 1;33(6):2601-608.
23. Terstegen J, Weel H, Frosch KH, et al. Classifications of posterior malleolar fractures: a systematic literature review. Arch Orthop Trauma Surg. 2022 Dec 5;143(7):4181-220.
24. Herscovici D, Scaduto JM, Infante A. Conservative treatment of isolated fractures of the medial malleolus. J Bone Joint Surg Br. 2007 Jan;89-B(1):89-93.
25. Müller ME, Nazarian S, Koch P, Schatzker J. The comprehensive classification of fractures of long bones. Springer; 2012.
26. Lauge-Hansen N. Fractures of the ankle. Arch Surg. 1950 May 1;60(5):957.
27. Nelson MC, Jensen NK, Ir MS, Cooper A. The treatment of trimalleolar fractures of the ankle. Surgery, Gynaecology & Obstetrics. 1940, 71: 509-514
28. Büchler L, Tannast M, Bonel HM, Weber M. Reliability of radiologic assessment of the fracture anatomy at the posterior tibial plafond in malleolar fractures. J Orthop Trauma. 2009 Mar;23(3):208-12.
29. Mangnus L, Meijer DT, Stufkens SA, et al. Posterior malleolar fracture patterns. J Orthop Trauma. 2015 Sep;29(9):428-35.
30. Mason LW, Kaye A, Widnall J, et al. Posterior malleolar ankle fractures: an effort at improving outcomes. JBJS Open Access. 2019 Apr 1;4(2):E0058.
31. Makwana NK, Bhowal B, Harper WM, Hui AW. Conservative versus operative treatment for displaced ankle fractures in patients over 55 years of age. J Bone Joint Surg. 2001 May 1;83(4):525-29.
32. Vacas-Sánchez E, Olaya-González C, Abarquero-Diezhandino A, et al. How to address the posterior malleolus in ankle fractures? A decision-making model based on the computerised tomography findings. Int Orthop. 2020 Jun 4;44(6):1177-85.
33. Miksch RC, Herterich V, Barg A, et al. Open reduction and internal fixation of the posterior malleolus fragment in ankle fractures improves the patient-rated outcome: a systematic review. Foot Ankle Int. 2023 Aug;44(8):727-37.
34. Naumann MG, Sigurdsen U, Utvåg SE, Stavem K. Associations of timing of surgery with postoperative length of stay, complications, and functional outcomes 3–6 years after operative fixation of closed ankle fractures. Injury. 2017 Jul;48(7):1662-69.
35. Schepers T, de Vries MR, van Lieshout EMM, van der Elst M. The timing of ankle fracture surgery and the effect on infectious complications; A case series and systematic review of the literature. Int Orthop. 2013 Mar 4;37(3):489-94.
36. Quan Y, Lu H, Xu H, et al. The distribution of posterior malleolus fracture lines. Foot Ankle Int. 2021 Jul 20;42(7):959-66.
37. Drago SR, Alvarado PAZ, Contreras M, et al. Recovery position vs prone position in the surgical treatment of trimalleolar ankle fractures using posterolateral and medial approach. Foot Ankle Orthop. 2022 Jan 21;7(1).
38. Kurk MB, Albayrak K, Pehlivanoglu G, et al. Does patient position matter? Lateral-to-supine positioning offers surgical and clinical advantages in Trimalleolar ankle fracture fixation. J Foot Ankle Surg. 2025 Dec 20:S1067-2516(25)00385-0.
39. Irwin TA, Lien J, Kadakia AR. Posterior malleolus fracture. J Am Acad Orthop Surg. 2013 Jan 1;21(1):32-40.
40. Wang J, Jia HB, Zhao JG, et al. Plate versus screws fixation for the posterior malleolar fragment in trimalleolar ankle fractures. Injury. 2023 Feb 1;54(2):761-67.
41. Hartwich K, Lorente Gomez A, Pyrc J, et al. Biomechanical analysis of stability of posterior antiglide plating in osteoporotic pronation abduction ankle fracture model with posterior tibial fragment. Foot Ankle Int. 2017 Jan 30;38(1):58-65.
42. Vetter SY, Privalov M, Beisemann N, et al. Influence of ankle joint position on angles and distances of the ankle mortise using intraoperative cone beam CT: A cadaveric study. PLoS One. 2019 May 31;14(5):e0217737.
43. Vetter SY, Euler J, Beisemann N, et al. Validation of radiological reduction criteria with intraoperative cone beam CT in unstable syndesmotic injuries. Eur J Trauma Emerg Surg. 2021 Aug 25;47(4):897-903.
44. Hsu AR, Gross CE, Lee S. Intraoperative o-arm computed tomography evaluation of syndesmotic reduction. Foot Ankle Int. 2013 May 15;34(5):753-59.
45. Blom RP, Hayat B, Al-Dirini RMA, et al. Posterior malleolar ankle fractures. Bone Joint J. 2020 Sep;102-B(9):1229-41.
46. Heim U PK. Internal fixation of small fractures: Technique recommended by the AO-ASIF Group. 3rd ed. Springer; 1988.
47. Baca E, Ziroğlu N. Fixation of posterior malleolus is enough for syndesmotic stability: fact or fiction? Eur Arch Med Res. 2020 Dec 22;36(4):239-45.
48. Regauer M, Mackay G, Nelson O, et al. Evidence-based surgical treatment algorithm for unstable syndesmotic injuries. J Clin Med. 2022 Jan 10;11(2):331.
49. Marinho Guimarães B, Lemos AVKC, Nery CA de S, et al. Modified posterolateral approach for fixation of posterior malleolus fractures associated with distal tibiofibular syndesmosis injury – description of surgical technique. J Foot Ankle. 2025 Sep 2;19(2):5.
50. Xu K, Zhang J, Zhang P, et al. Comparison of suture-button versus syndesmotic screw in the treatment of distal tibiofibular syndesmosis injury: a meta-analysis. J Foot Ankle Surg. 2021 May;60(3):555-66.
51. Onggo JR, Nambiar M, Phan K, et al. Suture button versus syndesmosis screw constructs for acute ankle diastasis injuries: A meta-analysis and systematic review of randomised controlled trials. J Foot Ankle Surg. 2020 Jan;26(1):54-60.
52. Shimozono Y, Hurley ET, Myerson CL, et al. Suture button versus syndesmotic screw for syndesmosis injuries: a meta-analysis of randomized controlled trials. Am J Sports Med. 2019 Sep 26;47(11):2764-71.
53. Lehtola R, Leskelä HV, Flinkkilä T, et al. Suture button versus syndesmosis screw fixation in pronation-external rotation ankle fractures: A minimum 6-year follow-up of a randomised controlled trial. Injury. 2021 Oct;52(10):3143-49.
54. Laflamme M, Belzile EL, Bédard L, et al. A prospective randomized multicenter trial comparing clinical outcomes of patients treated surgically with a static or dynamic implant for acute ankle syndesmosis rupture. J Orthop Trauma. 2015 May;29(5):216-23.
55. Ræder BW, Stake IK, Madsen JE, et al. Randomized trial comparing suture button with single 3.5 mm syndesmotic screw for ankle syndesmosis injury: similar results at 2 years. Acta Orthop. 2020 Nov 1;91(6):770-75.
56. Baumbach SF, Herterich V, Damblemont A, et al. Open reduction and internal fixation of the posterior malleolus fragment frequently restore syndesmotic stability. Injury. 2019 Feb;50(2):564-70.