This open-access article is distributed under Creative Commons licence CC-BY-NC 4.0.

CASE REPORT

First case of VEXAS syndrome in South Africa

J Damelin,[1] MB BCh, Dip HIV Man (SA); **J Jacobson,**[1] MB BCh, Dip HIV Man (SA); **C Bam,**[2] MB ChB, Dip HIV Man (SA); **L Pillay,**[3] MB ChB, FC Derm (SA); **J R du Toit,**[1] MB ChB, Cert Clin Haematol (SA) Phys

[1] *Wits Donald Gordon Cellular and Immunotherapy Centre, School of Clinical Medicine, Faculty of Health Sciences, University of the Witwatersrand, Johannesburg, South Africa*

[2] *Department of Medicine, Groote Schuur Hospital and Faculty of Health Sciences, University of Cape Town, South Africa*

[3] *Department of Dermatology, Helen Joseph Hospital and School of Clinical Medicine, Faculty of Health Sciences, University of the Witwatersrand, Johannesburg, South Africa*

Corresponding author: *J Damelin (jennadamelin8@gmail.com)*

VEXAS (vacuoles, E1 enzyme, X-linked, autoinflammatory, somatic) syndrome is an adult-onset autoinflammatory disorder first described in 2020, resulting from somatic mutations in the *UBA1* gene on the X chromosome. These mutations impair ubiquitin-activating enzyme function, driving a clonal, myeloid-restricted autoinflammatory state. Clinically, VEXAS is characterised by recurrent fevers, neutrophilic and vasculitic skin lesions, relapsing polychondritis, pulmonary infiltrates, venous thromboembolism and progressive cytopenias. A hallmark diagnostic feature is the presence of cytoplasmic vacuoles in myeloid and erythroid precursors. Haematological abnormalities are central to the disease presentation, and myelodysplastic syndromes are common. Given its broad multisystem presentation, VEXAS is frequently misdiagnosed as vasculitis, connective tissue disease, infection, or primary haematological pathology, often resulting in years of ineffective immunosuppression and delayed diagnosis. Mortality remains high, with approximately half of patients dying within 5 years of diagnosis. In South Africa (SA), access to advanced molecular diagnostics (including *UBA1* sequencing) remains limited, contributing to under-recognition of the condition. This case is notable in that, to the best of our knowledge, it represents the first reported SA case of VEXAS syndrome with molecular confirmation of a *UBA1* mutation.

Keywords: VEXAS syndrome, *UBA1*, myelodysplastic syndrome, autoinflammation, cutaneous vasculitis, South Africa

S Afr Med J 2026;116(9):e4691. https://doi.org/10.7196/SAMJ.2026.v116i9.4691

VEXAS (vacuoles, E1 enzyme, X-linked, autoinflammatory, somatic) syndrome is an adult-onset autoinflammatory disorder caused by somatic mutations in the *UBA1* gene on the X chromosome, which plays a central role in ubiquitylation. The *UBA1* gene encodes the E1 ubiquitin-activating enzyme, which initiates the ubiquitination pathway responsible for tagging proteins for degradation and cellular regulation. Mutations impair this process, leading to abnormal protein accumulation and activation of innate immune pathways that drive systemic inflammation.[1] These mutations lead to impaired protein homeostasis, clonal expansion of myeloid progenitors and a severe inflammatory phenotype that spans dermatological manifestations, bone marrow dysplasia with cytopenias and systemic inflammation.[2] The discovery of VEXAS unified several previously unrelated inflammatory and haematological conditions under a single genetic mechanism.[1]

Haematological abnormalities are prominent in VEXAS, with bone marrow examinations frequently demonstrating cytopenias and dysplasia. Approximately 50% of patients present with, or later develop, myelodysplastic syndromes (MDS).[2] MDS itself is a clonal haemopoietic stem cell disorder characterised by ineffective haematopoiesis leading to peripheral cytopenias and dysplasia in ≥1 cell lines.[3] In VEXAS-associated MDS, disease behaviour is often less aggressive than classic MDS, and may remain stable for prolonged periods despite significant inflammatory activity.[1]

Because VEXAS is newly recognised and has a wide and heterogeneous clinical presentation, clinician awareness remains limited, often resulting in delayed diagnosis. This is clinically significant, as VEXAS carries substantial morbidity and mortality, with up to half of affected patients dying within 5 years.[5] Our case highlights the importance of considering VEXAS syndrome in middle-aged male patients with MDS-like features, particularly when preceded by persistent systemic inflammation and dermatological manifestations.

Access to advanced molecular diagnostics such as *UBA1* testing remains limited in South Africa (SA), restricting timely recognition of rare autoinflammatory syndromes such as VEXAS. Greater clinician awareness and integration of molecular testing into diagnostic pathways are essential. As more local cases are identified, emerging data will help to clarify how VEXAS presents across diverse populations and in settings with high infectious and inflammatory burdens.

Ethics approval for publication of this case report was obtained from the University of the Witwatersrand Human Research Ethics Committee (Medical) (ref. no. M240463). Written informed consent was obtained from the patient for publication of this case report and any accompanying images.

Case presentation

The patient, a man in his 60s, had a background of ischaemic heart disease with prior coronary artery bypass grafting and coronary stenting. From 2018, he developed recurrent thrombotic events, including multiple deep-vein thromboses, despite therapeutic anticoagulation. These episodes were frequently accompanied by inflammatory skin changes involving the lower limbs and recurrent episodes of presumed cellulitis. He also experienced recurrent painful swelling and erythema of the external ear, clinically suggestive of auricular chondritis (Fig. 1).

Over the ensuing years, he developed escalating multisystem inflammatory episodes characterised by recurrent fevers, rash, pleuritic symptoms, migratory inflammatory arthralgia, jaw arthritis and recurrent auricular chondritis. Cutaneous examination during inflammatory flares revealed erythematous to violaceous, non-blanching palpable purpuric lesions involving the lower limbs, clinically consistent with cutaneous vasculitis (Fig. 2). A clinical diagnosis of systemic vasculitis with relapsing polychondritis was made, and he was treated with multiple immunosuppressive agents. Despite this, he continued to experience frequent steroid-responsive inflammatory flares.

During this period, he developed progressive multisystem involvement, including recurrent pneumonias, chronic sinus disease requiring surgical drainage, serositis and recurrent episodes of ocular inflammation. These ocular manifestations were characterised by periocular erythema, conjunctival injection and eyelid oedema during inflammatory flares (Fig. 3). He also required repeated hospital admissions FOR sepsis.

By 2023, he had developed worsening cytopenias. Bone marrow evaluation confirmed MDS with cytoplasmic vacuolation within myeloid and erythroid precursor cells, and he was commenced on erythropoietin therapy followed by azacitidine. Given the constellation of systemic inflammation, relapsing polychondritis and newly diagnosed MDS, VEXAS syndrome was suspected. Genetic testing for *UBA1* mutations was therefore performed on peripheral blood, with samples sent to Centogene (Cambridge, MA, USA) for next-generation sequencing. This identified a pathogenic somatic *UBA1* mutation, confirming the diagnosis of VEXAS syndrome.

In 2024, he continued to experience refractory inflammatory activity, recurrent episodes of sepsis and progression of squamous cell carcinoma of the scalp, accompanied by increasing frailty. Although he was evaluated and prepared for allogeneic stem cell transplantation for his MDS, aggressive recurrence of his squamous cell carcinoma ultimately precluded transplantation. His condition gradually deteriorated, and he was transitioned to palliative care. He passed away at home in May 2025.



Fig. 1. Clinical photograph demonstrating erythema and swelling of the external ear involving the cartilaginous portion, consistent with inflammatory auricular involvement.



Fig. 2. Clinical photograph demonstrating erythematous to violaceous, non-blanching palpable purpuric lesions involving the lower limbs.



Fig. 3. Clinical photograph demonstrating periocular erythema with conjunctival injection and eyelid oedema during an inflammatory flare.

Investigations

- Full blood count: macrocytic anaemia, lymphopenia and mild thrombocytopenia on all consecutive blood counts from 2022 to 2025
- Erythrocyte sedimentation rate and C-reactive protein: always mildly elevated from 2022 to 2025
- Bone marrow biopsy: bone marrow aspirate demonstrated prominent cytoplasmic vacuoles in myeloid and erythroid precursors (Fig. 4)
- Molecular analysis: molecular analysis of the *UBA1* gene confirmed the pathogenic variant c.122T>C p.(Met41Thr), (NM_003334.3:c.122T>C), first reported by Beck *et al*.[1] This substitution results in a methionine-to-threonine substitution at codon 41 within exon 3 (of 26). This substitution is one of the canonical Met41 variants described in VEXAS syndrome, known to impair ubiquitin-activating enzyme function and drive myeloid-restricted autoinflammation.[3]

Discussion

VEXAS syndrome is a recently described, adult-onset autoinflammatory disorder characterised by systemic inflammation, cytopenias and multi-organ involvement, typically affecting men >50 years of age owing to its X-linked association with somatic *UBA1* mutations.[1,2] Our patient's presentation illustrates the characteristic overlap between haematological, dermatological and rheumatological features, and the delay in diagnosis frequently described in international cohorts.

The *UBA1* p.Met41Thr (c.122T>C) variant identified in this case is a canonical mutation often associated with typical manifestations that include cytopenias, MDS overlap, cutaneous inflammation

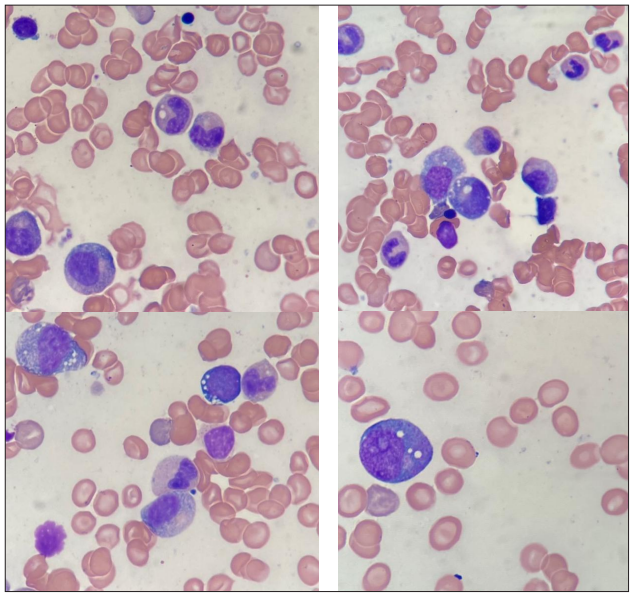

Fig. 4. Bone marrow aspirate demonstrating prominent cytoplasmic vacuolation within myeloid and erythroid precursor cells.

and thromboembolic disease.[1,4] The diagnostic hallmark remains cytoplasmic vacuoles in myeloid and erythroid precursors, originally reported in all patients in the first case series, although the underlying mechanism is still not fully understood.[1] Macrocytic anaemia and progressive cytopenias are common and often parallel, worsening systemic inflammation.[2]

Mutations affecting the methionine-41 (Met41) residue of the *UBA1* gene represent the most frequently reported pathogenic variants associated with VEXAS syndrome. Variants including p.Met41Thr, p.Met41Val and p.Met41Leu occur within a recognised mutational hotspot and have been described in multiple international cohorts since the initial description of the syndrome.[1,6] These variants impair cytoplasmic translation of the ubiquitin-activating enzyme E1, resulting in defective ubiquitination and activation of innate immune pathways that drive the systemic inflammatory phenotype characteristic of VEXAS syndrome.[1] The p.Met41Thr variant identified in our patient is one of these canonical mutations and has been reported in association with cytopenias and systemic inflammation, and in frequent overlap with MDS.[1,6]

Cutaneous involvement is one of the earliest and most frequent manifestations, reported in >80% of patients.[5] Presentations include neutrophilic dermatoses, leukocytoclastic vasculitis, urticaria-like lesions and relapsing polychondritis. Genotype-phenotype correlations have been noted: p.Met41Leu variants are more often associated with neutrophilic dermatoses, while p.Met41Val variants more frequently show vasculitic patterns.[4,5]

Given the high prevalence and early presentation of skin disease, clinicians should maintain a high index of suspicion for VEXAS in older male patients with neutrophilic dermatoses or vasculitic lesions, particularly when accompanied by cytopenias or systemic inflammation. Early *UBA1* genetic testing is crucial, as the identified variant may aid in prognostication and therapeutic decision-making.[5]

Because VEXAS is multisystemic, the clinical spectrum is broad and frequently misdiagnosed. Constitutional symptoms, pulmonary infiltrates, arthralgia, recurrent fevers and venous thromboembolism are common, as demonstrated in the large cohort (Table 1).[6] Steroids provide rapid symptom control in most patients, but relapse and toxicity are frequent, emphasising the need for steroid-sparing therapies.

Table 1. Clinical manifestations of *UBA1* variant carriers (VEXAS)*

Clinical domain	Specific manifestations reported
Haematological	Anaemia (universal) Macrocytosis Thrombocytopenia Leukopenia (variable) Elevated CRP/ESR Transfusion requirements
Bone marrow findings	Vacuoles in myeloid/erythroid precursors Megaloblastoid changes Dysmyelopoiesis MDS-like morphology
Dermatological	Neutrophilic dermatoses Vasculitic rash Erythematous plaques Sweet syndrome-like lesions Polychondritis-type inflammation Chronic refractory skin disease
Pulmonary	Pulmonary infiltrates Ground-glass opacities Interstitial pneumonitis Recurrent infections Airway inflammation Dyspnoea
Systemic/constitutional	Fevers Fatigue Weight loss Night sweats High inflammatory markers
Rheumatological/ musculoskeletal	Arthralgia/arthritis Myalgia Polychondritis-like features
Thrombotic	Deep-vein thrombosis Pulmonary embolism
Immunological diagnoses	Vasculitis Rheumatological conditions PMR Undifferentiated autoinflammatory disease Often underdiagnosed
Other	Ocular inflammation (episcleritis/ scleritis) Chronic infections Recurrent hospitalisations

CRP = C-reactive protein; ESR = erythrocyte sedimentation rate; MDS = myelodysplastic syndrome; EHR = electronic health record; PMR = polymyalgia rheumatica.
*Table constructed by the authors based on clinical manifestations described in Beck *et al.*[6]

Evidence to guide treatment remains limited. In the largest retrospective cohort to date, JAK inhibitors and IL-6 blockade showed the highest response rates, whereas IL-1 and TNF-α inhibitors demonstrated minimal benefit.[6] None of these agents significantly reduced *UBA1* clonal burden, highlighting the role of disease-modifying strategies in patients with MDS overlap.

Azacitidine is emerging as an important therapeutic option in VEXAS with associated MDS. Data from the French VEXAS registry and a subsequent phase II study showed clinical or haematological responses in ~70 - 78% of patients, including improved cytopenias, reduced inflammation and steroid-sparing effects.[7,8] This informed the decision to initiate azacitidine in our patient, aiming to control systemic inflammation and stabilise marrow function.

Allogeneic haematopoietic stem cell transplantation remains the only potentially curative therapy. Recent European Bone Marrow

Transplant data in 19 patients with VEXAS demonstrated encouraging molecular responses and sustained disease control, although treatment-related morbidity remained significant.[9] Given the constraints of the SA setting, early multidisciplinary evaluation and referral to transplant centres, locally or internationally, should be considered for appropriate candidates.

Teaching points

- VEXAS syndrome should be considered in middle-aged men presenting with unexplained systemic inflammation, cytopenias and relapsing polychondritis.
- VEXAS is often misdiagnosed and associated with high morbidity and mortality, making early identification and multidisciplinary management critical.
- Emerging therapies such as IL-6 blockade and JAK inhibitors may provide symptomatic benefit, while allogeneic stem-cell transplantation remains the only disease-modifying option in selected patients.
- In SA and the broader African context, VEXAS is likely to be substantially under-recognised owing to overlap with common regional conditions (HIV-related cytopenias, tuberculosis, nutritional deficiencies and autoimmune disease).
- Limited access to *UBA1* molecular testing and uneven specialist availability contribute to delays in diagnosis, emphasising the need to expand diagnostic capacity.
- Increased clinician awareness of marrow vacuolisation and its association with VEXAS is essential for earlier detection.
- Establishing national or regional registries is needed to define the prevalence, phenotype and outcomes of VEXAS across African populations and to improve access to evolving therapies.

Conclusion

This molecularly confirmed SA case illustrates the diagnostic importance of recognising VEXAS syndrome in patients with persistent systemic inflammation, characteristic cutaneous or chondral findings, thrombosis and unexplained cytopenias. Bone marrow vacuolation should prompt consideration of UBA1 testing, particularly when conventional immunosuppressive treatment has failed. Earlier diagnosis may allow timely multidisciplinary assessment and consideration of disease-modifying treatment, including transplantation in suitable patients. Improving access to molecular testing and documenting local cases will help define the burden and clinical spectrum of VEXAS in SA.

Data availability. N/a.

Declaration. None.

Acknowledgements. We are deeply grateful to the patient and his wife for their consent to publication and for their courage and generosity in allowing their experience to inform and educate others. Furthermore, the authors wish to acknowledge Wits Donald Gordon Medical Centre in enabling *UBA1* molecular testing to be performed in the USA, given the lack of local testing availability. We also want to thank Dr Nicole Holland from Lancet Laboratories for bone marrow imaging.

Author contributions. JD conceptualised the case report, collected and interpreted the clinical information, conducted the literature review and drafted the manuscript. JJ and CB assisted with the ethics application and critically revised the manuscript. LP provided dermatological assessment and interpretation of the cutaneous findings and critically revised the manuscript. JRdT supervised the case report, contributed to the patient's haematological management and interpretation of the clinical findings, and critically revised the manuscript. All authors reviewed and approved the final manuscript.

Funding. None.

Conflicts of interest. None.

AI contribution. Artificial intelligence (AI) tools were used for language editing and readability enhancement only. All scientific content, clinical interpretation and conclusions were generated and verified by the authors.

1. Beck DB, Ferrada MA, Sikora KA, et al. Somatic mutations in *UBA1* and severe adult-onset autoinflammatory disease. N Engl J Med 2020;383(27):2628-2638. https://doi.org/10.1056/NEJMoa2026834
2. Heiblig M, Patel B, Jamilloux Y. VEXAS syndrome, a new kid on the block of autoinflammatory diseases: A hematologist's point of view. Semin Arthritis Rheum 2023;59:152222. https://doi.org/10.1016/j.semarthrit.2023.152222
3. Cazzola M. Myelodysplastic syndromes. N Engl J Med 2020;383(14):1358-1374.
4. Tan IJ, Ferrada MA, Ahmad S, et al. Skin manifestations of VEXAS syndrome and associated genotypes. JAMA Dermatol 2024;160(4):385-395. https://doi.org/10.1001/jamadermatol.2024.1657
5. Al-Hakim A, Goldberg S, Gaillard S, Heiblig M, Beck DB, Savic S. Clinical features in VEXAS syndrome: A systematic review. Rheumatology 2025;64(10):5217-5229. https://doi.org/10.1093/rheumatology/keaf293
6. Beck DB, Bodian DL, Shah V, et al. Estimated prevalence and clinical manifestations of *UBA1* variants associated with VEXAS syndrome in a clinical population. JAMA 2023;329(4):318-324. https://doi.org/10.1001/jama.2022.24836
7. Gurnari C, Koster L, Baaij L, et al. Allogeneic haematopoietic cell transplantation for VEXAS syndrome: Results of a multicentre study of the EBMT. Blood Adv 2024;8(6):1444-1448. https://doi.org/10.1182/bloodadvances.2023012478
8. Comont T, Heiblig M, Rivière E, et al. Azacitidine for patients with Vacuoles, E1 enzyme, X-linked, Autoinflammatory, Somatic (VEXAS) syndrome and myelodysplastic syndrome: Data from the French VEXAS Registry. Br J Haematol 2022;196(5):969-974. https://doi.org/10.1111/bjh.17893
9. Hadjadj J, Nguyen Y, Mouloudj D, et al. Efficacy and safety of targeted therapies in VEXAS syndrome: Retrospective study from the FRENVEX cohort. Ann Rheum Dis 2024;83:1-10. https://doi.org/10.1136/ard-2024-225640

Received 7 January 2026; accepted 17 March 2026.