This open-access article is distributed under Creative Commons licence CC-BY-NC 4.0.

A retrospective review of the clinical, biochemical and radiological spectrum of adrenal incidentalomas at Tygerberg Academic Hospital, South Africa

M Hussain,[1] MB ChB, FCP (SA); **T Jalavu,**[2] MB ChB, MMed (Chem Path); **R Davis,**[3] MB ChB, FC Rad (Diag); **W Conradie,**[4] MMed (Surg), PhD (Surg); **M Conradie-Smit,**[1] FCP (SA), Cert Endocrinology Metabolism (SA)

[1] *Division of Endocrinology, Department of Medicine, Faculty of Medicine and Health Sciences, Stellenbosch University and Tygerberg Hospital, Cape Town, South Africa*
[2] *Division of Chemical Pathology, Department of Pathology, Faculty of Medicine and Health Sciences, Stellenbosch University and Tygerberg Hospital, Cape Town, South Africa*
[3] *Department of Medical Imaging and Radiodiagnosis, Division of Radiodiagnosis, Faculty of Medicine and Health Sciences, Stellenbosch University and Tygerberg Hospital, Cape Town, South Africa*
[4] *Breast and Endocrine Surgery Unit, Division of Surgery, Faculty of Medicine and Health Sciences, Stellenbosch University and Tygerberg Hospital, Cape Town, South Africa*

Corresponding author: *M Hussain (maleeha.h12@gmail.com)*

Background. An adrenal incidentaloma (AI) is a clinically unapparent adrenal mass >1 cm detected during imaging performed for reasons other than adrenal disease. The approach to AI is discussed extensively in international literature, but not specifically in resource-limited settings such as South Africa (SA).
Objective. To describe the clinical, biochemical and radiological spectrum of AIs at Tygerberg Hospital (TBH), Cape Town, SA.
Methods. This study was a retrospective descriptive review of all patients diagnosed with AI at TBH during the study period (1 January 2009 - 31 December 2023).
Results. Two hundred and ninety-five (295) patient records were screened for inclusion using the radiology and admission records. Those excluded were duplicate entries (*n*=50), patients not meeting criteria for AI (*n*=47) and diagnosis of AI with no further investigation (*n*=113), leaving 85 patients included. A computed tomography scan was the most frequently utilised imaging modality (*n*=54; 64%). Indications were abdominal pain (*n*=27; 32%), other gastrointestinal complaints (*n*=10; 12%), abdominal mass (*n*=7; 8%), trauma (*n*=3; 4%) or other (*n*=38; 45%). Non-functional tumours comprised 87% (*n*=74). Functional tumours included pheochromocytoma (PCC) (*n*=5; 45%), mild autonomous cortisol secretion (MACS) (*n*=3; 27%), primary hypercortisolaemia (*n*=2; 18%) and androgen-producing tumours (*n*=1; 9%). Fourteen patients (16%) had surgery.
Conclusion. Our study demonstrated that PCC and cortisol-producing adenomas were the most common functional tumours. This is in contrast to most international studies, which show MACS as the most common functional AI. This likely reflects regional screening bias and underutilisation of dexamethasone suppression testing, rather than the true disease prevalence of PCC in the Western Cape Province. A large proportion of patients with a diagnosis of AI did not undergo any further investigation. Awareness among clinicians and collaboration with radiologists for early identification and referral of AI cases is imperative.

Keywords: adrenal incidentaloma, clinical spectrum, biochemical evaluation, radiological features

S Afr Med J 2026;116(7):e4238. https://doi.org/10.7196/SAMJ.2026.v116i7.4238

An adrenal incidentaloma (AI) is defined as a clinically unapparent adrenal mass >1 cm detected during imaging performed for reasons other than suspected adrenal disease. By this strict definition, imaging is not performed due to clinical suspicion of adrenal dysfunction, and it excludes adrenal lesions discovered during the screening of patients with hereditary syndromes or extra-adrenal malignancies.[1] The mean age of diagnosis is 55 years.[2] The prevalence increases with age, ranging from 3% at age 50, to 10 - 15% in the fifth to seventh decade, and is rare in patients aged <40 years.[2-5] AI is more frequent in female patients as a result of the higher rate of abdominal diagnostic procedures performed in females.[1,6] There is an increased prevalence of AI in obese patients, as well as in patients with diabetes mellitus (DM) and hypertension.[7] The approach to AIs involves evaluating the function, both clinically and biochemically, as well as the risk of malignancy on imaging.[1,5] Although 70 - 75% of AIs are non-functional, every diagnosed patient should undergo a thorough history and clinical examination to determine hormone excess, primarily to rule out pheochromocytoma (PCC), hyperaldosteronism, hyperandrogenism and hypercortisolism.[1,6]

Screening for functionality includes a 1 mg overnight dexamethasone test for hypercortisolism, and plasma or urinary metanephrines and normetanephrines for PCC.[1] In patients with concurrent hypertension or unexplained hypokalaemia, the aldosterone/renin ratio should be evaluated to exclude primary aldosteronism.[1,7] For patients exhibiting clinical features of excess androgens or imaging characteristics of adrenocortical carcinoma (ACC), measuring sex steroids and steroidogenesis precursors is recommended.[1] Repeated hormonal testing in patients with a normal hormonal profile at initial evaluation is not recommended, unless new clinical signs of endocrine activity appear or there is worsening of comorbidities, such as hypertension or DM.[1]

If an adrenal mass appears lipid-rich on an adrenal protocol computed tomography (CT) scan, indicated by measuring <10 Hounsfield units (HU) and being homogeneous, no further imaging is recommended, as the mass is considered benign.[1] Approximately 70% of adrenal adenomas are lipid-rich and contain abundant intracytoplasmic fat, in contrast to most malignant lesions that lack intracellular lipid.[6] Radiological features of malignancy on CT scan include size >4 cm, heterogeneity, irregular contours, lymphadenopathy and invasion of surrounding structures.[6] Calcification and necrosis on CT scan are common in malignancy, but not specific.[3] The contrast in a benign lesion tends to wash out rapidly, while malignant lesions retain contrast for longer periods.[6] It is proposed that this occurs because of increased microvascularity and capillary permeability in malignant lesions, resulting in leakage of contrast into the extravascular space. The washout test during the adrenal protocol CT uses post-contrast attenuation values obtained at 60 seconds and 15 minutes after contrast administration. If an unenhanced scan was obtained, then an absolute percentage washout value (APW) is calculated. If no unenhanced scan is available, a relative percentage washout value (RPW) is calculated. An APW on a contrast scan >60% or RPW >40% is compatible with a benign adrenocortical adenoma. A lesion with an APW <60% or RPW <40% is indeterminate and warrants further diagnostic testing.[6,8]

Adrenalectomy is recommended for most functional AI, local symptoms, or lesions suggestive of malignancy. A minimally invasive surgical approach is the gold standard and is associated with less pain, shorter length of hospital stay, less blood loss and faster recovery.[9] Minimally invasive adrenalectomy can be performed with a transperitoneal or retroperitoneoscopic approach. Indications for open adrenalectomy include a size >6 - 10 cm, depending on surgical expertise and tumour anatomy. In adrenal malignancies such as ACC or a malignant PCC, the open approach is usually preferred owing to the risk of capsular injury, and is often associated with lymphadenopathy and invasion of local structures.[1,5]

For homogeneous adrenal lesions with between 11 and 20 HU and a tumour size <4 cm with no significant hormone excess upon investigation, immediate additional imaging or interval imaging in 12 months could be performed.[1] If the adrenal mass is ≥4 cm, heterogeneous or has an indeterminate washout, there is a higher risk of malignancy. Indeterminate cases should be discussed at a multidisciplinary team meeting, considering surgery or interval imaging at 6 - 12 months.[1] When interval imaging is performed, surgical resection is recommended if the mass enlarges by 20% in 6 - 12 months.[10]

The approach to AI is discussed extensively in international literature, but has not been specifically discussed in resource-limited settings such as South Africa (SA). However, a case report described the rare occurrence of adrenal leiomyoma as AI, with associated Epstein-Barr virus and HIV.[11] No SA studies to date describe the incidence and characteristics of AI. There is a need for locally driven data collection, informing clinicians of the differential diagnosis that might differ in our population, and the appropriateness of screening and follow-up. Limited resources as an obstacle to management should be considered. This study aimed to describe the clinical, biochemical and radiological spectrum of AIs at Tygerberg Hospital (TBH), Cape Town, SA, and to strengthen the local collaborative interdisciplinary approach to patients with AI.

Methods

A retrospective descriptive review was undertaken of all patients with a diagnosis of AI managed at TBH between 1 January 2009 and 31 December 2023. Ethical approval was obtained from the Stellenbosch University Human Research Ethics Committee (ref. no. S24/02/036), with a waiver of informed consent, as data were anonymised and retrospective. Clinical information on all patients with AI was retrieved from medical and radiological records. These records included the endocrinology admission and outpatient records, as well as the picture archiving and communication system (PACS). Inclusion criteria consisted of adrenal masses meeting the strict definition of an AI in adult patients (≥18 years). Patient exclusion criteria included AI not meeting criteria, duplicate entries and AI patients with no further investigations performed.

The diagnostic criteria and terminology for subclinical Cushing's shifted significantly throughout the study period. In 2009, the American Association of Clinical Endocrinology established a post-dexamethasone suppression cut-off value of >138, which yielded a high specificity of 100% and low sensitivity of 58%.[12] In 2016, a value between 51 and 138 nmol/L was termed 'possible autonomous cortisol secretion' and >138 'autonomous cortisol secretion.'[10] Current guidelines define 'mild autonomous cortisol secretion' using a value of >50 nmol/L.[1] To maintain internal validity and avoid misclassification, we stratified patients according to contemporaneous guidelines: a >138 nmol/L threshold was applied for the 2009 - 2022 cohort, while a >50 nmol/L threshold was used in 2023.

Demographic data, comorbidities, radiological characteristics, morphological assessment, biochemistry, functional assessment, outcomes, surgical indications, operation type and histological classification were recorded. Data analyses were conducted using SPSS version 2 (IBM, USA), with assistance from a statistician. Descriptive statistics were computed for all variables of interest. Univariate normality was determined for all quantitative variables. Demographic characteristics of the sample, as well as disease-related information, were calculated as means and standard deviations (SDs) for quantitative variables, and counts and associated percentages for categorical variables. For non-normally distributed variables, non-parametric analysis was applied.

Results

Two hundred ninety-five (295) patient records were included. Duplicate entries (n=50), patients not meeting AI criteria (n=47) (included imaging done for suspected adrenal dysfunction, screening of extra adrenal malignancy and hereditary syndromes associated with AI) and cases with no further investigations (n=113) were excluded, leaving a population of 85 in the study (Fig. 1).

The mean (SD) age was 56 (11.4) years. The majority of patients were female (n=62; 73%). Hypertension was present in 58 (68%) patients, and DM in 37 (44%) patients. The median body mass index (BMI) was 31.7 kg/m^2 (Table 1).

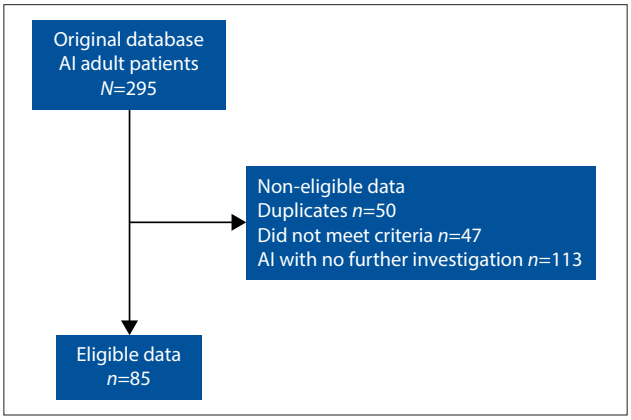

Fig. 1. Study participation flowchart. (AI = adrenal incidentaloma.)

The mode of initial imaging was an abdominal CT scan in most cases (*n*=54; 64%), followed by chest CT scan (*n*=17; 20%), abdominal ultrasound (*n*=7; 8%), other imaging, including nuclear medicine, specialised liver and kidney scans (*n*=7; 8%), and magnetic resonance imaging scan (1; 1%).

Unilateral lesions were identified in 74 (87%) patients, and bilateral lesions in 11 (13%). Morphological assessment of radiological features demonstrated adenomas that were lipid-poor (*n*=33; 39%), lipid-rich (*n*=48; 56%), indeterminate (*n*=7; 8%), possible PCC (*n*=4; 5%); and a possible malignancy in 1 (1%) patient. Malignancy was excluded in lipid-poor adenomas using radiological characteristics of size, absolute washout and repeat imaging. HUs were included in 76% of adrenal protocol and standard abdominal CT scan reports. One patient had unilateral hyperplasia, which is not an AI by strict definition, and another had bilateral macronodular hyperplasia. No patients had bilateral hyperplasia or unilateral macronodular hyperplasia.

Non-functional tumours comprised 87% (*n*=74) of the total, and functional 13% (*n*=11) (Table 2).

Surgery was performed in 14 (16%) patients, with indications for surgery including size >4 cm (*n*=10; 71%), hormonal excess (*n*=8; 57%), indeterminate mass (*n*=3; 21%) and radiological features of malignancy (*n*=1; 7%). Fourteen surgeries performed consisted of open adrenalectomy (*n*=4; 29%), laparoscopic transperitoneal adrenalectomy (*n*=8; 57%) and retroperitoneoscopic adrenalectomy (*n*=2; 14%). Histological evaluation showed adrenocortical adenoma (*n*=4; 29%) and PCC (*n*=4; 29%) (Table 3).

Regarding further follow-up of non-operated AIs, 43/71 (60%) patients underwent interval imaging or biochemistry, 21 (28%) were benign, non-functional and discharged, and 7 (10%) patients were lost to follow-up.

Discussion

To the best of our knowledge, this is the first review of AI in SA. The study revealed a predominance of female middle-aged patients and a majority of unilateral non-functioning adenomas, consistent with international studies. The most common functional tumour was PCC, both biochemically and histologically, followed by cortisol-producing tumours. PCC imaging characteristics include a heterogeneous appearance or an unenhanced CT density value of ≥10 HU (Fig. 2).[13]

Table 1. Characteristics of patients with adrenal incidentaloma at baseline (*N*=85)

Characteristic	*n* (%)*
Male	23 (27)
Female	62 (73)
Age, years, mean (SD)	85 (56.7; 11.4)
BMI, kg/m^2, median, IQR	64 (31.7; 26.1 - 39.2)
Hypertension	58 (68)
Diabetes mellitus	37 (44)
HbA1c, %, mean (SD)	36 (7.9; 1.86)

SD = standard deviation; IQR = interquartile range; BMI = body mass index.
*Unless otherwise indicated.

These unique radiological features combined with an increased use of radiological diagnostic imaging may prompt radiology to initiate a referral, and may suggest a cause of the increased prevalence in AI. Our study contrasts with most international studies, which have cortisol-producing tumours as the most common finding.[7] However, a retrospective study in Korea showed PCC as the most common functional AI, in keeping with studies showing a higher prevalence of PCC in Asian countries.[14,15]

The lower prevalence of MACS in this study may be due to a stricter diagnostic threshold (>138 nmol/L) for most of the study period (2009 - 2022). The transition to a more sensitive threshold (>50 nmol/L) occurred in the last year of the study (2023), likely leading to an underestimation of cases. Potential screening bias and the underutilisation of the 1 mg dexamethasone suppression test may have influenced these findings. As our study was conducted in a tertiary referral centre, physicians often give priority to rule out a PCC with urinary metanephrines to avoid the risk of a hypertensive crisis.

There is an increasing trend for PCC to be discovered incidentally, with rates as high as 40%.[13,16] When detected incidentally, a study showed a larger mean tumour diameter of 60 mm. However, some studies showed a smaller size of PCC compared with tumours detected due to adrenergic symptoms, which were associated with lower metanephrine results.[13,16,17] The mean size of PCC in our study was 33 mm, which was in the smaller range. Incidental PCC has been associated with older patients.[13,16] In our study, the mean age of patients with PCC was 50 years. Of the 5 biochemically suspected PCC, 4 were confirmed histologically. The fifth patient presented with an AI and a concomitant histologically confirmed extra adrenal paraganglioma, which accounted for the elevated metanephrines. It is important to note that elevated metanephrines are not always diagnostic of a PCC, as pre-analytical factors such as an upright posture prior to testing, physiological stress and drugs can cause false positive elevations.[18] It is possible that when an AI was detected on a CT scan and demonstrated imaging features suspicious for PCC (Fig. 2), patients were more likely to be referred for functional assessment. This may have contributed to the higher rate of PCC observed in our cohort.

All patients with cortisol excess (overt and subclinical) in the study were female. This is in line with the literature, indicating that hypercortisolism has a higher prevalence in women.[15] The mean BMI of patients with overt hypercortisolaemia was 43 kg/m^2, compared with 32 kg/m^2 in patients with MACS. Overt and mild autonomous cortisol excess are associated with a higher incidence of coexisting conditions such as hypertension, obesity, type 2 DM and dyslipidaemia.[10] Regarding patients with overt Cushing's syndrome, one underwent open adrenalectomy for a size >4 cm, and one had a retroperitoneoscopic adrenalectomy. Histopathological analysis demonstrated primary adrenal cortical adenoma and primary pigmented nodular adrenocortical disease, respectively. MACS was demonstrated in three patients. One patient underwent open adrenalectomy for ACC. The remainder did not have surgery, and their radiological characteristics were reported as bilateral macronodular

Table 2. Hypertension, diabetes and BMI by functional status (*N*=85)

Morbidity	Functional, *n*=11, *n* (%)*	Non-functional, *n*=74, *n* (%)*	*p*-value
Hypertension	9 (82)	49 (66)	0.49
Diabetes	3 (27)	34 (46)	0.33
BMI, kg/m^2, median (IQR)	31 (25 - 40)	32 (26 - 40)	0.53

BMI = body mass index; IQR = interquartile range.
*Unless otherwise indicated.

Table 3. Biochemical function and confirmed histology of AI

AI characteristic	*n* (%)
Biochemistry (*n*=11)	
PCC	5 (45)
Mild autonomous cortisol secretion	3 (27)
Overt hypercortisolaemia	2 (18)
Androgen producing	1 (9)
Histologically confirmed (*n*=14)	
Adrenocortical adenoma	4 (29)
PCC	4 (29)
Myelolipoma	1 (7)
ACC	1 (7)
Endothelial cyst	1 (7)
Leiomyoma	1 (7)
Haemorrhagic adrenal pseudocyst	1 (7)
Primary pigmented nodular adrenocortical disease	1 (7)

AI = adrenal incidentaloma; PCC = pheochromocytoma; ACC = adrenocortical carcinoma.

hyperplasia (Fig. 3) and bilateral adenomas, respectively (though no histological confirmation).

ACC was rarely detected as AI, and found in a single female patient who presented with recurrent pulmonary emboli and hirsutism (Fig. 4).[19] Biochemistry revealed glucocorticoid and androgen excess. This is in keeping with international studies, which show a low prevalence of ACC in 0.4 - 4% of AI, and a female predominance.[1,7,8] Locally, a case series published in 1985 described five patients with ACC seen over 10 years.[20] The presentation was heterogeneous, with three patients presenting with Cushing's syndrome and two with no features of hormonal excess. One patient presented with an abdominal mass, and the other was found to have a large non-functioning ACC with liver metastases found at laparotomy for intractable abdominal pain.[20]

Our study included no patients with primary aldosteronism. In the context of AI, patients would undergo biochemical evaluation for primary aldosteronism, in which hypertension (with or without hypokalaemia) or hypokalaemia is present. Part of the exclusion criteria of AI is imaging due to suspected hormonal excess. Primary aldosteronism is unlikely to present without a clinical or laboratory finding, i.e. hypertension with or without hypokalaemia.[21] In our study, 13% (*n*=12) of patients had renin/aldosterone levels performed without the presence of hypertension or hypokalaemia. This may be due to lack of awareness of AI recommendations. A majority of 80% (*n*=46) of patients with hypertension underwent renin/aldosterone testing. Recently, primary aldosteronism has been characterised as a spectrum, ranging from an unrecognised milder severity without hypertension, to severe clinically apparent primary aldosteronism with hypertension and hypokalaemia. The more severe and prolonged the exposure to renin-independent aldosterone production and a sodium-retention state, the higher the risk of severe hypertension and hypokalaemia.[22]

The most significant finding in this study was that many patients (*n*=113) with AI underwent no further diagnostic work-up. This may be a result of clinicians being unfamiliar with the guidelines, or influenced by the radiology report.[23] Most patients had an abdominal indication for imaging, and treating clinicians may have been preoccupied with the patient's acute presentation (Fig. 5). A study at a tertiary hospital in the UK revealed a low investigation rate of AI, attributed to scans being ordered by non-physicians.[24] Although the majority of AIs are benign, they still require functional evaluation.[1,7,24] Guidelines recommend that all

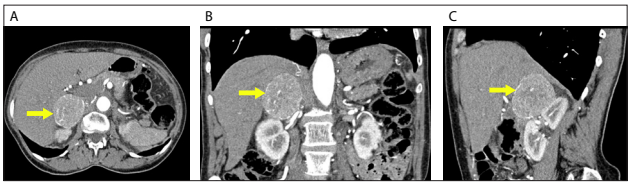

Fig. 2. Arterial phase computed tomography abdomen demonstrating an avidly enhancing, well-circumscribed mass (yellow arrow) in the right adrenal gland in A: axial, B: coronal, and C: sagittal planes. The mass exceeds 4 cm in maximal dimension. Histologically confirmed phaeochromocytoma.

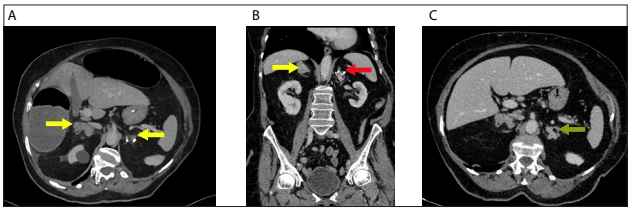

Fig. 3. Portal venous phase computed tomography abdomen demonstrating bilateral multinodular enlargement (A and B) of the adrenal glands (yellow arrows), with B: calcification (red arrow) and C: macroscopic fat (green arrow) in the left adrenal gland.

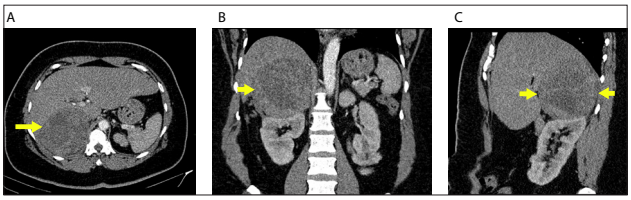

Fig. 4. Arterial phase CT abdomen demonstrating a large, well-circumscribed heterogeneous mass (yellow arrow) in the right adrenal gland in A: axial, B: coronal and C: sagittal planes. The mass exceeds 4 cm in maximal dimension. Histologically confirmed adrenal carcinoma.[19]

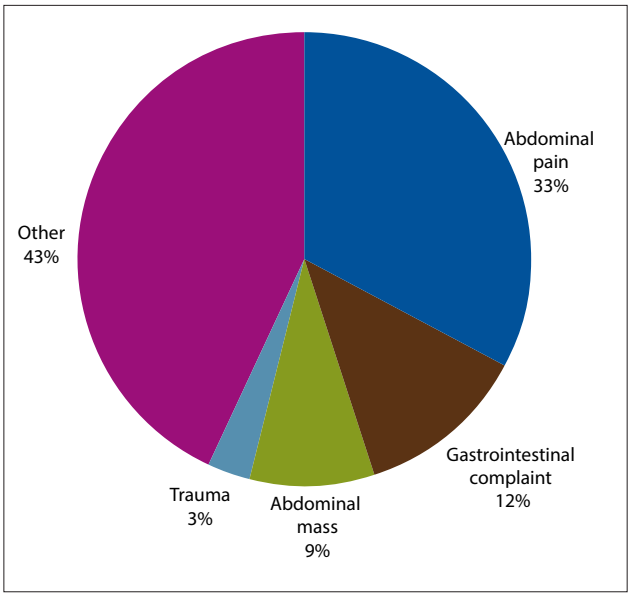

Fig. 5. Indications for imaging. Other = respiratory, vascular, urological, surgical and haematological indications.

AIs undergo careful evaluation for hormonal excess. Evaluation includes a 1 mg dexamethasone suppression test to exclude cortisol excess, urinary fractionated or plasma metanephrines to exclude PCC if HU is >10, and a renin/aldosterone ratio to exclude

aldosterone excess only if there is hypertension or hypokalaemia.[1] Evaluation for malignancy includes additional imaging if HU is >10 and the washout is indeterminate.[1]

There is emerging evidence showing an increased prevalence of metabolic syndrome in non-functioning AI,[25] with a twofold increase in prevalence of diabetes compared with individuals without AI.[26] The prevalence of diabetes was 27% in functional and 46% in non-functional AI, which were both higher than the average population prevalence of 7.2%.[27] There were no differences in the prevalences of hypertension, diabetes and BMI in patients with functional and non-functional adenoma (Table 2).

Radiological reporting may contribute to the large number of AIs without further work-up. Terminology used in radiology has significantly influenced referral rates of AIs.[24] A retrospective review revealed that none of the adrenal nodules reported as benign had any follow-up, and that a radiological report recommending follow-up was associated with a five times higher outpatient referral rate.[23] Investigations of adrenal nodules are more likely to occur if the report includes the HU, mass size and diagnostic recommendation, and when the findings are repeated in the report's conclusion.[28] Other factors that have been shown to increase follow-up include recommendations to refer to endocrinology in the radiology report, and whether the scan was ordered in an outpatient setting compared with an emergency setting.[28] A standardised and consistent way of reporting has to be promoted to increase the rate of further evaluation of AI.[28] An electronic medical record tool that utilises an algorithm giving specific advice on biochemistry and radiological follow-up has been shown to improve rates of hormonal testing and radiological follow-up.[29]

Fourteen patients in our cohort underwent surgery. Most (57%) underwent minimally invasive adrenalectomy, in keeping with international guidelines.[1] Indications for open surgery included local invasion of structures, and tumour size, performed for PCC (n=2), adrenal adenoma (n=1) and ACC (n=1). The rate of open adrenalectomy for PCC was 50%. Local retrospective studies have shown similar rates in Cape Town, at 45%, and in KwaZulu-Natal Province, at 54%.[30,31] Retroperitoneoscopic adrenalectomy was performed in one of our patients with a PCC.[32] The value of a multidisciplinary approach was demonstrated when the patient was appropriately referred.

Study limitations

The study has several limitations. It was a single-centre, retrospective study with a small number of patients. Missing data for BMI in 22 patients within the non-functional AI subgroup may impact the analysis of metabolic correlations. During the study period, changes to the European Society of Endocrinology clinical practice guidelines occurred in 2016 and 2023. Our findings may be subject to underreporting owing to evolving diagnostic criteria. The use of a >138 nmol/L cutoff from 2009 to 2022 likely excluded patients with MACS who would meet the current >50 nmol/L criteria. The study was conducted in a tertiary hospital, which may have caused a screening bias resulting from focus on excluding PCC to avoid hypertensive crises, and an underutilisation of the dexamethasone suppression test for incidentaloma workup.

Conclusion

This study contributes to our knowledge about this important clinical problem. In conclusion, we demonstrated that PCC and cortisol-producing adenomas were the most common functional tumours. This is in contrast to the findings of most international studies, which show MACS as the most common functional AI.[1] This likely reflects regional screening bias and underutilisation of dexamethasone suppression testing, rather than the true disease prevalence of PCC in the Western Cape Province.

A large proportion of patients with AI did not undergo further biochemical or radiological work-up, contrary to international recommendations. Awareness among clinicians must be improved regarding the identification and management of AI. AIs are often suboptimally reported radiologically. Standardised radiology reports may improve the clinical and biochemical evaluation of AIs. We suggest that radiologists in SA should recommend further evaluation of AI, as well as referral to endocrinology, in their reports.

Data availability. The data used for this study are not publicly available due to privacy and ethics restrictions, but are available from the corresponding author on reasonable request with institutional approval.

Declaration. The research for this study was done in fulfillment of the requirements for MH's MPhil degree at Stellenbosch University.

Acknowledgements. The authors would like to thank Mr Carl Lombard for the statistical analysis.

Author contributions. MH, MCS and IC conceptualised the study. MH conducted the data collection. MCS, IC, TJ and RD supervised the manuscript. All authors contributed to the final manuscript.

Funding. None.

Conflicts of interest. None.

1. Fassnacht M, Tsagarakis S, Terzolo M, et al. European Society of Endocrinology clinical practice guidelines on the management of adrenal incidentalomas, in collaboration with the European Network for the Study of Adrenal Tumors. Eur J Endocrinol 2023 ;189(1):1-42. https://doi.org/10.1093/ejendo/lvad066
2. Barzon L, Sonino N, Fallo F, Palu G, Boscaro M. Prevalence and natural history of adrenal incidentalomas. Eur J Endocrinol 2003;149(4):273-285. https://doi.org/10.1530/eje.0.1490273
3. Mansmann G, Lau J, Balk E, Rothberg M, Miyachi Y, Bornstein SR. The clinically inapparent adrenal mass: Update in diagnosis and management. Endocr Rev 2004;25(2):309-340. https://doi.org/10.1210/er.2002-0031
4. Arnaldi G, Boscaro M. Adrenal incidentaloma. Best Pract Res Clin Endocrinol Metab 2012;26(4):405-419. https://doi.org/10.1016/j.beem.2011.12.006
5. Sherlock M, Scarsbrook A, Abbas A, et al. Adrenal incidentaloma. Endocr Rev 2020;41(6):775-820. https://doi.org/10.1210/endrev/bnaa008
6. Naidu V, Singh B. Adrenal lesions encountered in current medical practice – a review of their radiological imaging. SA J Radiol 2013;17(4):128. https://doi.org/10.7196/sajr.914
7. Terzolo M, Stigliano A, Chiodini I, et al. AME position statement on adrenal incidentaloma. Eur J Endocrinol 2011;164(6):851-870. https://doi.org/10.1530/eje-10-1147
8. Allolio B, Fassnacht M. Clinical review: Adrenocortical carcinoma: Clinical update. J Clin Endocrinol Metab 2006;91(6):2027-2037. https://doi.org/10.1210/jc.2005-2639
9. Thompson G, Grant C, van Heerden J, et al. Laparoscopic versus open posterior adrenalectomy: A case-control study of 100 patients. Surgery 1997;122(6):1132-1136. https://doi.org/10.1016/s0039-6060(97)90218-x
10. Fassnacht M, Arlt W, Bancos I, et al. Management of adrenal incidentalomas: European Society of Endocrinology Clinical Practice Guideline in collaboration with the European Network for the Study of Adrenal Tumors. Eur J Endocrinol 2016;175(2):1-34. https://doi.org/10.1530/eje-16-0467
11. Alteer M, Ascott B, Conradie M. Leiomyoma: A rare cause of adrenal incidentaloma. JEMDSA 2013;18(1):71-74. https://doi.org/10.1080/22201009.2013.10872308
12. Zeiger MA, Thompson GB, Duh QY, et al. American Association of Clinical Endocrinologists and American Association of Endocrine Surgeons medical guidelines for the management of adrenal incidentalomas. Endocr Pract 2009;15(Suppl 1):S1-S35. https://doi.org/10.4158/ep.15.s1
13. Aggarwal S, Prete A, Chortis V, et al. Pheochromocytomas most commonly present as adrenal incidentalomas: A large tertiary center experience. J Clin Endocrinol Metab 2023;109(1):389-396. https://doi.org/10.1210/clinem/dgad401
14. Kim J, Bae K, Choi Y, et al. Clinical characteristics for 348 patients with adrenal incidentaloma. Endocrinol Metab 2013 ;28(1):20-25. https://doi.org/10.3803/enm.2013.28.1.20
15. Sconfienza E, Tetti M, Forestiero V, Veglio F, Mulatero P, Monticone S. Prevalence of functioning adrenal incidentalomas: A systematic review and meta-analysis. J Clin Endocrinol Metab 2023;108(7):1813-1823. https://doi.org/10.1210/clinem/dgad044
16. Guerrero M, Schreinemakers J, Vriens M, et al. Clinical spectrum of pheochromocytoma. J Am Coll Surg 2009;209(6):727-732. https://doi.org/10.1016/j.jamcollsurg.2009.09.022
17. Kopetschke R, Slisko M, Kilisli A, et al. Frequent incidental discovery of phaeochromocytoma: Data from a German cohort of 201 phaeochromocytoma. Eur J Endocrinol 2009;161(2):355-361. https://doi.org/10.1530/eje-09-0384
18. Lenders JW, Duh QY, Eisenhofer G, et al. Pheochromocytoma and paraganglioma: An Endocrine Society clinical practice guideline. J Clin Endocrinol Metab 2014;99(6):1915-1942. https://doi.org/10.1210/jc.2014-1498
19. Davids A, Kruger E, Zemlin A, Conradie-Smit, M. Adrenocortical carcinoma in a patient presenting with recurrent pulmonary emboli. JEMDSA 2025;30(1):21-25. https://doi.org/10.1080/16089677.2025.2477895
20. Palte S, Pillans P. Adrenal carcinoma. A case report. S Afr Med J 1985;67(25):1021-1022.
21. Stavropoulos K, Imprialos KP, Katsiki N, et al. Primary aldosteronism in patients with adrenal incidentaloma: Is screening appropriate for everyone? J Clin Hypertens 2018;20(5):942-948. https://doi.org/10.1111/jch.13291
22. Vaidya A, Carey R. Evolution of the primary aldosteronism syndrome: Updating the approach. J Clin Endocrinol Metab 2020;105(12):3771-3783. https://doi.org/10.1210/clinem/dgaa606

23. Watari J, Vekaria S, Lin Y, et al. Radiology report language positively influences adrenal incidentaloma guideline adherence. Am J Surg 2022; 223(2):231-236. https://doi.org/10.1016/j.amjsurg.2021.06.015
24. Feeney T, Madiedo A, Knapp PE, Gupta A, McAneny D, Drake FT. Incidental adrenal masses: Adherence to guidelines and methods to improve initial follow-up: A systematic review. J Surg Res 2022;269:18-27. https://doi.org/10.1016/j.jss.2021.07.041
25. Li X, Lan H, Lin X, et al. Metabolic complications and clinical outcomes of non-functioning adrenal incidentalomas: A systematic review and meta-analysis. BMC Endocr Disord 2025;25:92. https://doi.org/10.1186/s12902-025-01923-2
26. Lopez D, Luque-Fernandez MA, Steele A, Adler GK, Turchin A, Vaidya A. 'Nonfunctional' adrenal tumors and the risk for incident diabetes and cardiovascular outcomes: A cohort study. Ann Intern Med 2016;165(8):533-542. https://doi.org/10.7326/M16-0547
27. International Diabetes Federation. IDF Diabetes Atlas, 11th ed. Brussels: IDF, 2025. https://diabetesatlas.org (accessed 10 February 2026).
28. De Haan R, Schreuder M, Pons E, Visser J. Adrenal incidentaloma and adherence to international guidelines for workup based on a retrospective review of the type of language used in the radiology report. J Am Coll Radiol 2019;16(1):50-55. https://doi.org/10.1016/j.jacr.2018.08.011
29. Eldeiry LS, Alfisher MM, Callahan CF, Hanna NN, Garber JR. The impact of an adrenal incidentaloma algorithm on the evaluation of adrenal nodules. J Clin Transl Endocrinol 2018;13:39-45. https://doi.org/10.1016/j.jcte.2018.07.001
30. Nel D, Panieri E, Malherbe F, Steyn R, Cairncross L. Surgery for pheochromocytoma: A single-center review of 60 cases from South Africa. World J Surg 2020;44(6):1918-1924. https://doi.org/10.1007/s00268-020-05420-6
31. Zorgani A, Pirie F, Motala A. Characteristics and outcome of patients with pheochromocytoma at a tertiary endocrinology clinic in Durban, South Africa over 14 years. JEMDSA 2018;23(2):52-58. https://doi.org/10.1080/16089677.2018.1446592
32. Conradie W, Conradie M, Geldenhuys E, Edge J, Coetzee A, Lambrechts A. Retroperitoneoscopic adrenalectomy – introducing a new surgical technique in South Africa. S Afr J Surg 2023;61(1):1-6. https://doi.org/10.36303/sajs.3836

Received 21 October 2025; accepted 12 January 2026.