S Afr J Surg. 2026;64:226-228. Online first
https://doi.org/10.36303/SAJS.04148

Open Access article distributed under the terms of the Creative Commons Attribution-Non-Commercial Works 4.0 South Africa License (CC BY NC)
https://creativecommons.org/licenses/by-nc/4.0/

S Afr J Surg
ISSN: 0038-2361 eISSN: 2078-5151
© 2026 The Author(s)
CASE REPORT

Gastroduodenal intussusception in an adult: a rare case of a bleeding gastrointestinal stromal tumour with biliary dilatation

M Morar,[1] A Abd Elrahman[2,3,4]

[1] *Department of Surgery, School of Clinical Medicine, Faculty of Health Sciences, University of the Witwatersrand, South Africa*
[2] *Department of Surgery, Medical City for Military and Security Services, Oman*
[3] *Department of Surgery, Klerksdorp Tshepong Hospital Complex, South Africa*
[4] *Department of Surgery, School of Clinical Medicine, Faculty of Health Sciences, University of the Witwatersrand, South Africa*

Corresponding author, email: *morarmeera@gmail.com*

Summary
Gastroduodenal intussusception in adults is a rare entity with gastric gastrointestinal stromal tumours being the most common aetiology of this presentation. This case is the first reported in South Africa. Clinical manifestations can be in the form of upper gastrointestinal bleeding, gastric outlet obstruction, obstructive jaundice and pancreatitis. The case highlights the importance of a high-quality endoscopy and the potentially life-threatening consequences of missed or misinterpreted pathology. In the common presentation of upper gastrointestinal bleeding, clinicians should be familiar with appropriate diagnostic algorithms and be wary of attributing massive bleeding to minor endoscopic findings without further investigation.
Keywords: gastroduodenal intussusception, gastrointestinal stromal tumour, biliary dilatation, massive gastrointestinal bleed

Case report

A 34-year-old male patient with a history of peptic ulcer disease presented with features of an upper gastrointestinal bleed (UGIB) based on a history of melaena and symptomatic anaemia. On examination, he was tachycardic with a heart rate of 130 beats/minute, had significant pallor, and an ejection systolic flow murmur; however, no melaena stools were present on rectal examination. Laboratory investigations revealed severe iron-deficiency anaemia with a haemoglobin of 3.3 g/dL (13.4–17.5) requiring transfusion of 5 units of packed red blood cells. Gastroscopy revealed mild gastritis along the greater curvature of the stomach with no active bleeding source identified. The patient was discharged after haemoglobin normalisation without further investigation and prescribed proton pump inhibitors, haematinics and *Helicobacter pylori* eradication therapy. He was followed up for one year and labelled with a diagnosis of "gastritis" despite the absence of clear risk factors, with repeated prescriptions of proton pump inhibitors.

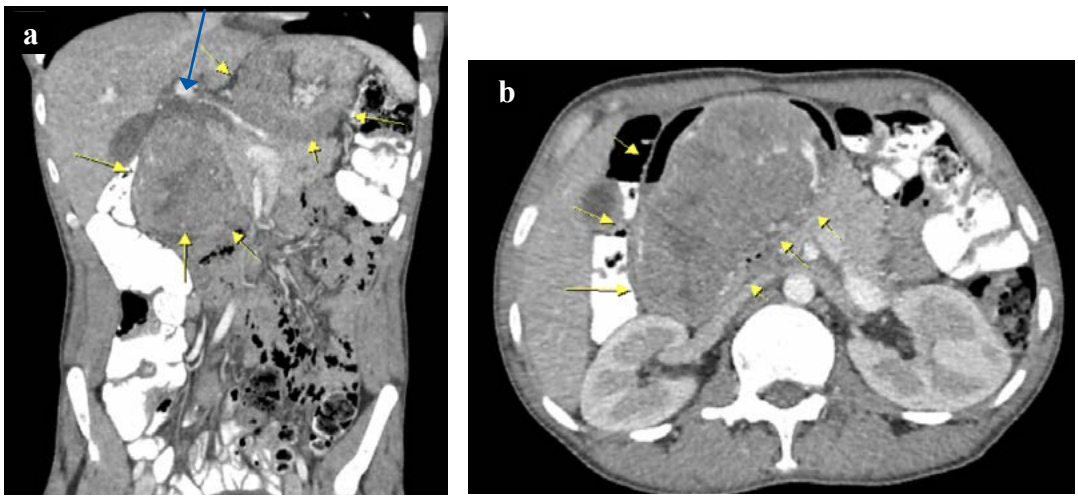

Figure 1: (1a) Coronal view of large gastric tumour projecting into the duodenum (yellow arrows) causing biliary dilatation (blue arrow). (1b) Axial view of the tumour protruding into the duodenum (yellow arrows) compressing porta hepatis

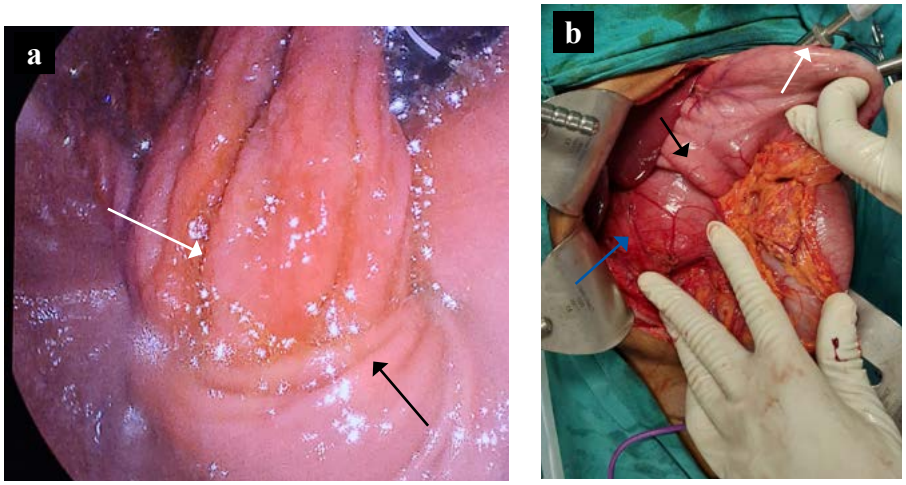

Figure 2: (2a) Endoscopic image of gastroduodenal intussusception; fundus of the stomach (white arrow) intussuscepting through the pylorus (black arrow). (2b) Intraoperative image of the fundal GIST intussuscepting into the duodenum (blue arrow), the pyloric area (black arrow) and the suction tip going through the invaginated fundus of the stomach (white arrow)

Eighteen months after the index presentation, he re-presented with severe symptomatic microcytic anaemia (haemoglobin 2.6 g/dL) and a 6 cm epigastric mass. He was not clinically or biochemically jaundiced and had normal liver function tests. Contrast-enhanced computed tomography (CT) demonstrated an exophytic intraluminal mass arising from the pylorus and extending into the duodenum, causing local mass effect and compression of the porta hepatis and pancreatic head with resultant biliary, intrahepatic and pancreatic duct dilatation (Figure 1). The differential at this stage was an intraluminal gastrointestinal stromal tumour (GIST), gastric adenocarcinoma or lymphoma based on the radiographic evidence.

Repeat gastroscopy demonstrated gastroduodenal intussusception, with the gastric fundus telescoping through the pylorus. The attached mass had telescoped within the duodenum and could not be accessed endoscopically (Figure 2a). Intraoperatively, the mass was milked out of the duodenum and a wedge resection was performed (Figure 2b). The patient had an uncomplicated postoperative course and was discharged. The mitotic rate was approximately 1 per 10 high-power fields (HPF), with no tumour necrosis and mild-to-moderate nuclear pleomorphism. Immunohistochemistry was strongly positive for CD117, DOG1 and CD34. The tumour measured 110 mm in maximal diameter and was classified as intermediate risk. As the neoplasm was completely resected and the tumour showed no imatinib-sensitive mutations, no further oncological treatment was offered. The patient is back to baseline activities and undergoing surveillance at the surgical outpatient department.

Discussion

Gastroduodenal intussusception in adults is rare, with gastric GISTs representing the most reported underlying cause worldwide. In the South African setting, it is important to consider lymphoma as a differential.[1] There are fewer than 30 globally reported cases of a GIST as a cause of this rare pathology with this case being the first reported from South Africa.[2] Even more rare is this pathology being a cause for biliary duct and pancreatic duct dilatation via ampullary compression. This case report serves to bring attention to a rare cause of obstructive jaundice, pancreatitis and gastric outlet obstruction that could be the consequences of this pathological process. It highlights the necessity of further investigation in the form of imaging or endoscopy in patients without a convincing aetiology in these conditions. An interesting aspect in this case is the absence of recognition of the GIST in the index oesophagogastroduodenoscopy (OGD). Given the low mitotic index, published data suggest that such tumours may exhibit slow growth kinetics, often progressing only a few millimetres per year and evolving over many years.[3,4] It can be assumed that this GIST was present on the initial endoscopy which leaves two options; either the endoscopy was inadequately performed for the tumour to have been missed or the tumour was not visible as it had telescoped into the pylorus and this was misinterpreted as gastritis. Failure to recognise or correctly interpret pathology at endoscopy may result in delayed diagnosis and potentially life-threatening complications, as illustrated in this case. Therefore, OGD should be performed by endoscopically trained personnel or under the supervision of a doctor with formal training which can be a challenge in the South African setting with limited resources and specialist availability. An option to address this shortfall is to prioritise the training of junior doctors with formal endoscopy courses or a period of supervised procedures under an experienced practitioner.

Another important aspect was the poor correlation between the clinical severity and endoscopic findings. In practice, it is common to label a patient with a specific diagnosis without interrogation thereof in subsequent visits, i.e. gastritis, gastro-oesophageal reflux disease, hiatus hernia to name a few. These patients are subjected to a lifetime of unnecessary chronic medication and follow-up visits and, most importantly, of new worrisome symptoms incorrectly being attributed to this misdiagnosis. Gastritis as a cause does not explain a significant drop in haemoglobin. The differential in this case was either an UGIB with an obscure cause or a small bowel bleed. In stable patients with ongoing bleeding and no identifiable upper gastrointestinal source, further evaluation should follow established algorithms, including repeat endoscopy by an experienced endoscopist, colonoscopy to exclude brisk lower gastrointestinal bleeding, CT angiography, and small bowel evaluation using capsule endoscopy or deep enteroscopy.[5-7]

Contrast-enhanced CT is the first-line imaging choice to characterise the mass to aid in the diagnosis of a GIST and evaluate the extent of disease as the initial staging. A tissue diagnosis is not mandatory if imaging and endoscopic features are typical of a GIST, the tumour is resectable and neoadjuvant therapy is not required. A biopsy does not change the management of the patient that will proceed directly to resection; however, in cases where the tumour is unresectable, has atypical imaging features or there is evident metastatic disease, a biopsy is required to confirm diagnosis and guide neoadjuvant treatment. A tissue diagnosis is challenging in a GIST as it is a submucosal lesion requiring stacked biopsies and there is a risk of bleeding and rupture.[8]

Surgery is the primary treatment of choice in resectable GIST lesions. There are a few reports of small GISTs being treated successfully with endoscopic submucosal resection as an alternative especially in elderly patients. Intraoperative principles include complete resection of the macroscopic tumour with an intact tumour capsule. As the tumours are fragile in nature, they should be handled with care to avoid tumour rupture. Segmented or wedge resection is usually adequate to achieve negative margins. Given the low incidence of nodal metastases, lymphadenectomy is not required but resection of the pathological enlarged lymph nodes can be considered in certain cases. Re-resection is not indicated for pathology showing a microscopically positive margin.[8] Laparoscopy can be considered in favourable anatomical locations such as anterior gastric wall, jejunum and ileum with a meta-analysis showing no difference in long-term outcomes but less blood loss, lower complication rates and shorter hospital stays in the laparoscopic cases.[9]

This case highlights a rare but clinically significant cause of upper gastrointestinal bleeding and biliary obstruction. It underscores the importance of adequate endoscopic training, careful clinical-endoscopic correlation, and appropriate escalation of investigations when findings are incongruent. In the South African setting of limited resources and specialist availability, structured training and supervision in endoscopy are essential to prevent avoidable morbidity. Knowledge of the appropriate diagnostic pathways for upper gastrointestinal bleeding in the setting of a normal gastroscopy is critical and may be life-saving.

Conflict of interest

The authors declare no conflict of interest.

Funding source

No funding was required.

Ethical approval

Ethical clearance approved unconditionally by Human Research Ethics Committee (Medical) of the University of the Witwatersrand. Ethics clearance certificate number M250763.

ORCID

M Morar https://orcid.org/0000-0002-7791-3751
A Abd Elrahman https://orcid.org/0000-0002-9297-7120

REFERENCES

1. Wagh AN, Ganesan B, Jawale HM, Mishra RA, Bhatt R. A rare case report of large B cell lymphoma in adult presentation as intussusception. Clin Pract. 2020;10(4):1292. https://doi.org/10.4081/cp.2020.1292.
2. Hsieh YL, Hsu WH, Lee CC, et al. Gastroduodenal intussusception caused by gastric gastrointestinal stromal tumour: A case report and review of the literature. World J Clin Cases. 2021;9(4):838-46. https://doi.org/10.12998/wjcc.v9.i4.838.
3. Jeon HK, Kim GH. Natural history of gastric subepithelial tumours: Long-term outcomes and surveillance strategies. J Clin Med. 2025;14(18):6354. https://doi.org/10.3390/jcm14186354.
4. Kim JY, Kang SJ. Natural course of gastric subepithelial tumours. Korean J Helicobacter Up Gastrointest Res. 2025;25(3):224-33.https://doi.org/10.7704/kjhugr.2025.0039.
5. Gerson LB, Fidler JL, Cave DR, Leighton JA. ACG clinical guideline: Diagnosis and management of small bowel bleeding. Am J Gastroenterol. 2015;110(9):1265-87. https://doi.org/10.1038/ajg.2015.246.
6. Gralnek IM, Stanley AJ, Morris AJ, et al. Endoscopic diagnosis and management of nonvariceal upper gastrointestinal haemorrhage (NVUGIH): European Society of Gastrointestinal Endoscopy (ESGE) Guideline - Update 2021. Endoscopy. 2021;53(3):300-32. https://doi.org/10.1055/a-1369-5274.
7. Laine L, Barkun AN, Saltzman JR, Martel M, Leontiadis GI. ACG clinical guideline: Upper gastrointestinal and ulcer bleeding. Am J Gastroenterol. 2021;116(5):899-917. https://doi.org/10.14309/ajg.0000000000001245.
8. National Comprehensive Cancer Network (NCCN). NCCN clinical practice guidelines in oncology: Gastrointestinal stromal tumours. Version 1.2025. Plymouth Meeting (PA): National Comprehensive Cancer Network; 2025. Available from: https://www.nccn.org/professionals/physician_gls/pdf/gist.pdf. Accessed 17 January 2026.
9. Nishida T, Kawai N, Yamaguchi S, Nishida Y. Submucosal tumours: Comprehensive guide for the diagnosis and therapy of gastrointestinal submucosal tumours. Dig Endosc. 2013;25(5):479-89. https://doi.org/10.1111/den.12149.