*S Afr J Surg.* 2026;64:287-291. Online first
https://doi.org/10.36303/SAJS.02873

Open Access article distributed under the terms of the Creative Commons Attribution-Non-Commercial Works 4.0 South Africa License (CC BY NC)
https://creativecommons.org/licenses/by-nc/4.0/

S Afr J Surg
ISSN: 0038-2361 eISSN: 2078-5151
© 2026 The Author(s)
HEPATOPANCREATOBILIARY

# Beyond the scope: endoscopic approach for the definitive management of major bile duct injuries

**M Bhana,[1] D Creamer,[2] C Kloppers,[1] M Bernon,[1] S Burmeister,[1] B Misoi,[1] P Apai,[1] E Jonas[1]**

[1] *Hepatobiliary Unit, Department of Surgery, Groote Schuur Hospital, University of Cape Town, South Africa*
[2] *Department of Interventional Radiology, Groote Schuur Hospital, University of Cape Town, South Africa*

***Corresponding author, email:*** *malinibhana@yahoo.com*

**Background:** Traditionally major bile duct injuries (MBDIs) have been managed with surgery. Endoscopic treatment for MBDIs has more recently been performed with comparable results and lower morbidity rates, but data regarding longer term outcomes is lacking.
**Methods:** This is a retrospective review analysing the short- and long-term outcomes of endoscopic management in consecutive patients with MBDIs.
**Results:** Fourteen patients were included with a median age of 40 years (range 26–55 years), of whom 11 (79%) were female. Laparoscopic cholecystectomy (LC) ($n$ = 12, 86%) was the most common cause of injury while penetrating trauma accounted for ($n$ = 2, 14%). The most common presenting symptoms were pain ($n$ = 9) and bile leaks ($n$ = 9). Strasberg E2 (8,56%) was the most common injury. Seven patients (50%) had endoscopic stenting while the remainder underwent the combined endoscopic and radiologic approach (CERA). Successful endoscopic management was achieved in all patients. Complications included cholangitis and pancreatitis, which were mild. In the patients still alive, none developed stenosis during a median follow-up of 22 months.
**Conclusions:** The definitive endoscopic management of patients with MBDIs represents a major advance in the management of these injuries. Endoscopic management is a safe and durable intervention for patients with MBDIs, with outcomes comparable to those ascribed to a surgical reconstruction. A broader view of management in these patients should be considered at a multidisciplinary team and considered for inclusion in treatment algorithms of MBDIs.
**Keywords:** bile duct injury, Strasberg classification, endoscopic retrograde cholangiopancreatography, combined endoscopic and radiologic approach, modified rendezvous

## Introduction

One hundred and forty-one years ago, the first cholecystectomy was carried out by Langenbuch.[1] Iatrogenic bile duct injuries (BDIs) at cholecystectomy remain a devastating complication. In the open cholecystectomy era, the incidence of BDIs was reported to be around 0.1%. Post-introduction of laparoscopic cholecystectomy (LC), the incidence has risen to 0.8%.[2,3] The injuries range in severity from a simple cystic duct stump leak to a complete transection of a major bile duct.

The original description of major bile duct injuries (MBDIs) by McMahon encompassed a transection of the common hepatic duct (CHD) or common bile duct (CBD), partial injury involving > 25% of the circumference of the ducts and includes a postoperative stricture not otherwise specified.[4] Traditionally, MBDIs have been managed with surgery, hepaticojejunostomy being widely accepted as the operation of choice due to favourable long-term outcomes.[5] However, this procedure is associated with significant morbidity and mortality. Endoscopic management has been used as an alternate, usually in injuries with incomplete transection of the bile duct where ductal continuity allows for guidewire cannulation. More recently endoscopic treatment for MBDIs has been expanded to those with complete transection and tissue loss, with comparable results and lower morbidity rates.[6-8] However, outcome data of this endoscopic management of MBDIs are lacking. The aim of this study was to analyse the short- and long-term outcomes of endoscopic management in patients with MBDIs treated at our centre.

## Methods

This is a retrospective cohort study. An HREC approved Bile Duct Injury Registry (HREC R032/2014) was used to identify patients between 1 January 2015 and 31 December 2024. Inclusion criteria were patients aged 18 years and older with MBDIs, as defined by McMahon, who were definitively managed endoscopically. Exclusion criteria were any patients requiring surgery for the management of MBDIs, and blunt abdominal trauma as a mechanism of injury. Injuries were classified according to the Strasberg-Bismuth Classification of BDIs (Figure 1).

The primary aim was to assess the short- and long-term outcomes of MBDIs managed endoscopically at Groote Schuur Hospital, Cape Town, South Africa. The secondary aim is to assess procedural complications of endoscopic management of MBDIs.

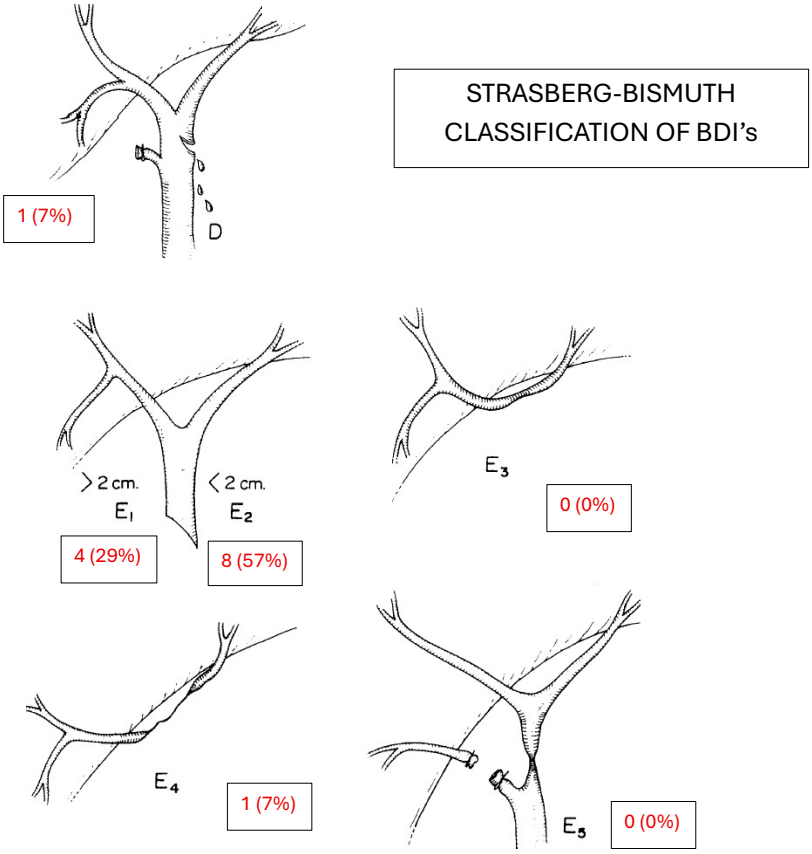


*Figure 1: Strasberg-Bismuth Classification of Bile Duct Injuries with their injury distribution; Type D – Lateral injury to extrahepatic bile duct, Type E – Circumferential injury to major bile duct, Type E1/E2 – Transection > 2 cm or < 2 cm from hilum, Type E3 – Hilar injury but confluence intact, Type E4 – Confluence disrupted with separated right and left duct, Type E5 – Combined common hepatic duct and aberrant right duct injury*



*Figure 2a: Cholangiogram with proximal cutoff of biliary system (red arrow)*



*Figure 2b: Defect demonstrated with PTC (red arrow) placed via Rendezvous bridging the gap*

## Treatment protocol

The protocol at our tertiary centre HPB Unit regarding imaging of MBDIs is that cross-sectional imaging was obtained. Contrast-enhanced computerised tomography (CE-CT), magnetic resonance imaging (MRI), or both, is used to assess for vascular injury, intra-abdominal collections. Biliary anatomy was delineated by magnetic resonance cholangio-pancreatography (MRCP). A sinogram through a surgical or percutaneously placed drain was a helpful adjunct in delineating biliary anatomy when present in selected patients. Our routine management of BDIs included control of sepsis by administering of appropriate antibiotics and early percutaneous drainage of intra-abdominal collections. Based on imaging, mapping of the injury is performed, and a preliminary treatment plan is devised. In general, patients were considered for definitive endoscopic management when anatomy was considered favourable, regardless of ductal continuity or tissue loss, which included a 1 cm or more CHD stump for landing of the proximal end of a self-expandable metal stent (SEMS). However, we also included patients who underwent initial internalisation of the bile leak as a bridge to surgery, but where definitive endoscopic treatment was ultimately pursued after discussion with the patient. All interventions, both percutaneous and endoscopic, were performed under conscious sedation or general anaesthesia.

In those patients who were deemed suitable for definitive endoscopic management, a percutaneous transhepatic cholangiogram (PTC) was performed if dilated intrahepatic ducts (IHDs) were noted, as the first procedure (Figure 2a). In patients where there was contrast extravasation into the subhepatic space from the proximal system, an attempt was made to pass a guidewire into the distal bile duct. If this was successful, an external internal catheter was placed with the distal tip secured in the duodenum (Figure 2b). If this was not successful, the PTC drain was secured in the subhepatic space to allow drainage of both the proximal bile ducts and subhepatic collections. In patients where the proximal bile duct was occluded by a ligaclip, clips were dislodged at the first or subsequent PTCs before internalisation was attempted. If, however, a non-dilated biliary system was noted, an endoscopic retrograde cholangiography (ERC) was performed as the first procedure (Figure 3a). Once the proximal bile ducts were successfully cannulated with a guidewire, a stent (Figure 3b) was placed.

In patients with discontinuity of the bile duct, with or without substance loss where the defect could not be traversed with a guidewire either percutaneously or trans-papillary, a rendezvous procedure was performed. As a first step, a stone extraction basket was deployed via PTC or ERC in the extraductal subhepatic space. A guidewire was then placed from the opposite site of access, which was then snared by the basket and exteriorised. An appropriate stent was then placed, ensuring biliary continuity and bridging the defect. This method is referred to as the combined endoscopic and radiologic approach (CERA). Fully covered 10 mm SEMS were used in all patients of sufficient length to cover the defect and allow for the distal end of the stent to lie in the duodenum.



*Figure 3a: Cholangiogram demonstrating proximal cutoff with metal clips at the site of occlusion (red arrow)*

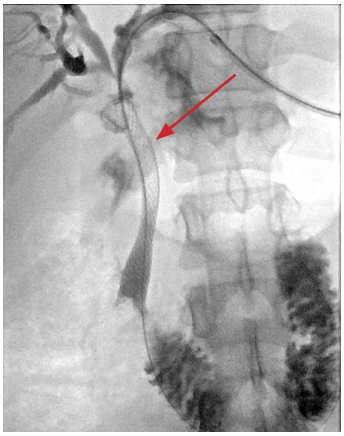

*Figure 3b: Cholangiogram done after ERCP where a distal stent (red arrow) was placed to allow for drainage of a bile collection and CERA used via PTC to bridge the defect*

Patients underwent stent exchange every 3 months for a total stent duration of at least 9 months. After stent removal, patients were followed up clinically, and with liver function tests (LFTs). Technical success was defined as biliary tract continuity successfully established with at least one stent bridging the defect or stricture and long-term clinical success defined as an asymptomatic patient with normalisation of LFTs or improving LFTs upon stent removal and follow-up. No imaging was done for follow-up in patients that were asymptomatic – LFT trends were noted and symptoms monitored. These patients should have no indication for repeat endoscopic, percutaneous or surgical intervention.

## Results

A summary of the patient's demographics and outcomes can be found in Table I.

### *Demographics and procedure*

Fourteen patients were included in this study with a median age of 40 years (range 26–55 years), of whom 11 (79%) were female. The median BMI was 36 (range 21–63). The most common cause of injury was a misadventure during LC ($n$ = 12, 86%) with penetrating trauma ($n$ = 2, 14%) accounting for the remainder. Four (33%) of the LC injuries were converted to an open procedure.

### *Presentation and description of injury*

The median duration of time from injury to diagnosis was 11 days (range 3–30 days). The most common presenting symptoms were pain ($n$ = 9) and bile leaks ($n$ = 9). Obstructive jaundice was present in four (29%) patients. The mean total bilirubin on presentation was 62 ug/dl, the mean ALP was 195 and GGT 339 (units). Eleven (78%) patients were evaluated for an associated vascular injury with imaging, of whom an injury was detected in two (18%). Percutaneous drainage of collections was performed in two patients (15%). A Strasberg E2 injury was found in eight patients (57%) (Figure 1). In seven (50%) patients endoscopic stenting was performed while the remainder underwent CERA. In one patient, where an unreconstructible hilar injury was found at emergency laparotomy, multiple 8 mm SEMS were used (Figure 4).

**Table I: Detailed patient profile**

| Age, y/sex | Primary Operation | Converted to OC | Delay to diagnosis (D) | Classification of BDI, Strasberg | Vascular Injury | Time from injury to endoscopic management (D) | Type of Endoscopic management | Length of stenting (M) | Follow-up period (M) | Outcome (success/failure) |
|---|---|---|---|---|---|---|---|---|---|---|
| 47 M | TL | N/A | 5 | E2 | Y | 5 | CERA | 5 | 24 | Success |
| 52 M | LC | N | 9 | E2 | N | 9 | ES | 48 | 48 | Success |
| 29 F | LC | N | 7 | E2 | N | 7 | CERA | 11 | 13 | Success |
| 35 F | LC | Y | 30 | E2 | N | 30 | ES | 5 | 50 | Success |
| 52 F | LC | Y | 5 | E4 | N | 5 | CERA | 10 | 1 | Under treatment |
| 31 F | LC | N | 7 | E1 | N | 7 | CERA | 12 | 1 | Success |
| 30 F | LC | N | 8 | E2 | N | 8 | CERA | 6 | 6 | Under treatment |
| 55 F | LC | N | 3 | E1 | N | 3 | ES | 6 | 12 | Success |
| 33 F | LC | N | 28 | E2 | N | 28 | ES | 19 | 12 | Success |
| 42 F | LC | N | 26 | E2 | N | 26 | ES | 16 | 12 | Success |
| 44 F | LC | Y | 6 | D | N | 6 | ES | 8 | 18 | Success |
| 45 F | LC | Y | 6 | E1 | Y | 6 | CERA | 12 | 48 | Success |
| 26 M | TL | N/A | 3 | E1 | N | 3 | ES | 1 | 1 | Success |
| 48 F | LC | N | 17 | E2 | N | 17 | CERA | 12 | 1 | Success |

TL – trauma laparotomy, LC – laparoscopic cholecystectomy, Y – yes, N – no, D – day, M – month, N/A – not applicable, CERA – combined endoscopic and radiologic approach, ES – endoscopic stenting

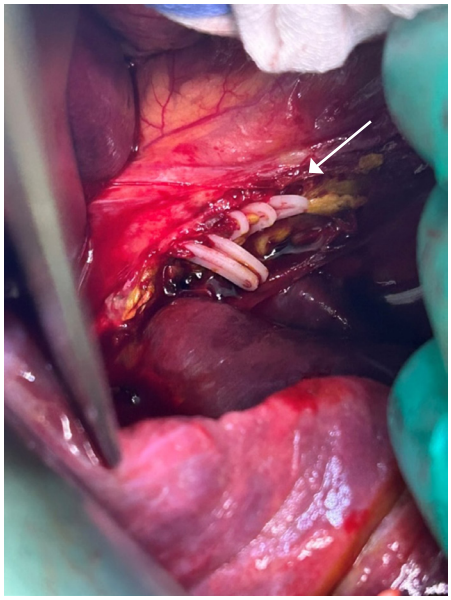

*Figure 4: Intraoperative finding of multiple plastic clips in hilum (white arrow)*

### *Management*

A detailed summary of the treatment per patient is shown in supplementary Table I. Occluding ligaclips were found in six cholecystectomy patients (58%), all of which were successfully dislodged. The mean number of procedures per patient was three, with a median stent duration of 12 months (range 5–48 months).

### *Complications*

Cholangitis occurred in two patients (15%), both requiring stent repositioning. One patient had a mild post-ERCP pancreatitis.

### *Follow-up*

The median duration of follow-up was 22 months (range 1–50 months; range for alive), with a clinical and technical success rate of 100%. One trauma patient died 30 days post-initial injury, from complications of injuries sustained by trauma unrelated to the BDI. No patients developed strictures during follow-up.

## Discussion

In our study of 14 patients with MBDIs, successful endoscopic management was achieved in all patients. Complications included cholangitis and pancreatitis, which were mild. In the patients still alive, none developed stenosis during a median follow-up of 22 months.

The major cause of a MBDI remains a LC as is demonstrated in this cohort.[9] A third of patients who had a LC were also converted to an open procedure. These patients presented with only postoperative detection of the MBDI, highlighting that conversion is not always a safer procedure and alternative bail-out options should be considered when encountering a difficult LC. In line with previous studies, the majority of these patients were female, and below the age of 50 years.[10]

Surgical repair is still practised as the management of choice for MBDIs, with recognised, favourable long term outcomes.[11] Morbidity rates, however, are a concern and the timing of the surgery can be complex. This is compounded by the fact that intraoperative recognition of BDIs is infrequent, and the majority of our patients presented with symptoms more than a week after the initial surgery, making an early surgical repair challenging due to the ongoing bile leak and sepsis. Endoscopic management in these cases may be a more attractive and feasible option, even if only a bridge to surgery.

Other causes of MBDI, for example, trauma related injuries, are rare, occurring in about 1% of patients with penetrating trauma.[12] Percutaneous and endoscopic intervention for traumatic BDIs has been well described in the management of these patients, mostly to address minor MBDIs with postoperative bile leaks.[13,14] Definitive endoscopic management for MBDIs caused by trauma has not been well reported on, with the majority of patients undergoing surgery for associated injuries.[14,15]

Occluding ligaclips are often a cause of obstruction as demonstrated in patient 9 of this cohort (Figure 3a). They are radio opaque (titanium) and easily visible on imaging. Attempts at removing them have a high chance of success and should be pursued when possible. Hem-o-lock clips, however, cannot be removed endoscopically and as seen in a patient in this cohort (Figure 4) will require surgical removal.

As expected, patients managed with CERA had on average a higher number of procedures needed to complete treatment versus those undergoing endoscopic stenting alone, reflecting the complexity of the procedure. However, once the initial stent is placed, the complexity of the follow-up stent exchange procedures drops, and they go on to have the general average of stent exchanges six monthly. In our study, patients required longer stenting times for complete transections (15.2 months) ($n$ = 7), compared to partial transections, (11.5 months) ($n$ = 5).

The favourable results of our and previously published cohort studies warrants revisiting interventional non-operative treatment as a treatment modality that should be considered for inclusion in treatment algorithms of MBDIs, including those with tissue loss. It has many advantages over external drainage, and internalisation of biliary drainage is particularly important in patients requiring prolonged prehabilitation prior to definitive surgery. Firstly, fluid losses and electrolyte imbalances are prevented, and nutritional recovery is enhanced due to the luminal presence of bile. Secondly, they can be managed at home instead of a protracted hospital admission.

Post-procedure, cholangitis was the commonest complication noted and was usually due to incomplete drainage due to stent positioning – this was successfully corrected by stent exchange. It emphasises close patient review and follow-up to mitigate this and should also be a consideration when choosing endoscopic management for patients who may not have good access to healthcare and follow-up. There were no mortalities in our study for procedure- or complication-related events.

The limitations remain that CERA is an advanced procedure requiring significant expertise and experience and may not be possible at many centres of care where patients with MBDIs present to. It also has a relatively small cohort, retrospective methodology, and single-centre setting, which may restrict the broader applicability of the findings.

## Conclusion

In our experience, endoscopic management is a safe and durable intervention for patients with MBDIs, comparable to outcomes ascribed to a surgical reconstruction, even when tissue loss is present. A broader view of management in patients with MBDIs should be considered and the results of this cohort emphasise the importance of a multidisciplinary team, including experienced surgical gastroenterologists and interventional radiologists, for consideration of both diagnosis and method of intervention.

### *Conflict of interest*

The authors declare no conflict of interest.


### *Funding source*

No funding was required.


### *Ethical approval*

Ethical approval was obtained from the University of Cape Town Human Research Ethics Committee (HREC 414/2018).


### *ORCID*

M Bhana https://orcid.org/0000-0001-6301-2234
D Creamer https://orcid.org/0000-0003-1620-5855
C Kloppers https://orcid.org/0000-0003-2438-6879
M Bernon https://orcid.org/0000-0002-7967-8548
S Burmeister https://orcid.org/0000-0003-0888-7606
B Misoi https://orcid.org/0000-0002-5419-6278
P Apai https://orcid.org/0000-0001-6655-0062
E Jonas https://orcid.org/0000-0003-0123-256X


### REFERENCES


1. Traverso LW. Carl Langenbuch and the first cholecystectomy. Am J Surg. 1976;132(1):81-2. https://doi.org/10.1016/0002-9610(76)90295-6.
2. Strasberg SM, Hertl M, Soper NJ. An analysis of the problem of biliary injury during laparoscopic cholecystectomy. J Am Coll Surg. 1995;180(1):101-25. PMID: 8000648.
3. Barone JE, Lincer RM. Correction: A prospective analysis of 1518 laparoscopic cholecystectomies. N Engl J Med. 1991;325(21):1517-8. https://doi.org/10.1056/NEJM199111213252117.
4. McMahon AJ, Fullarton G, Baxter JN, O'Dwyer PJ. Bile duct injury and bile leakage in laparoscopic cholecystectomy. Br J Surg. 1995;82(3):307-13. https://doi.org/10.1002/bjs.1800820308.
5. de'Angelis N, Catena F, Memeo R, et al. 2020 WSES guidelines for the detection and management of bile duct injury during cholecystectomy. World J Emerg Surg. 2021 Jun 10;16(1):30. https://doi.org/10.1186/s13017-021-00369-w.
6. Donatelli G, Vergeau BM, Derhy S, et al. Combined endoscopic and radiologic approach for complex bile duct injuries (with video). Gastrointest Endosc. 2014;79(5):855-64. https://doi.org/10.1016/j.gie.2013.12.034.
7. Fiocca F, Salvatori FM, Fanelli F, et al. Complete transection of the main bile duct: Minimally invasive treatment with an endoscopic-radiologic rendezvous. Gastrointest Endosc. 2011;74(6):1393-8. https://doi.org/10.1016/j.gie.2011.07.045.
8. Schreuder AM, Booij KA, de Reuver P, et al. Percutaneous-endoscopic rendezvous procedure for the management of bile duct injuries after cholecystectomy: Short- and long-term outcomes. Endoscopy. 2018;50(6). https://doi.org/10.1055/s-0043-123935.
9. Fatima J, Barton JG, Grotz TE, et al. Is there a role for endoscopic therapy as a definitive treatment for post-laparoscopic bile duct injuries? J Am Coll Surg. 2010;211(4):495-502. https://doi.org/10.1016/j.jamcollsurg.2010.06.013.
10. Booij KA, de Reuver PR, van Dieren S, et al. Long-term impact of bile duct injury on morbidity, mortality, quality of life, and work related limitations. Ann Surg. 2018;268(1):143-150. https://doi.org/10.1097/SLA.0000000000002258.
11. Marichez A, Adam JP, Laurent C, Chiche L. Hepaticojejunostomy for bile duct injury: State of the art. Langenbecks Arch Surg. 2023;408(1):107. https://doi.org/10.1007/s00423-023-02818-3.
12. Molinari M. Traumatic bile duct injuries. In: Actual problems of emergency abdominal surgery. Garbuzenko DV, editor. IntechOpen: Rijeka; 2016. https://doi.org/10.5772/64535.
13. Yuan KC, Wong YC, Fu CY, et al. Screening and management of major bile leak after blunt liver trauma: A retrospective single centre study. Scand J Trauma Resusc Emerg Med. 2014;22:26. https://doi.org/10.1186/1757-7241-22-26.
14. Bridges A, Wilcox CM, Varadarajulu S. Endoscopic management of traumatic bile leaks. Gastrointest Endosc. 2007;65(7):1081-5. https://doi.org/10.1016/j.gie.2006.11.038.
15. Richey JS, Manning BM, Jones WB. Outcomes of endoscopic stenting for traumatic biliary and pancreatic fistulae. Am Surg. 2016;82(7):588-93. https://doi.org/10.1177/000313481608200723.


***Supplementary table available online at: https://ojs.sabinet.co.za/index.php/sajs/article/view/2873/2449***