SAJS
Case Report

Missile embolism – pulmonary vein to systemic bullet embolism

A case report and review of the literature

LETLHOGELA M. NTLHE, F.C.S. (S.A.)
Department of Surgery, Dr George Mukhari Hospital and University of Limpopo, Medunsa Campus, Pretoria

STEPHANUS M. KOMATI, F.C.P. (S.A.)
PIETER A. FOURIE, M.MED.
ALEWYN P. ROSSOUW, M.MED.
Private practice, Pretoria

Summary

Missile embolism occurs very rarely. It was first reported by Thomas Davis in 1834, and only 153 cases had been reported up to 1988.[1] Rich *et al*. reported a 0.3% incidence in 7 500 cases of vascular injury in the Vietnam conflict.[2] To our knowledge, this is the first reported case of pulmonary vein entry and internal carotid artery embolisation.

Case report

A 32-year-old man sustained a close-range low-calibre gunshot injury to the anterior left chest. He was admitted comatose and shocked. The chest radiograph was normal. A provisional diagnosis of cardiac injury was made and the patient was immediately taken to theatre as part of the resuscitation process, where a trans-oesophageal echocardiogram (TEE) was found to be normal. Thoracotomy was therefore avoided and the patient was admitted to the intensive care unit for further management.

He regained consciousness in the morning, but had a dense left-sided hemiplegia, expressive dysphasia and retrograde amnesia. Two months later he presented with additional symptoms of right-sided neck pain, worse on turning his head to the right, occasional left chest pain, and grand mal epilepsy controlled with phenytoin. Both carotid pulses were palpable.

Right-sided intracranial embolisation was suspected, and the patient was assessed accordingly. On imaging with four-vessel angiography and computed brain tomography, a bullet was noted in the right internal carotid artery with no distal flow, the circle of Willis was patent, and a right fronto-parietal infarct was seen on the brain scan (Figs 1 and 2). Conservative management was pursued with analgesics and phenytoin, but the patient continued to request the removal of the bullet because he could not tolerate the neck pain. The bullet was surgically removed 7 months after injury under local anaesthesia.

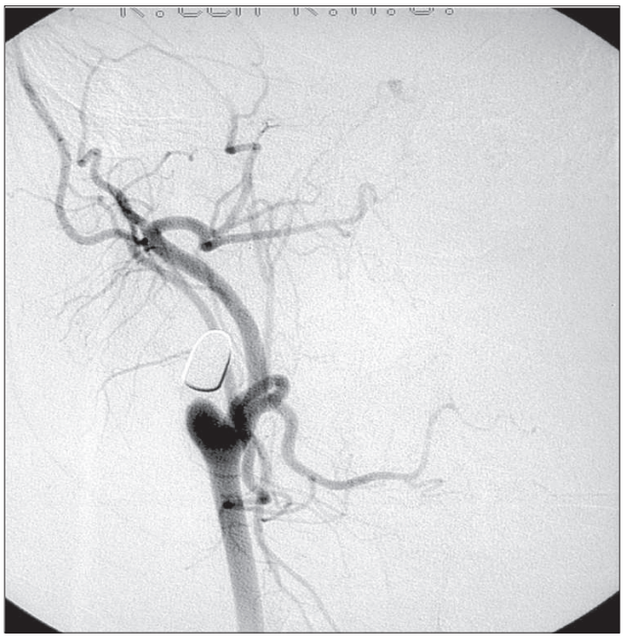

Fig. 1. Arteriogram showing a bullet embolus in the proximal right internal carotid artery with distal occlusion.

At operation a marked inflammatory reaction at the bullet site in the proximal internal carotid artery was found. The common and external carotid arteries were patent and proximal and distal control on the common carotid and external carotid artery was obtained. Direct transverse arteriotomy was done on the internal carotid artery where the bullet could be felt. The bullet was retrieved with the segment of vessel it had impacted in, and the internal carotid artery was ligated.

Immediately postoperatively there was a dramatic (though transient) complete recovery of the left hemiplegia and expressive dysphasia. At the time of writing the patient was continuing to take phenytoin daily, his speech was normal and he had mild residual left hemiparesis. Histological

Pg 58-60.indd 58 5/30/08 9:51:10 AM

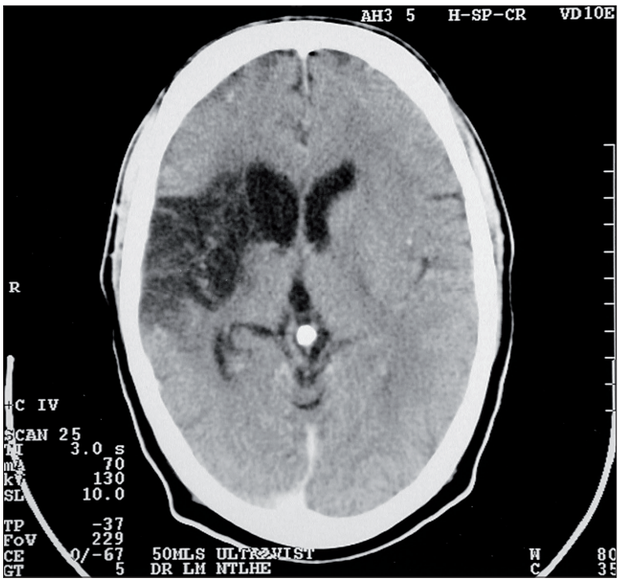

Fig. 2. Brain scan showing a right fronto-parietal infarct.

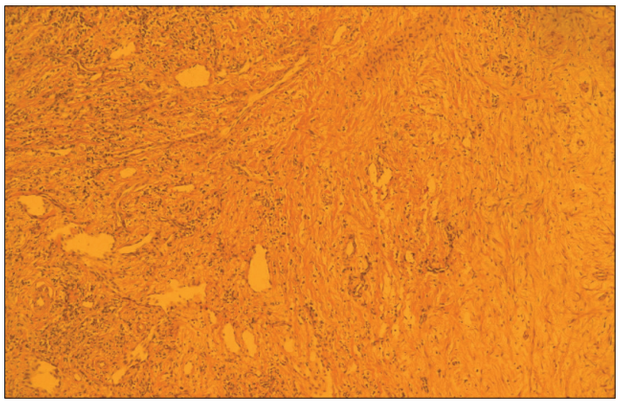

Fig. 3. Slide of the internal carotid artery demonstrating transmural infiltration by chronic inflammatory cells.

examination of the artery showed transmural infiltration by chronic inflammatory cells (Fig.3).

Discussion

The phenomenon of pulmonary vein entry by a bullet was first reported by Schmidt in 1885.[3] Civilian low-calibre, low-velocity gunshot violence accounts for 80% of missile embolisation; the remainder of cases are military. Suspicion should be aroused when there is an entrance wound without an exit wound and clinical features of embolisation. Early embolectomy is suggested because it prevents thrombosis and further embolisation and reduces the risk of sepsis.[4-6]

A search for a bullet entry site through the aorta or cardiac route in our patient was negative. Direct arteriotomy and removal of the bullet was done 7 months after the event because the patient found the pain caused by the bullet unbearable.

A thorough search for emboli may include a contrast-enhanced computed tomography scan, echocardiography, a duplex Doppler scan, phlebography and angiography; recently angioscopy has been suggested.[6-10] Shannon *et al*. recommend taking plain radiographs above and below the bullet entry site before embarking on other more costly investigations, which we support.[6] Dada and Loftus suggest that meticulous examination of the brain be carried out at autopsy when brain softening and infarction is encountered in cases of suspected intracranial embolisation, because missile emboli may be missed at autopsy.[9]

The missile may be retrieved by direct arteriotomy or Fogarty embolectomy. Embolectomy is not recommended if the missile is irregular or adherent, or if the vessel is very small, because further vascular damage may occur during extraction.

Bullet embolism is rare and pulmonary vein entry unusual. A high index of suspicion for missile embolic events should be entertained when a patient has a missile injury without an exit wound.

Professor J. V. Robbs is thanked for his valuable comments and Mrs J. C. Ferreira for patience in typing the manuscript.

REFERENCES

1. Michelassi F, Pietrabissa A, Ferrari M, Mosca F, Vargish T, Moosa HH. Bullet emboli to the systemic and venous circulation. *Surgery* 1990; 107: 239-245.
2. Rich NM, Collins GJ Jr, Andersen CA, McDonald PT, Kozloff L, Ricotta JJ. Missile emboli. *J Trauma* 1978; 18: 236-239.
3. Schmidt GB. A fatal gunshot wound of the vascular system with embolization to the lower extremities. *Zentralbl Chir* 1885; 8: 131.
4. Bongard F, Johs SM, Leighton TA, Klein S. Peripheral arterial shotgun missile emboli : Diagnostic and therapeutic management – case reports. *J Trauma* 1991; 31: 1426-1431.
5. Chapman AJ, McClain JBS. Wandering missiles: autopsy study. *J Trauma* 1984; 24: 634-637.
6. Shannon JJ Jr, Nghia M, Stanton PE Jr, Dimler M. Peripheral arterial missile embolization: A case report and 22-year literature review. *J Vasc Surg* 1987; 5: 773-778.
7. Vascik JM, Tew JM Jr. Foreign body embolization of the middle cerebral artery: Review of the literature and guidelines for management. *Neurosurgery* 1982; 11: 532-536.
8. Miner ME, Handel SF. Traumatic embolization of the intracranial internal carotid artery. *Neuroradiology* 1978; 15: 141-143.
9. Dada MA, Loftus IAJ, Stuart GR. Shotgun pellet embolism to the brain. *Am J Forensic Med Pathol* 1993; 14: 58-60.
10. Robbs JV. Penetrating cervico-mediastinal vascular injury. Presentation at the World Congress of Trauma, Durban, 12-15 August 2003.

Pg 58-60.indd 60 5/30/08 9:51:12 AM