*S Afr J Surg.* 2026;64:294-296. Online first
https://doi.org/10.36303/SAJS.04527

Open Access article distributed under the terms of the Creative Commons Attribution-Non-Commercial Works 4.0 South Africa License (CC BY NC)
https://creativecommons.org/licenses/by-nc/4.0/

S Afr J Surg
ISSN: 0038-2361 eISSN: 2078-5151
© 2026 The Author(s)
CASE REPORT

# Blue rubber bleb nevus syndrome: Balancing bleeding and thrombosis

**M Vally,[1] L Choonara,[2] I Berkowitz,[3] B Jacobson,[4,5] S Louw[4,5]**

[1] *Division of Internal Medicine and Haematology, Charlotte Maxeke Johannesburg Academic Hospital, University of the Witwatersrand, South Africa*
[2] *Department of Emergency Medicine, Faculty of Health Sciences, University of the Witwatersrand, South Africa*
[3] *Department of Medical Gastroenterology, Netcare Milpark Hospital, South Africa*
[4] *Department of Molecular Medicine and Haematology, School of Pathology, Faculty of Health Sciences, University of the Witwatersrand, South Africa*
[5] *National Health Laboratory Service, South Africa*

***Corresponding author, email:*** *cerezvally@gmail.com*

**Summary**
Blue rubber bleb nevus syndrome (BRBNS) is a rare venous malformation syndrome characterised by chronic gastrointestinal bleeding and iron-deficiency anaemia. We report a 79-year-old woman with known BRBNS who presented with overt gastrointestinal bleeding requiring blood transfusion and intravenous iron replacement. Upper and lower gastrointestinal endoscopy failed to reveal a bleeding source while capsule endoscopy demonstrated actively bleeding small-bowel venous malformations. During ongoing evaluation, she developed an ischaemic stroke despite the absence of an identifiable embolic source or inherited thrombophilia. The competing risks of haemorrhage and thrombosis created a significant therapeutic dilemma, necessitating prioritisation of haemorrhage control, with anticoagulation withheld because of the risk of recurrent gastrointestinal bleeding. This case highlights that patients with BRBNS may present with simultaneous thrombotic and haemorrhagic challenges, requiring individualised multidisciplinary management when standard antithrombotic strategies are contraindicated.
**Keywords:** blue rubber bleb nevus syndrome, venous malformations, gastrointestinal bleeding, venous thromboembolism, capsule endoscopy

## Case report

A 79-year-old Caucasian woman with blue rubber bleb nevus syndrome (BRBNS) diagnosed by video capsule endoscopy (VCE) in 2014, without associated cutaneous manifestations, presented in June 2025 with a two-week history of symptomatic anaemia following 3 episodes of haematochezia. She was receiving low-dose aspirin following a myocardial infarction in 2005 and had metabolic syndrome (hypertension and type 2 diabetes mellitus). She had sustained a pulmonary embolism in 2007, for which warfarin was discontinued after a GIT bleed in 2014; aspirin was, however, continued.

On examination, she was tachycardic but normotensive, with marked pallor. The remainder of the systemic examination, including digital rectal examination, was unremarkable. Laboratory investigations revealed a haemoglobin concentration of 7.8 g/dL (reference range 12.0–15.5 g/dL) with microcytic hypochromic indices and a ferritin level of 16 µg/L (reference range 13–150 µg/L), consistent with an iron-deficiency anaemia. Renal and liver function tests, coagulation parameters, and inflammatory markers were normal.

She required multiple blood transfusions and 3 doses of intravenous iron. Upper endoscopy and colonoscopy were unremarkable, with no visible BRBNS lesions. Subsequent video capsule endoscopy revealed multiple venous blebs and ectatic lesions in the distal jejunum and proximal ileum with active bleeding, consistent with BRBNS lesions (Figure 1).

In August 2025, she represented with an acute cerebrovascular accident. Computed tomography angiography confirmed a subacute left posterior cerebral artery infarction without carotid stenosis or cerebral arteriovenous malformations. Electrocardiography, Holter monitoring, transthoracic echocardiography, and a comprehensive thrombophilia screen including antiphospholipid antibodies, lupus anticoagulant, protein C and S, antithrombin, homocysteine, and factor V Leiden mutation, were negative. Additionally, there was no evidence of atrial fibrillation or another definite cardioembolic source. No radiological features suggested cerebral involvement by BRBNS. Although the aetiology of the stroke remained uncertain following inpatient evaluation, further outpatient investigation for occult cardioembolic sources, including prolonged cardiac rhythm monitoring, was planned.

The coexistence of active GIT bleeding and ischaemic stroke posed a therapeutic challenge. Given the diffuse distribution of multiple bleeding lesions throughout the distal jejunum and proximal ileum, focal endoscopic therapy such as argon plasma coagulation was not considered feasible, as treatment would have required extensive endoscopic intervention with a high likelihood of residual untreated lesions. Surgical resection was likewise inappropriate

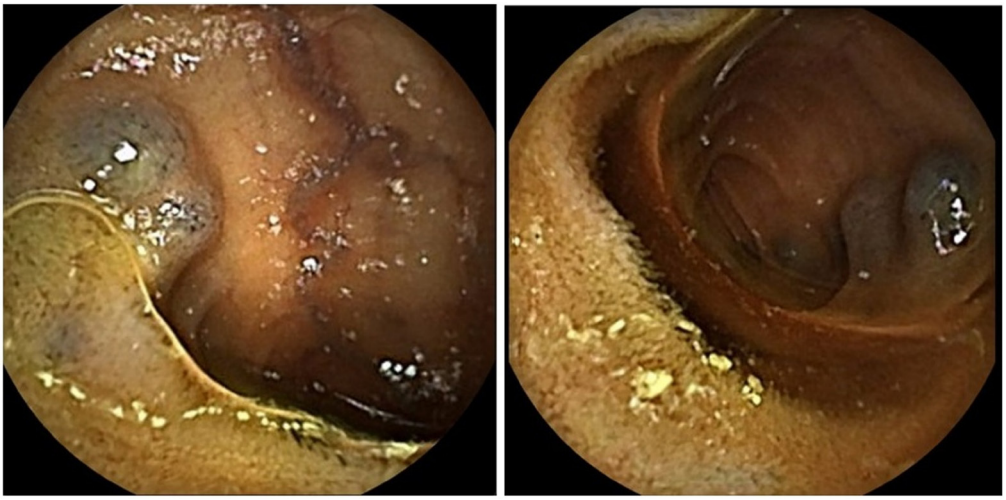

*Figure 1: Video capsule endoscopy images demonstrating multiple BRBNS lesions within the small bowel. More than 20 lesions were identified throughout the examination*

because of the multifocal disease. Anticoagulation was therefore withheld because of the high risk of recurrent gastrointestinal bleeding. Low-dose aspirin was continued with optimisation of cardiovascular risk factors and iron replacement.

At the most recent follow-up, the patient had experienced no further episodes of gastrointestinal bleeding or transfusion requirements. She remained under outpatient follow-up and was undergoing neurological rehabilitation with gradual recovery following her stroke.

## Discussion

BRBNS is a rare vascular disorder characterised by multifocal venous malformations of the skin and visceral organs, most notably the gastrointestinal tract (GIT).[1] The condition was first described by William Bennett Bean in 1958 and earlier by George Gascoyen[2] in 1860 and still has the eponym Bean syndrome. Only 200 cases have been reported in the literature.[1] The descriptive term reflects its clinical appearance: "blue" denotes the colour imparted by deoxygenated venous blood; "rubber bleb" describes the soft, compressible nature of the lesions; and "nevus" reflects the congenital origin of the disorder.[3]

Cutaneous lesions are often the most visible manifestation; however, gastrointestinal involvement has the greatest clinical impact. Lesions may occur throughout the GIT but occur most commonly in the small intestine and colon and are associated with chronic occult or overt bleeding resulting in iron-deficiency anaemia.[3] In a European multicentre cohort, gastrointestinal involvement was reported in 80% of patients, with clinically significant bleeding in 50% and intervention required in 30%.[4] Lesions have also been described in the liver, spleen, central nervous system (CNS), and musculoskeletal system.[1]

At a molecular level, BRBNS is postulated to be the result of somatic activating mutations in the TEK gene which encodes the endothelial tyrosine kinase receptor TIE2, a regulator of vascular stability and angiogenesis.[5] These mutations result in ligand-independent receptor activation with unregulated downstream PI3K/AKT/mTOR signalling, leading to abnormal endothelial proliferation, survival, and migration.[5] Rare variants in non-TEK loci may further modulate signalling and extracellular matrix remodelling, contributing to phenotypic heterogeneity.[5] The resulting malformed venous channels are dilated and fragile.

Although BRBNS is classically associated with bleeding, increasing evidence from venous malformation syndromes suggests a paradoxical predisposition to thrombosis.[6] Localised intravascular coagulopathy, venous stasis within ectatic vascular channels and chronic activation of coagulation pathways have been proposed as potential mechanisms.[6] However, the true incidence and clinical significance of thrombotic events in BRBNS remain poorly defined.

In this context, we report a South African patient with BRBNS complicated by recurrent bleeding and thrombotic events, highlighting the clinical complexity of managing the coexistence of haemorrhagic and thrombotic conditions. Whether these thrombotic events represent a direct manifestation of BRBNS, an association, or coexisting vascular pathology remains uncertain. Although the pathobiology, driven by TEK mutations and resultant abnormal venous architecture, has been hypothesised to promote thrombosis through structural fragility and venous stasis, this remains a proposed rather than proven mechanism.[5]

From a management perspective, this challenging bleeding-thrombosis phenotype creates significant therapeutic dilemmas. Management remains individualised, largely informed by sparse case report literature, with anticoagulation carefully balanced against bleeding risk, particularly where lesions are diffuse and inaccessible.[7-9] In the present case, the coexistence of active gastrointestinal bleeding and ischaemic stroke necessitated prioritisation of haemorrhage control, with anticoagulation withheld due to ongoing bleeding. Anticoagulation was therefore not re-initiated because the risk of recurrent gastrointestinal bleeding was considered to outweigh the potential benefit of anticoagulation. Management therefore focused on supportive care, including transfusion support, iron replacement and optimisation of cardiovascular risk factors. Beyond supportive care, targeted therapies such as sirolimus show promise in reducing bleeding burden and may modify disease manifestations, although evidence remains limited.[10]

It is clear that the absence of robust epidemiological data underscores the need for collaborative registries and prospective studies to better define thrombotic risk and

guide management in this rare and complex condition. Overall, this case highlights the diagnostic and therapeutic challenges posed by the sequence of bleeding and thrombosis in BRBNS, and emphasises the need for careful, individualised, multidisciplinary management in the absence of clear evidence-based guidelines.

### *Conflict of interest*

The authors declare no conflict of interest.


### *Funding source*

No funding was required.


### *Ethical approval*

Ethical approval for publication of this case report was obtained from the Human Research Ethics Committee (Medical) of the University of the Witwatersrand (HREC reference number: M251089).


### *ORCID*

M Vally https://orcid.org/0009-0003-5603-7208
L Choonara https://orcid.org/0009-0003-8387-9742
I Berkowitz https://orcid.org/0009-0005-4220-3505
B Jacobson https://orcid.org/0000-0001-6981-3112
S Louw https://orcid.org/0000-0002-4315-1496


### REFERENCES


1. Kozai L, Nishimura Y. Clinical characteristics of blue rubber bleb nevus syndrome in adults: Systematic scoping review. Scand J Gastroenterol. 2023;58(10):1108-14. https://doi.org/10.1080/00365521.2023.2214263.
2. Gascoyen GG. Case of naevus involving the parotid gland and causing death from suffocation: Naevi of the viscera. Trans Pathol Soc Lond. 1860;11(1):267-9.
3. Nahm WK, Moise S, Eichenfield LF, et al. Venous malformations in blue rubber bleb nevus syndrome: Variable onset of presentation. J Am Acad Dermatol. 2004;50(5 Suppl):S101-S106. https://doi.org/10.1016/S0190-9622(03)02468-X.
4. Becq A, Bisdorff A, Riccioni ME, et al. Blue rubber bleb nevus syndrome: A European multicentre cohort study. Dig Liver Dis. 2025;57(2):603-8. https://doi.org/10.1016/j.dld.2024.10.001.
5. Limaye N, Wouters V, Uebelhoer M, et al. Somatic mutations in angiopoietin receptor gene TEK cause solitary and multiple sporadic venous malformations. Nat Genet. 2009;41(1):118-24. https://doi.org/10.1038/ng.272.
6. Martinez-Lopez A, Salvador-Rodriguez L, Montero-Vilchez T, et al. Vascular malformation syndromes: An update. Curr Opin Pediatr. 2019;31(6):747-53. https://doi.org/10.1097/MOP.0000000000000812.
7. Mithanthaya R, Ismail AGM, Muwanwella N, Venugopal K. Blue rubber bleb nevus syndrome in a patient on anticoagulation: A management challenge. BMJ Case Rep. 2023;16(11):e256702. https://doi.org/10.1136/bcr-2023-256702.
8. Liu YL, Jiang YP, Du J. Pulmonary embolism during pregnancy in a case of blue rubber bleb nevus syndrome. Chin Med J (Engl). 2019;132(12):1499-501. https://doi.org/10.1097/CM9.0000000000000268.
9. Giordano C, Battaglia E, Di Gioia CRT, et al. Blue rubber bleb nevus syndrome and pulmonary hypertension: An unusual association. Cardiovasc Pathol. 2004;13(6):317-22. https://doi.org/10.1016/j.carpath.2004.07.004.
10. Yuksekkaya H, Ozbek O, Keser M, Toy H. Blue rubber bleb nevus syndrome: Successful treatment with sirolimus. Paediatrics. 2012;129(4):e1080-e1084. https://doi.org/10.1542/peds.2010-3611.