S Afr J Surg. 2026;64:343-349. Online first
https://doi.org/10.36303/SAJS.05130

Open Access article distributed under the terms of the Creative Commons Attribution-Non-Commercial Works 4.0 South Africa License (CC BY NC)
https://creativecommons.org/licenses/by-nc/4.0/

S Afr J Surg
ISSN: 0038-2361 eISSN: 2078-5151
© 2026 The Author(s)
REVIEW

The expanding role of therapeutic endoscopy in metabolic and bariatric surgery

JA Lubbe

Division of Surgery, Department of Surgical Sciences, Faculty of Medicine and Health Sciences, Stellenbosch University, South Africa

Corresponding author, email: *jal@sun.ac.za*

Summary
The global prevalence of obesity has reached epidemic proportions, with more than one billion people worldwide living with obesity and its associated metabolic complications. As the most effective long-term treatment for severe obesity, metabolic and bariatric surgery (MBS) has expanded rapidly, with laparoscopic sleeve gastrectomy (SG) and Roux-en-Y gastric bypass (RYGB) becoming the most commonly performed procedures. Although generally safe, increasing procedural volume has been accompanied by postoperative complications including leaks, fistulas, strictures, bleeding and weight recurrence. Historically, many patients required revisional surgery, exposing them to considerable morbidity and mortality. Over the past decade, advances in therapeutic endoscopy have fundamentally changed this paradigm. Contemporary techniques, including endoscopic vacuum therapy, internal drainage, endoscopic suturing, over-the-scope clips and transoral outlet reduction, now achieve clinical success rates approaching or exceeding 80–90% for many indications, allowing most appropriately selected patients to avoid reoperation. Flexible endoscopy has therefore evolved from a predominantly diagnostic modality into an essential therapeutic discipline spanning postoperative rescue and long-term obesity care.

Introduction

Nearly 880 million adults and 159 million children and adolescents aged 5–19 years are currently living with obesity, and current projections suggest that by 2030 almost half of the world's adult population will have overweight or obesity.[1] Metabolic and bariatric surgery (MBS) remains the most effective long-term treatment for severe obesity and its associated metabolic complications. Reflecting the escalating global burden of obesity, procedure numbers continue to rise, with laparoscopic sleeve gastrectomy (SG) and Roux-en-Y gastric bypass (RYGB) accounting for more than 90% of metabolic operations worldwide.[2]

The success of MBS has inevitably been accompanied by an increasing absolute number of postoperative complications. Although overall morbidity is low, staple-line and anastomotic leaks, fistulas, strictures, bleeding, marginal ulceration, weight recurrence and altered gastrointestinal anatomy remain important therapeutic challenges. Historically, many required revisional surgery, exposing patients to substantial morbidity, prolonged hospitalisation and, in severe cases, increased mortality.

Over the past decade, advances in therapeutic endoscopy have fundamentally changed the management of postoperative complications following MBS. Contemporary techniques –including endoscopic vacuum therapy, internal drainage, over-the-scope clips, endoscopic suturing, self-expanding metal stents and endoscopic revision procedures – now achieve clinical success rates approaching or exceeding 80–90% for many indications, allowing most appropriately selected patients to avoid reoperation. Therapeutic endoscopy has therefore become a preferred first-line approach for many stable patients, preserving surgical reconstruction while reducing the morbidity of revisional surgery.

This evolution has redefined the role of the endoscopist within the multidisciplinary metabolic surgery team. Although endoscopy contributes to preoperative assessment, operative planning and long-term surveillance, its greatest impact has been the development of minimally invasive therapies that can diagnose and treat postoperative complications during the same procedure. The modern therapeutic endoscopist contributes to management of leaks, bleeding and strictures, as well as weight recurrence and dumping syndrome, Barrett's surveillance after SG, and biliary access in altered anatomy. Successful management increasingly depends on collaboration among surgeons, gastroenterologists, interventional radiologists, anaesthetists, dietitians and specialist nursing staff.

This review focuses on the expanding therapeutic role of endoscopy across MBS, examining contemporary evidence for minimally invasive management of postoperative complications and long-term sequelae, and how these advances have established the endoscopist as an integral member of the modern metabolic surgery team.

The metabolic surgery patient: unique challenges for the therapeutic endoscopist

Although early postoperative endoscopy following MBS is safe, patients after SG and RYGB present unique clinical and technical challenges.[3,4] Early complications include leaks, bleeding and obstruction; later problems include strictures, marginal ulceration, weight recurrence, Barrett's oesophagus after SG and difficult biliary access after RYGB. Successful management requires technical expertise together with an

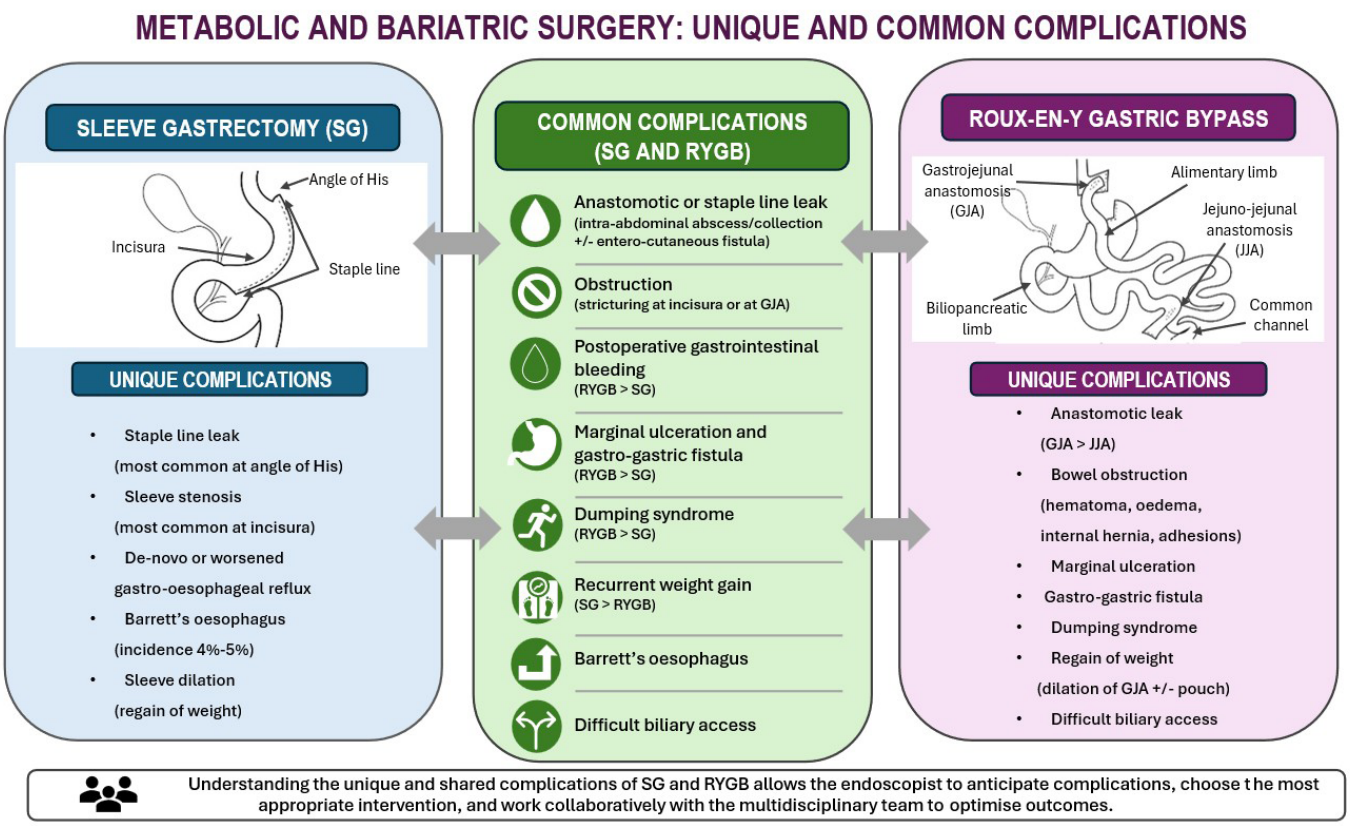

Figure 1: Anatomy and complications after sleeve gastrectomy and Roux-en-Y gastric bypass

understanding of altered anatomy, postoperative physiology and the natural history of complications (Figure 1).

Patients with severe obesity may present additional diagnostic and therapeutic challenges. Serious complications can initially manifest only as tachycardia or tachypnoea, while radiological assessment may be technically difficult or less reliable. Airway management, obstructive sleep apnoea and multiple metabolic comorbidities further complicate decision-making. Early recognition and timely multidisciplinary assessment are therefore critical.

Management has evolved from an approach centred on revisional surgery to individualised multidisciplinary care. Patients with generalised peritonitis, uncontrolled sepsis or multiorgan failure still require prompt surgery, often with radiological drainage. In physiologically stable patients, however, therapeutic endoscopy has altered the treatment paradigm achieving high clinical success while preserving surgical reconstruction and avoiding reoperation in appropriately selected patients.

Within this framework, the therapeutic endoscopist has assumed an increasingly pivotal role. Beyond diagnosis, the endoscopist provides definitive treatment through closure of leaks and fistulas, internal drainage, management of bleeding and strictures, treatment of weight recurrence and dumping syndrome, and long-term surveillance. Because many patients require staged interventions, close collaboration with surgeons, interventional radiologists, anaesthetists, dietitians and specialist nursing staff is essential.

The following sections review the principal postoperative complications after SG and RYGB and examine how advances in therapeutic endoscopy have transformed their management, establishing the endoscopist as a key contributor to both rescue and long-term care.

All endoscopic interventions should be guided by a consistent set of principles: early recognition and prompt intervention; multidisciplinary decision-making; preservation of the original operation; control of sepsis before closure; prioritisation of drainage over closure when infected collections are present; early restoration of enteral nutrition; expectation of staged or repeated interventions rather than a single procedure; and timely escalation to surgery when endoscopic therapy is unlikely to succeed or the patient is physiologically unstable (Figure 2).

The therapeutic endoscopist as the rescue specialist

Management of staple-line and anastomotic disruption

Staple-line and anastomotic disruption remain an important early complication of MBS. Management requires early recognition, control of sepsis and contamination, preservation of the surgical reconstruction and restoration of enteral nutrition. Treatment depends on timing and location of the leak, defect size, associated collection, distal obstruction and physiological status. Haemodynamic instability, generalised peritonitis or multiorgan failure remain indications for surgery; in appropriately selected stable patients, therapeutic endoscopy can frequently avoid revisional surgery.

Following SG, reported leak rates have fallen from 1–8% in older series to approximately 0.3–1.5% in recent meta-analyses.[5,6] Most occur at the angle of His, with distal sleeve narrowing and increased intraluminal pressure contributing to persistence. Diabetes, chronic kidney disease, steroid use and smoking are additional risk factors. After RYGB,

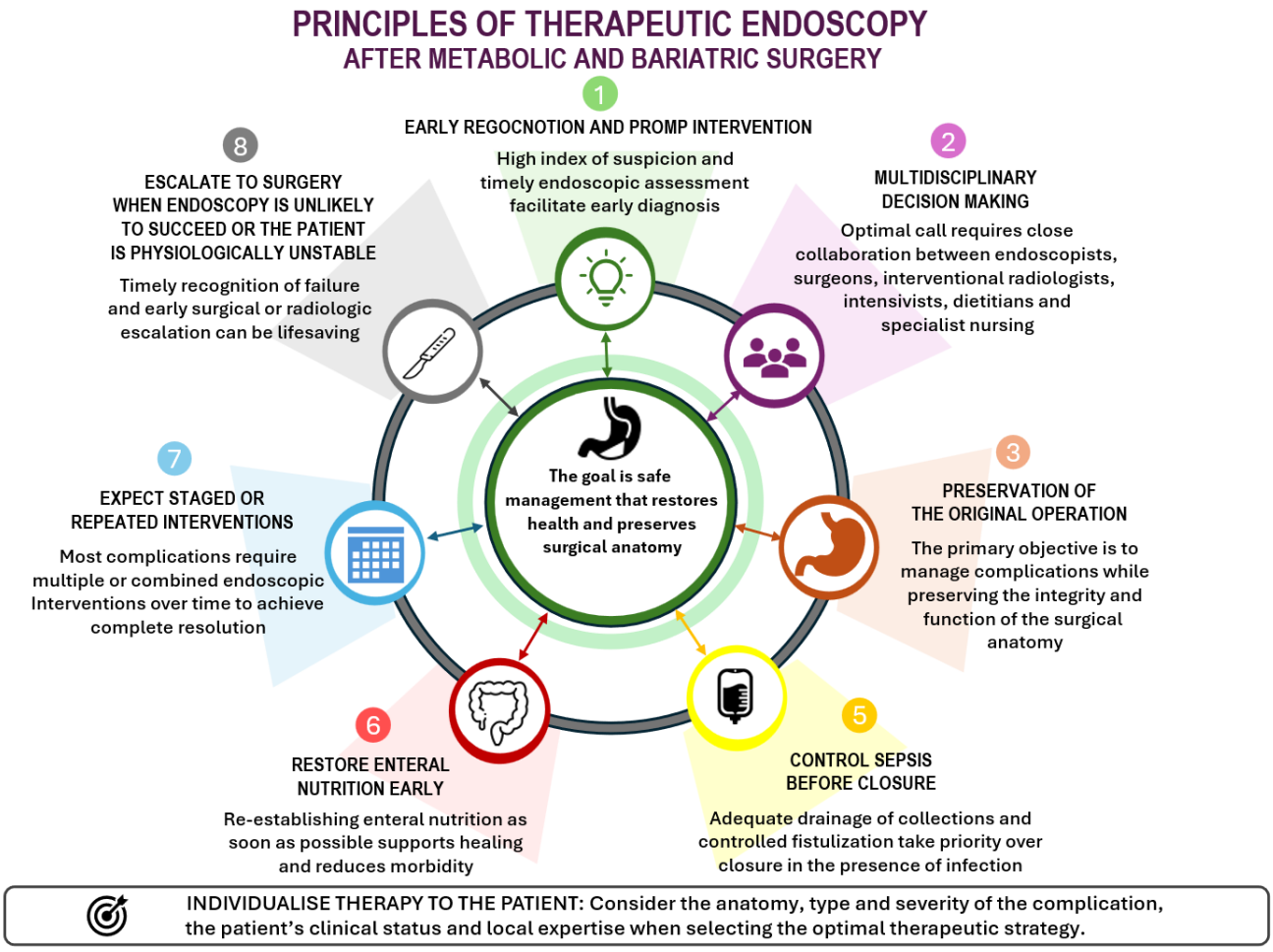

Figure 2: Principles of therapeutic endoscopy after metabolic and bariatric surgery

the gastrojejunal anastomosis is the most common site, usually related to anastomotic tension and exposure to gastric secretions; jejuno-jejunal leaks are less common but technically more difficult to access.[7]

Endoscopic assessment defines the location and size of the defect, tissue viability and chronicity, distal obstruction and the presence of a collection.[8] These findings determine whether the priority should be diversion, closure, drainage or a combination. Closure should not be regarded as the sole goal: when an infected or poorly drained collection is present, effective drainage and source control take precedence.

Endoscopic stenting

Self-expanding metal stents (SEMS) divert enteric contents and reduce intraluminal pressure. Longer, larger-diameter bariatric stents were developed to cover leaks and potentially relieve distal sleeve narrowing, but comparative studies have not consistently shown superiority over conventional covered oesophageal stents.[9,10] For SG leaks, stents generally extend from the distal oesophagus beyond the incisura and, selectively, across the pylorus.[11] Migration remains the major limitation, occurring in up to 40–60% of SG cases. Fixation with sutures or clips may reduce migration but can complicate removal and cause tissue injury.[4,12] Reflux, nausea and vomiting are common; nasojejunal feeding should be considered when oral intake is inadequate.

Systematic evidence suggests clinical success of approximately 72.8% for SG leaks and 76.1% for RYGB leaks.[13] Stenting remains effective for diversion, but tolerance, migration and the likelihood of repeated procedures must be considered.

Endoscopic closure

Direct closure includes tissue sealants, over-the-scope clips (OTSCs) and full-thickness endoscopic suturing. Tissue adhesives are generally suited to small fistulas, while OTSCs and suturing are used for larger or well-defined defects. Meta-analytic evidence shows variable outcomes, emphasising careful selection.[8,11]

Defect characteristics and chronicity are critical. Acute leaks with healthy tissue may be amenable to direct closure, whereas chronic epithelialised fistulas are more difficult to close. OTSCs may suit smaller defects, while suturing can be useful for larger ones; tissue preparation or combined techniques may improve closure in selected chronic fistulas.[10]

Closure should never substitute for source control. An undrained infected collection should be treated before definitive closure.

Endoscopic drainage

Effective drainage is often more important than immediate closure. Periluminal collections can be treated with endoscopic vacuum therapy (EVT), transmural double-pigtail drainage or, in selected chronic sleeve leaks,

septotomy. The aim is to control contamination, drain infection and establish controlled internal drainage while the defect heals.

EVT places a polyurethane sponge within the lumen or leak cavity and applies continuous negative pressure to reduce contamination and oedema and promote granulation.[14] Repeated exchanges are usually required.[15] A meta-analysis reported 87.2% clinical success with EVT, with adverse events in 6%; a mean 6.47 exchanges were required at approximately 4.4-day intervals, with dislodgement in 12.5%.[16] Comparative evidence suggests EVT may be more effective than conventional stenting for upper gastrointestinal transmural defects, although evidence remains heterogeneous.[17]

Transmural double-pigtail drainage is particularly useful when a well-defined collection is accessible from the gastric lumen.[11] A meta-analysis found similar pooled closure rates for pigtail drainage and EVT (91.6% vs 85.2%), but treatment duration was longer with pigtail drainage (approximately 78 vs 28 days).[18]

Endoscopic septotomy provides internal drainage for selected chronic SG leaks by dividing the fibrous septum between the lumen and mature cavity.[10] It is most useful when a well-defined cavity is present without significant distal stenosis.

These approaches demonstrate that no single procedure is universally appropriate. Pigtail drainage, EVT and septotomy can achieve success rates approaching 90% in selected patients, but treatment should be tailored to anatomy, chronicity, collections, distal obstruction and clinical status. Staged or repeated drainage, debridement, stenting or closure may be necessary.[10]

Management is therefore a coordinated process rather than a choice between devices. Early recognition, multidisciplinary assessment, source control, preservation of reconstruction, nutritional support and repeated intervention when required are central. Surgery remains essential for instability, uncontrolled sepsis or anatomy unsuitable for endoscopic therapy; in selected stable patients, endoscopy increasingly provides effective anatomy-preserving treatment with an overall clinical success rate of 88%.[19]

Management of postoperative gastrointestinal bleeding

Gastrointestinal bleeding may occur early or late after MBS. Following RYGB, early bleeding commonly arises from the gastrojejunal or jejuno-jejunal anastomosis; after SG, staple-line bleeding more often occurs into the peritoneal cavity. Later bleeding after RYGB is mostly related to marginal ulceration.

Endoscopy provides localisation and definitive treatment in appropriately selected patients.[20] Mechanical haemostasis with clips may be advantageous for early postoperative bleeding because it can permit earlier resumption of pharmacological thromboprophylaxis when thromboembolic risk remains high.

Marginal ulceration may present with bleeding, perforation or stricture. Endoscopic therapy may provide haemostasis and, in refractory cases, selected intervention such as endoscopic suturing.[21] The therapeutic endoscopist must therefore recognise the underlying structural problem and plan subsequent treatment when ulceration leads to fistula or stricture.

Management of postoperative strictures

Postoperative strictures are important late complications of SG and RYGB. After SG, stenosis most often occurs at the incisura and may create a high-pressure zone with reflux and proximal sleeve dilatation. After RYGB, stricturing usually occurs at the gastrojejunal anastomosis and may reflect the original configuration or scarring from marginal ulceration.

Endoscopy should define the site and severity of narrowing and identify associated ulceration, angulation or downstream obstruction. Treatment is generally staged and tailored to the anatomy and cause.

For SG strictures, staged treatment may begin with radial expansion and progress to pneumatic dilation, with target diameters of approximately 20 mm initially and 30–35 mm subsequently.[11] A meta-analysis of 28 studies involving 1 000 patients reported a pooled response of approximately 78%, with a mean 1.82 dilations; subsequent stenting and surgery were required in 19.3% and 16%, respectively.[22]

Gastrojejunal strictures after RYGB generally respond to balloon dilation, with a target diameter of approximately 12 mm; about 38% require a second dilation.[23] Guidewire-assisted technique is important in the potentially angulated Roux limb, with a reported overall complication rate of approximately 3–4%.[23] Larger diameters should be approached cautiously because of perforation risk and potential loss of restriction.[11]

Strictures associated with marginal ulceration are more difficult to treat and carry greater perforation risk.[22] Conventional SEMS have inconsistent results, while lumen-apposing metal stents (LAMS) have shown encouraging early success in selected refractory gastrojejunal strictures, although evidence remains limited and does not support routine use.[24,25]

Successful treatment therefore depends on addressing the cause of the narrowing rather than simply enlarging the lumen. Repeated endoscopic therapy is often preferable to immediate revisional surgery when anatomy remains suitable and the patient can be managed safely.

Management of gastro-gastric fistula

Gastro-gastric fistula is an uncommon late consequence of a contained leak or perforation after RYGB. Re-establishment of communication between the pouch and excluded stomach can reduce the restrictive and metabolic effects of bypass and may present with recurrent weight gain.

Management requires characterisation of the tract and surrounding tissue. Conventional clips are often unsuccessful; larger defects may be treated with OTSCs or endoscopic suturing, although long-term success with suturing alone is modest at approximately 30–35%.[11] Chronic epithelialised fistulas may benefit from argon plasma coagulation or submucosal dissection before closure.

Endoscopic versus surgical treatment should be individualised according to fistula size, chronicity, tissue quality, ulceration and patient factors. OTSC placement may complicate subsequent laparoscopic revision, making close communication between endoscopist and surgeon essential.

The therapeutic endoscopists role in the long-term management of the obese patient

Endoscopic management of weight recurrence and dumping syndrome

The endoscopist's role now extends to long-term management of weight recurrence and dumping syndrome. Weight recurrence is increasingly viewed as part of the postoperative trajectory rather than simply failure of the original operation. The 2024 IFSO (International Federation for the Surgery and Other Therapies for Obesity) consensus defines recurrent weight gain as an increase of > 30% of maximum total weight loss, or significant worsening of an obesity-related complication; suboptimal response is weight loss < 20% or inadequate improvement in an obesity-related complication.[26]

Mechanisms differ by procedure: sleeve dilatation may reduce restriction after SG, while enlargement of the gastrojejunal outlet after RYGB may reduce satiety, accelerate emptying and contribute to dumping. Weight regain exceeding 10% has been reported in approximately 17.6% of patients after RYGB and SG, with longer-term randomised data suggesting greater recurrence after SG.[27]

Management should be multidisciplinary and include dietary, metabolic and pharmacological assessment. Endoscopy is most useful when an anatomical target is present. After SG, endoscopic sleeve-in-sleeve (SIS) has emerged as a less invasive alternative to surgical conversion or re-sleeve. A 2026 propensity-matched cohort reported similar one-year weight loss to surgery, although confirmation in larger multicentre studies is needed.[28]

After RYGB, transoral outlet reduction (TORe) is the principal endoscopic revisional intervention for an enlarged gastrojejunal anastomosis. By reducing outlet diameter with endoscopic suturing, TORe restores restriction and slows pouch emptying.[29] TORe can generally be performed as a minimally invasive day-case procedure with lower morbidity than surgical revision. A 2025 ASGE-associated meta-analysis reported approximately 9.5% weight loss at one year, increasing to 12.8% with a purse-string technique; pooled clinical success for dumping syndrome was approximately 83%.[29,30] Adjunctive mucosal ablation may enhance tissue remodelling.

Endoscopic revision therefore represents a shift from automatic surgical revision towards individualised assessment of anatomy, metabolic factors, behaviour and medical therapy. The therapeutic endoscopist has become part of long-term obesity management rather than simply a provider of rescue therapy.

Long-term surveillance and management of altered anatomy

The endoscopist's role continues beyond postoperative complications. Long-term surveillance and management of altered gastrointestinal anatomy are increasingly important components of care after MBS.

Barrett's oesophagus after sleeve gastrectomy

Sleeve gastrectomy can worsen gastro-oesophageal reflux and is associated with Barrett's oesophagus, with an estimated prevalence of approximately 4.6%; the extent to which SG increases oesophageal adenocarcinoma risk remains uncertain.[31]

Endoscopic surveillance is therefore an important long-term role. Current recommendations support screening after SG, with subsequent intervals determined by findings.[31] The endoscopist should assess reflux injury and anatomy and ensure appropriate surveillance or treatment when dysplasia is identified.

Biliary access after Roux-en-Y gastric bypass

Altered anatomy after RYGB creates a distinctive challenge when biliary disease develops. Rapid weight loss increases gallstone risk, while the excluded stomach and Roux limb make conventional endoscopic retrograde cholangiopancreatography (ERCP) difficult or impossible.[32]

Options include laparoscopic-assisted ERCP, device-assisted enteroscopy and EUS-directed transgastric ERCP (EDGE). EDGE creates temporary access between the pouch and excluded stomach with a LAMS, allowing use of a conventional duodenoscope.

EDGE has reported technical success of approximately 96%, but timing must balance early stent dislodgement against persistent fistula if the tract is allowed to mature. A recent meta-analysis reported dislodgement in approximately 7%, persistent fistula in 17% and subsequent weight regain in about 4%.[33] These risks must be weighed against the morbidity of alternative surgical approaches.

Biliary management after RYGB therefore exemplifies the broader role of the therapeutic endoscopist in altered anatomy: advanced techniques can provide access to otherwise inaccessible organs and permit complex therapy while avoiding major revisional surgery.

Conclusion

Therapeutic endoscopy has transformed the management of patients undergoing metabolic and bariatric surgery. High clinical success rates for leaks and other postoperative complications now allow many appropriately selected patients to be treated without repeat surgery, while preserving the original reconstruction. Its role has subsequently expanded to include strictures, gastro-gastric fistulas, weight recurrence, dumping syndrome, Barrett's surveillance and biliary intervention in altered anatomy.

Many of these interventions are staged and require close collaboration between the therapeutic endoscopist, bariatric surgeon and wider multidisciplinary team. The endoscopist should therefore no longer be regarded simply as a proceduralist called upon when complications arise, but as an integral member of the metabolic surgery team. The future of care lies in early recognition, anatomy-preserving intervention and appropriate escalation to surgery when endoscopic therapy is unlikely to succeed. As therapeutic techniques continue to evolve, the integration of advanced endoscopy into metabolic bariatric programmes will be increasingly important to achieving safe, effective and durable outcomes.

Conflict of interest

The author declares no conflict of interest.

ORCID

JA Lubbe https://orcid.org/0000-0001-8397-8685

REFERENCES

1. World Obesity Atlas 2025. World Obesity Federation. Available from: https://www.worldobesity.org/resources/resource-library/world-obesity-atlas-2025. Accessed 1 August 2026.
2. Hany M, Torensma B, Zidan MH, et al. Trends and evolution of metabolic bariatric surgery over a decade: Analysis of IFSO global registry reports' data collection, clinical trends, and a FAIR-informed appraisal of report-level transparency. eClinicalMedicine. 2026;97. https://doi.org/10.1016/j.eclinm.2026.104068.
3. Sharma G, Ardila-Gatas J, Boules M, et al. Upper gastrointestinal endoscopy is safe and feasible in the early postoperative period after Roux-en-Y gastric bypass. Surgery. 2016;160(4):885-91. https://doi.org/10.1016/j.surg.2016.07.001.
4. Birda CL, Dhar J, Kumar N, et al. Endoscopic management for gastrointestinal leaks, perforations, and fistulae: Technical tips and outcomes. World J Gastrointest Endosc. 2025;17(12):111782. https://doi.org/10.4253/wjge.v17.i12.111782.
5. Ma L, Gao Z, Luo H, et al. Comparison of the postoperative outcome with and without intraoperative leak testing for sleeve gastrectomy: A systematic review and meta-analysis of 469 588 cases. Int J Surg. 2024;110(2):1196-205. https://doi.org/10.1097/JS9.0000000000000919.
6. Gagner M, Kemmeter P. Comparison of laparoscopic sleeve gastrectomy leak rates in five staple-line reinforcement options: A systematic review. Surg Endosc. 2020;34(1):396-407. https://doi.org/10.1007/s00464-019-06782-2.
7. Lee S, Carmody B, Wolfe L, et al. Effect of location and speed of diagnosis on anastomotic leak outcomes in 3828 gastric bypass cases. J Gastrointest Surg Off J Soc Surg Aliment Tract. 2007;11(6):708-13. https://doi.org/10.1007/s11605-007-0085-3.
8. Doyle WN, Netzley A, Mhaskar R, et al. Endoscopic closure techniques of bariatric surgery complications: A meta-analysis. Surg Endosc. 2024;38(5):2894-9. https://doi.org/10.1007/s00464-024-10799-7.
9. Hamid HKS, Emile SH, Saber AA, et al. Customised bariatric stents for sleeve gastrectomy leak: Are they superior to conventional oesophageal stents? A systematic review and proportion meta-analysis. Surg Endosc. 2021;35(3):1025-38. https://doi.org/10.1007/s00464-020-08147-6.
10. Galloro G, Giglio MC, Chini A, et al. Endoscopic treatment of staple-line leaks after sleeve gastrectomy in patients with obesity: Which one is the best option, if any? A systematic review with meta-analysis and meta-regression. Obes Surg. 2025;35(12):5496-514. https://doi.org/10.1007/s11695-025-08294-6.
11. Schulman AR, Watson RR, Abu Dayyeh BK, et al. Endoscopic devices and techniques for the management of bariatric surgical adverse events (with videos). Gastrointest Endosc. 2020;92(3):492-507. https://doi.org/10.1016/j.gie.2020.04.002.
12. Law R, Prabhu A, Fujii-Lau L, Shannon C, Singh S. Stent migration following endoscopic suture fixation of oesophageal self-expandable metal stents: A systematic review and meta-analysis. Surg Endosc. 2018;32(2):675-81. https://doi.org/10.1007/s00464-017-5720-9.
13. Okazaki O, Bernardo WM, Brunaldi VO, et al. Efficacy and safety of stents in the treatment of fistula after bariatric surgery: A systematic review and meta-analysis. Obes Surg. 2018;28(6):1788-96. https://doi.org/10.1007/s11695-018-3236-6.
14. Schmidt F, Mennigen R, Vowinkel T, et al. Endoscopic vacuum therapy (EVT): A new concept for complication management in bariatric surgery. Obes Surg. 2017;27(9):2499-505. https://doi.org/10.1007/s11695-017-2783-6.
15. Archid R, Wichmann D, Klingert W, et al. Endoscopic vacuum therapy for staple line leaks after sleeve gastrectomy. Obes Surg. 2020;30(4):1310-5. https://doi.org/10.1007/s11695-019-04269-6.
16. Intriago JMV, de Moura DTH, do Monte Junior ES, et al. Endoscopic vacuum therapy (EVT) for the treatment of post-bariatric surgery leaks and fistulas: A systematic review and meta-analysis. Obes Surg. 2022;32(10):3435-51. https://doi.org/10.1007/s11695-022-06228-0.
17. Do Monte Junior ES, de Moura DTH, Ribeiro IB, et al. Endoscopic vacuum therapy versus endoscopic stenting for upper gastrointestinal transmural defects: Systematic review and meta-analysis. Dig Endosc Off J Jpn Gastroenterol Endosc Soc. 2021;33(6):892-902. https://doi.org/10.1111/den.13813.
18. Laopeamthong I, Akethanin T, Kasetsermwiriya W, Techapongsatorn S, Tansawet A. Vacuum therapy and internal drainage as the first-line endoscopic treatment for post-bariatric leaks: A systematic review and meta-analysis. Visc Med. 2022;38(1):63-71. https://doi.org/10.1159/000518946.
19. Minakari M, Sebghatollahi V, Namaki M. Success rate of endoscopic treatment for post-sleeve gastrectomy leaks: A systematic review and meta-analysis. Obes Surg. 2025;35(8):3228-40. https://doi.org/10.1007/s11695-025-08014-0.
20. Barola S, Magnuson T, Schweitzer M, et al. Endoscopic suturing for massively bleeding marginal ulcer 10 days post Roux-en-Y gastric bypass. Obes Surg. 2017;27(5):1394-6. https://doi.org/10.1007/s11695-017-2621-x.
21. Salame M, Jawhar N, Belluzzi A, et al. Marginal ulcers after Roux-en-Y gastric bypass: Aetiology, diagnosis, and management. J Clin Med. 2023;12(13):4336. https://doi.org/10.3390/jcm12134336.
22. Eguchi M, Nogueira R, Balthazar da Silveira CA, et al. Endoscopic management of gastric stenosis after sleeve gastrectomy: A systematic review and single-arm meta-analysis. Surg Endosc. 2025;39(8):5324-47. https://doi.org/10.1007/s00464-025-11843-w.
23. Baumann AJ, Mramba LK, Hawkins RB, et al. Endoscopic dilation of bariatric RNY anastomotic strictures: A systematic review and meta-analysis. Obes Surg. 2018;28(12):4053-63. https://doi.org/10.1007/s11695-018-3491-6.
24. Bazerbachi F, Heffley JD, Abu Dayyeh BK, et al. Safety and efficacy of coaxial lumen-apposing metal stents in the management of refractory gastrointestinal luminal strictures: A multicentre study. Endosc Int Open. 2017;5(9):E861-E867. https://doi.org/10.1055/s-0043-114665.
25. Puig CA, Waked TM, Baron TH, Wong Kee Song LM, Gutierrez J, Sarr MG. The role of endoscopic stents in the management of chronic anastomotic and staple line leaks and chronic strictures after bariatric surgery. Surg Obes Relat Dis Off J Am Soc Bariatr Surg. 2014;10(4):613-7. https://doi.org/10.1016/j.soard.2013.12.018.
26. Salminen P, Kow L, Aminian A, et al. IFSO consensus on definitions and clinical practice guidelines for obesity management: An international Delphi study. Obes Surg. 2024;34(1):30-42. https://doi.org/10.1007/s11695-023-06913-8.

27. Athanasiadis DI, Martin A, Kapsampelis P, Monfared S, Stefanidis D. Factors associated with weight regain post-bariatric surgery: A systematic review. Surg Endosc. 2021;35(8):4069-84. https://doi.org/10.1007/s00464-021-08329-w.
28. Jirapinyo P, Siranart N, Thompson CC. Endoscopic versus surgical management of recurrent weight gain following sleeve gastrectomy. Gastrointest Endosc. 2026;103(6):1173-9. https://doi.org/10.1016/j.gie.2025.11.004.
29. Beran A, Ramai D, Albakri A, et al. Transoral outlet reduction for dumping syndrome after Roux-en-Y gastric bypass: A comprehensive systematic review and meta-analysis. Obes Surg. 2025;35(11):4620-7. https://doi.org/10.1007/s11695-025-08275-9.
30. Jirapinyo P, Kumar N, Thompson CC, et al. Association for Bariatric Endoscopy systematic review and meta-analysis assessing the American Society for Gastrointestinal Endoscopy preservation and incorporation of valuable endoscopic innovations thresholds for transoral outlet reduction. Gastrointest Endosc. 2025;102(4):440-53.e6. https://doi.org/10.1016/j.gie.2025.05.020.
31. Fisher OM, Chan DL, Talbot ML, et al. Barrett's oesophagus and bariatric/metabolic surgery - IFSO 2020 Position Statement. Obes Surg. 2021;31(3):915-34. https://doi.org/10.1007/s11695-020-05143-6.
32. Enestvedt BK, Kothari S, Pannala R, et al.; ASGE Technology Committee. Devices and techniques for ERCP in the surgically altered GI tract. Gastrointest Endosc. 2016;83(6):1061-75. https://doi.org/10.1016/j.gie.2016.03.018.
33. Deliwala SS, Mohan BP, Yarra P, et al. Efficacy and safety of EUS-directed transgastric endoscopic retrograde cholangiopancreatography (EDGE) in Roux-en-Y gastric bypass anatomy: A systematic review and meta-analysis. Surg Endosc. 2023;37(6):4144-58. https://doi.org/10.1007/s00464-023-09926-7.