SAJS
Case Report

Buccal fat pad – a simple, underutilised flap

E. Meyer, M.B. Ch.B., F.C.O.R.L. (S.A.)
S. J. R. Liebenberg, M.B. Ch.B., M.R.C.S. (Ed.), F.C.O.R.L. (S.A.)
J. J. Fagan, M.B. Ch.B., M.Med., F.C.O.R.L. (S.A.)
Division of Otolaryngology, Faculty of Health Sciences, University of Cape Town and Groote Schuur Hospital

Summary

The pedicled buccal fat pad is a reliable flap for the repair of small oral defects. It is durable, easy to harvest, and should be considered in settings where access to free flaps is limited and in cases where previous flaps have failed. We discuss a case in which this flap was used successfully for closure of an oro-antral fistula. The indications, anatomy and techniques of successful harvest are discussed.

S Afr J Surg 2012;50(2):47-49.

A 57-year-old woman presented in 1998 with a benign minor salivary gland tumour of the hard palate. A wide local excision of the tumour was performed. The excision margins extended onto the palatal bone, but no bone was excised. The greater palatine artery was ligated and the bone was left to re-epithelialise spontaneously. Two years later, she again had a benign palatal lesion which was excised. The surgery resulted in an oro-antral fistula.

In 2007 she was symptomatic, with all fluids coming through her nose when drinking. A local gingival mucosal rotational flap was done without success. Three months later, a pedicled buccal fat pad was electively used to close this defect (Fig. 1). The edges of the defect were debrided to healthy/fresh margins, and the buccal fat pad was dissected and draped over the defect and secured with vicryl sutures (Fig. 2).

The patient was seen 1 month later (Fig. 3); she had no complaints and could wear her dentures comfortably.

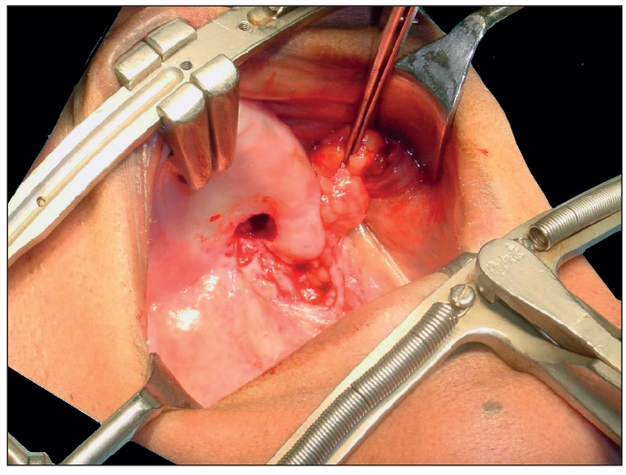

Fig. 1. Oro-antral fistula and mobilised buccal fat pad.

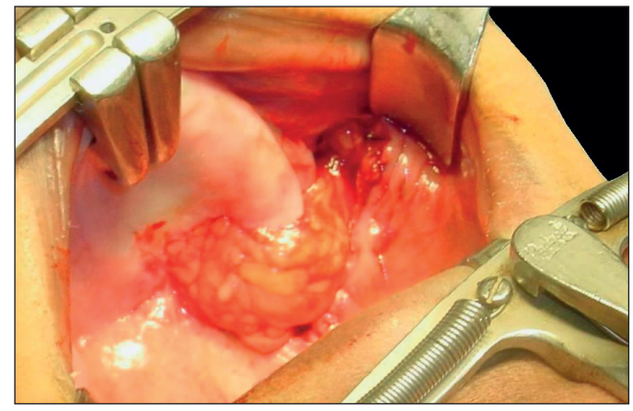

Fig. 2. Buccal fat pad sutured to cover the oro-antral fistula.



Fig. 3. The patient, 1 month later, was very happy with the result, and had no problems eating or inserting dentures.

The buccal fat pad flap

The buccal fat pad flap is an axial flap. The pad was first described 300 years ago and was considered a nuisance by surgeons for many years because of its accidental encounter during various operations in the pterygomandibular region.[1] Egyedi[2] was the first to report (in 1977) the use of a pedicled buccal fat pad as a flap for closure of post-surgical maxillary defects. Since then, it has become a recognised option for the reconstruction of small- to medium-sized soft tissue and bony defects in the oral cavity. When precisely dissected and mobilised, the buccal fat pad provides a 7x4x3 cm pedicled graft.[1]

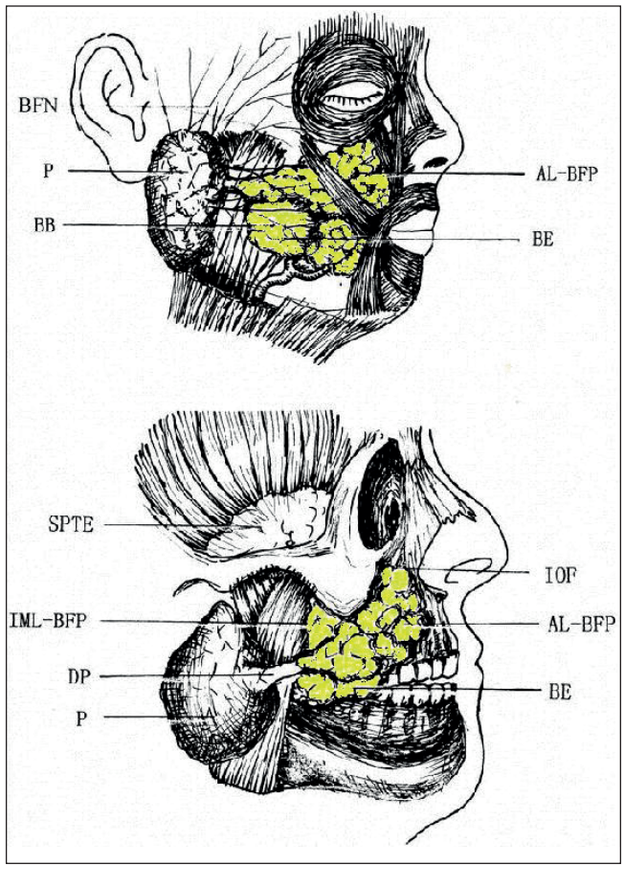

Fig. 4. Top: In this child, the buccal branches (BB) of the facial nerve are seen to cross superficial to the anterior lobe of the buccal fat pad (AL-BFP) and the buccal extension (BE). The zygomaticus major muscle crosses the anterior lobe (Zhang et al.[4]*).*

Bottom: Anterior lobe in an adult. The parotid duct (DP) and anterior facial vein traverse the anterior lobe. The buccal extension is located below the parotid duct and lies posteriorly on the surface of the masseter. The fatty tissue covering the duct is less than that in children. Medially and superiorly, the anterior lobe encapsulates the infra-orbital vessels and enters the infra-orbital foramen (IOF); P = parotid; IML-BFP, = intermediate lobe; SPTE = superficial part of the temporal extension (Zhang et al.[4]*).*

Anatomy (Fig. 4)

- The buccal fat pad is an encapsulated, rounded, biconvex, specialised fatty tissue which is distinct from subcutaneous fat.[3]
- The buccal fat pad fills the deep tissue spaces, acts as gliding pads when masticatory and mimetic muscles contract, and cushions important structures from the forces generated by muscle contraction.
- The volume of the fat pad changes throughout life. It has a body located behind the zygomatic arch.
- The buccal fat pad is attached by 6 ligaments to the maxilla, posterior zygoma, and inner and outer rims of the infra-orbital fissure, temporalis tendon and buccinator membrane.
- Four processes (buccal, pterygoid, superficial and deep temporal) extend from the body to surrounding tissue spaces e.g. the pterygomandibular and infratemporal spaces.
- The parotid duct passes along the lateral surface of the buccal fat pad or penetrates the body of the fat pad before it opens on the buccinator muscle.

The body is divided into 3 lobes – anterior, intermediate and posterior, in accordance with the structure of the lobar envelopes, the ligaments and the source of the nutritional vessels.

- The **anterior lobe** is located below the zygoma, extending to the front of the buccinator, maxilla and the deep space of the quadrate muscle of the upper lip and zygomaticus major muscle. The canine muscle originates from the infraorbital foramen and passes through the medial part of the anterior lobe. The parotid duct passes through the posterior part, and the anterior facial vein passes through the antero-inferior margin. The anterior lobe also envelops the infra-orbital vessels and nerve, and together enters the infra-orbital canal. The branches of the facial nerve lie on the outer surface of the capsule.
- The **intermediate lobe** lies in and around the posterior lobe, lateral maxilla and anterior lobe. It is a membrane-like structure with thin fatty tissue in adults, but is a large mass in children.
- The **posterior lobe** is situated in the masticatory and neighbouring spaces. It extends up to the infra-orbital fissure and surrounds the temporalis muscle, and extends down to the superior rim of the mandibular body, and back to the anterior rim of the temporalis tendon and ramus. In doing so, it forms the buccal, pterygopalatine and temporal processes.

Feeding vessels

The buccal fat flap is an axial flap. The facial artery, transverse facial vessel and the internal maxillary artery as well as their anastomosing branches enter the fat tissue and form a lobar subcapsular vascular plexus by anastomosing with each other.

Indications

- Reconstruction of small to medium (<5 cm) acquired or congenital soft-tissue and bone defects in the oral cavity, e.g. oro-nasal and oro-antral communications following dental extraction; surgical defects following tumour excision and excision of leukoplakia and submucous fibrosis; and primary and secondary palatal cleft.
- Coverage of maxillary and mandibular bone grafts.
- Alternative or backup for failed buccal advancement flaps, palatal rotation and transposition flaps, tongue and nasolabial flaps.

Surgical steps

1. If done under local anaesthesia: 2% lignocaine with adrenaline (1:80 000).
2. Three approaches:
   2.1 Incise buccal mucosal membrane 1 cm below opening of parotid duct (Matarasso's method).
   2.2 Incise behind opening of parotid duct (Stuzin's method).
   2.3 Incise in superior gingivobuccal sulcus.
3. Bluntly dissect sub-mucosal tissues until the buccal fat pad is found.
4. Incise the capsule of buccal pad.
5. Gently deliver required volume of buccal fat tissue into oral cavity.
6. Take care not to injure inferior buccinator branches of facial artery to prevent haematoma.

7. Freshen edges of defect to be grafted.
8. Position buccal fat flap in defect and secure with absorbable sutures.
9. Cover flap with mucosa if possible.
10. Full epithelialisation normally occurs in 1 month.

Complications

Complications are very rare (3 - 7%), and comprise postoperative infection, partial necrosis, excessive scarring and granulation, and sulcus obliteration.

Advantages

- Ease of harvesting
- Simplicity
- Versatility
- Low complication rate
- Can be done under local anaesthesia
- Quick surgical technique
- Fat pad located in the same surgical field as the defect
- Minimal donor site morbidity.[5]

Conclusions

The pedicled buccal fat pad is a reliable flap for the repair of small oral defects and, as in our case, oro-antral fistulae. The easy mobilisation of the buccal fat pad and its excellent blood supply and minimal donor site morbidity make it an ideal flap for such indications. Radiotherapy does not seem to influence the success of reconstruction. It is advisable to begin radiotherapy once flap epithelialisation is complete. This flap can also be used on a previously irradiated bed without problems.[5] It should be considered as a reliable back-up procedure in the event of failure of other techniques.

REFERENCES

1. Rapidis AD, Alexandridis CA, Eleftheriadis E, et al. The use of the buccal fat pad for reconstruction of oral defects: Review of the literature and report of 15 cases. J Oral Maxillofac Surg 2000;58(2):158-163.
2. Egyedi P. Utilization of the buccal fat pad for closure of oro-antral and/or oro-nasal communications. J Craniomaxillofac Surg 1977;5:241.
3. Liversedge RL, Wong K. Use of the buccal fat pad in maxillary and sinus grafting of the severely atrophic maxilla preparatory to implant reconstruction of the partially or completely edentulous patient: Technical note. Int J Oral Maxillofac Implants 2002;17:424-428.
4. Zhang H, Yan Y, Qi K, Wang J, Liu Z. Anatomical structures of the buccal fat pad and its clinical adaptation. Plast Reconstr Surg 2002;109(7):2509-2518.
5. Dean A, Alamillos F, Garcia-Lopez A, Sanchez J, Penalba M. The buccal fat pad in oral reconstruction. Head Neck 2001;23(5):383-388.