SA Journal of Oncology
ISSN: (Online) 2523-0646, (Print) 2518-8704

Extrarenal Wilms tumour: A rare cause for retroperitoneal mass in children

Check for updates

Authors:
Leilah Schoonraad[1]
Anel van Zyl[1]
Bob Banieghbal[2]
Pawel Schubert[3]

Affiliations:
[1]Department of Paediatric Oncology, Faculty of Paediatrics and Child Health, Stellenbosch University, Cape Town, South Africa

[2]Department of Paediatric Surgery, Faculty of Surgery, Stellenbosch University, Cape Town, South Africa

[3]Department of Anatomical Pathology, Faculty of Anatomical Pathology, Stellenbosch University, Cape Town, South Africa

Corresponding author:
Leilah Schoonraad,
leilah@sun.ac.za

Dates:
Received: 17 Sept. 2025
Accepted: 13 May 2026
Published: 14 July 2026

How to cite this article:
Schoonraad L, Van Zyl A, Banieghbal B, Schubert P. Extrarenal Wilms tumour: A rare cause for retroperitoneal mass in children. S. Afr. j. oncol. 2026; 10(0), a352. https://doi.org/10.4102/sajo.v10i0.352

Copyright:
© 2026. The Authors. Licensee: AOSIS. This work is licensed under the Creative Commons Attribution 4.0 International (CC BY 4.0) license (https://creativecommons.org/licenses/by/4.0/).

Read online:
Scan this QR code with your smart phone or mobile device to read online.

Nephroblastoma (Wilms tumour) is one of the most common paediatric solid tumours, with a prevalence of 5% globally and 13.5% in South Africa. However, extrarenal Wilms tumour (ERWT) is a rare disease, and fewer than 100 cases have been reported in the paediatric age group.

Contribution: In this report, we present the first reported case of extrarenal Wilms tumour, presenting as a retroperitoneal mass to a Paediatric Oncology Unit in South Africa.

Keywords: nephroblastoma; Wilms tumour; extrarenal Wilms tumour; retroperitoneal mass; cytopathology; immunohistochemisty Wilms tumour.

Introduction

Wilms tumour (WT), arising almost exclusively from the kidneys, represents around 95% of paediatric renal tumours.[1,2,3] The rare occurrence of extrarenal Wilms tumour (ERWT) with no evidence of kidney involvement was first reported by Moyson et al. in 1961 and accounts for 0.5% – 1% of WT diagnoses.[4] Extrarenal Wilms tumour most often develops in the retroperitoneum and inguinal regions. However, it can arise from various sites, including the female genital organs, mediastinum, pelvis, adrenal gland, bladder, prostate, scrotum, testis, lumbosacral region, paravertebral soft tissue and spinal intravertebral foramina or canal. The most accredited pathogenic hypothesis is that ERWT arises in ectopic nephrogenic rests anywhere along the craniocaudal migration pathway of the primitive mesonephros and metanephros cells.[2]

Case report

Clinical presentation

A 2-year-and-11-month-old boy, previously well, presented to a regional hospital with acute gastroenteritis. A left-sided abdominal mass was incidentally found. There was no history of haematuria, fever or abdominal pain. His weight trend showed a plateau in growth. The family history was negative for any relevant diseases, including malignancies and congenital malformations. He was born at term with a normal birthweight, and had received all childhood immunisations.

On clinical examination, the boy was well-looking. He was hypertensive (140/90 mmHg), and the urine dipstick was normal. No dysmorphic features or scalp or skin lesions were visible, and he had a normal nutritional status. There was a large, firm abdominal mass (8 cm × 8 cm) in the left upper quadrant extending into the left lower quadrant and flank, and the mass was not ballotable. The remainder of the clinical examination was unremarkable. The blood investigations revealed a normal full blood count and renal and liver functions, negative HIV status, elevated lactate dehydrogenase (310 U/L; normal 110 U/L – 295 U/L), normal ferritin (14 ug/L; normal 6 ug/L – 67 ug/L) and raised C-reactive protein (38 mg/L; normal <10 mg/L). Urine samples were sent for vanillylmandelic acid and homovanillic acid as a screen for neuroblastoma, but these tests were unavailable at the local laboratory. Other tumour markers such as alpha-fetoprotein or beta-human chorionic gonadotropin hormone were not done at the time of presentation.

Imaging

An abdominal sonar done at the base hospital showed two normal kidneys (right 6.5 cm and left 6.6 cm). A large irregular solid mass with cystic components was noted medial and distal to the left kidney. The lower pole of the left kidney was deemed to be separate from the mass. The patient was transferred to our paediatric oncology unit for further investigation, where a magnetic resonance imaging (MRI) abdomen scan was done.

The computed tomography (CT) scan of the chest showed no abnormalities. The images were presented at a multidisciplinary tumour board meeting, where it was agreed that the mass was compressing the left kidney but did not arise from it (no claw sign was seen). It was approximately 50% solid and cystic. The radiologic differential diagnosis included teratoma, rhabdomyosarcoma, sarcoma and lymphangioma.

Pathological examination

As the MRI could not identify a clear origin of the mass, a pre-treatment fine needle aspiration biopsy (FNAB) via a retroperitoneal approach was performed. This showed that the mass was morphologically compatible with WT. All three components of WT (epithelium, stroma and blastema) were present.

There were no obvious features of anaplasia, but there was some variation in nuclear size in the blastema component, with occasional nuclei being very large (thought to represent nuclear unrest). The morphological findings were further supported by immunocytochemistry: AE1/AE3 immunostaining of the epithelial component, WT1 stained all three components of the tumour, and myogenin was negative. Based on the cytological findings, neo-adjuvant chemotherapy, according to the International Society for Paediatric Oncology (SIOP) Umbrella Renal Tumour Study Group (RTSG) 2016 protocol, was initiated, consisting of weekly vincristine and actinomycin D (VA) as for localised WT.[5] An interim MRI scan after 4 weeks of therapy showed no significant interval change in the tumour size (Figure 1).

Due to the discordance between the radiological imaging and cytological diagnosis together with a rather poor response to neo-adjuvant chemotherapy, it was decided to perform a second biopsy. This biopsy was performed via access through a open lateral transabdominal incision, cognisant of upstaging the tumour. The second biopsy again confirmed a diagnosis of WT with treatment-related changes. The histology of the tumour was partially cystic with protruding large papillary fronds, lined by epithelium, with a sclerotic stroma containing numerous small tubules. Some tubules demonstrated nuclear unrest, with nuclear enlargement and hyperchromasia, but did not fulfil the criteria for anaplasia. Immunohistochemical stains for AE1/AE3 and WT1 were diffusely positive, with AE1/AE3 demonstrating the epithelial nature of the cells. P53 was also diffusely positive (Figure 2).

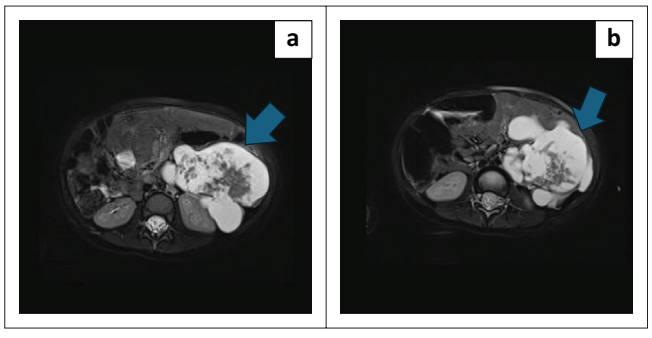

Source: Image taken by Pawel Schubert, Tygerberg Hospital, South Africa, 2025, image used with permission. No unauthorised duplication allowed

Note: Anteriorly, the mass abutted loops of the small bowel and anteriorly displaced the splenic flexure and distal transverse colon. Medially, the mass extended to the midline and displaced the aorta. No retro-aortic extension, involvement of the aorta or inferior vena cava or extension into the neural foramina was noted. The mass abutted the left renal hilum with no evidence of left renal vein or artery infiltration. Posteriorly, the mass displaced the left kidney, pancreatic tail and spleen with no sign of infiltration. Both adrenal glands were normal. The right kidney was normal.

FIGURE 1: Radiologic features of the mass: (a) An magnetic resonance imaging scan showed a heterogeneous, lobulated mass (9.6 cm × 8.2 cm) occupying the left side of the abdomen (blue arrows); (b) Second interim evaluation scan: tumour measurements: 8.2 cm × 7.3 cm.

Management and clinical course

The case was again brought to the multidisciplinary forum as a unusual form of ERWT. As a plane of separation between the tumour and the lower pole of the left kidney was unclear on the MRI scan, a tumour resection and left hemi-nephrectomy was planned. However, intraoperatively, the left renal blood supply and the tumour mass were thought to be in close relationship to each other, and therefore, a radical left nephrectomy and tumour excision was performed via laparotomy. A normal left kidney and a large extrarenal tumour were removed with no overt invasion into adjacent structures (Figure 3). Pathological examination of the resected specimen revealed a well-circumscribed tumour measuring 60 mm × 60 mm × 58 mm, separate from the kidney (Figure 3). The histomorphology showed a similar picture to what was seen on the incisional biopsy. Solid and cystic regions were seen with predominance of epithelium forming small, primitive tubules to more well-differentiated tubules and lining papillary fronds that projected into the cystic spaces.

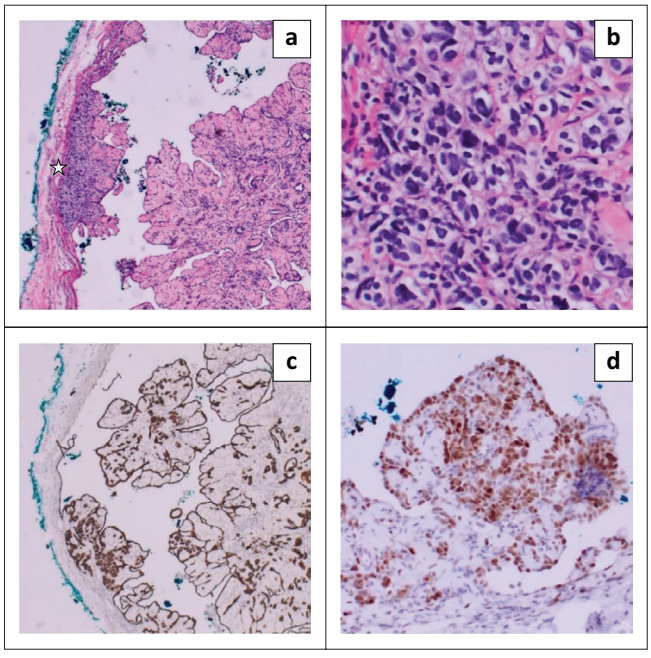

Source: Image taken by Pawel Schubert, Tygerberg Hospital, South Africa, 2025, image used with permission. No unauthorised duplication allowed

FIGURE 2: Pathological features of the mass (open biopsy): (a) A low magnification view of a cystic tumour with protruding papillary fronds with fibrotic stromal cores (haematoxylin and eosin stain); (b) An area of nuclear unrest with a high-power view of the area (marked in [a] with a star; (c) All the tumour cells stained positive (AE1/AE3 immunostain); (d) P53 immunostain, staining the area in B positive (intermediate magnification).

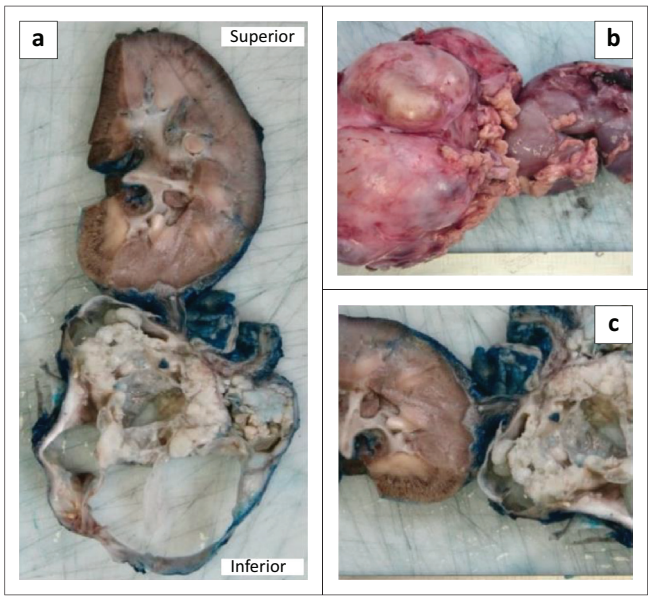

Source: Image taken by Pawel Schubert, Tygerberg Hospital, South Africa, 2025, image used with permission. No unauthorised duplication allowed

Note: The native kidney is located superior with the tumour seen just inferior of the specimen. There was no connection between these two specimens, besides a fibrous adhesion.

FIGURE 3: Macroscopic appearance of the resected surgical specimen: (a) A formalin fixed specimen that has been bisected in the coronal plane; (b) A image of the fresh specimen with the native kidney on the right with the large tumour on the left; (c) Closer photograph shows a clear demarcation of the native kidney on the left with the tumour on the right.

The stromal component comprised of vast amounts of fibrous tissue. Micro-foci of blastema, accounting for less than 1% of the viable tumour, was also seen.

The histological staging was stage 2, intermediate risk; however, due to the open biopsy, the final staging was classified as stage 3 ERWT. Two lymph nodes submitted showed no involvement.

As there is no standardised treatment pathway for ERWT, we sought an opinion from a member of the SIOP RTSG. It was advised that the tumour histology would direct therapy and the outcomes would be the same as if the kidney had been infiltrated. We therefore extrapolated post-operative chemotherapy in accordance with SIOP Umbrella RTSG protocol. This included vincristine and actinomycin D for 27 weeks as per the initial histological staging.[5] We excluded doxorubicin from post-operative chemotherapy in accordance with the findings of Pritchard-Jones et al who describe that doxorubicin does not need to be included in treatment of stage 2–3 intermediate risk Wilms' tumour when the histological response to pre-operative chemotherapy is incorporated into the risk stratification.[6] The patient received whole abdominal radiotherapy of 15.0 Gy as the peritoneum was opened during the second biopsy. Currently, the boy is very well and is receiving long-term follow-up care. An abdominal sonar 4 months after treatment completion showed no signs of local recurrence. The patient continues to receive three monthly clinical reviews with an abdominal sonar repeated for disease surveillance at every alternate visit.

Discussion

Paediatric ERWT is a rare malignancy. All publications are case reports or small case series, as shown in a recent systematic literature review.[2] The primary tumour site (retroperitoneum) in our patient corresponds with the most prevalent sites described in case series, in which 70% of ERWTs arise from the retroperitoneum, inguinal region or scrotum and female genital organs.[2] Previous publications highlighted that there is no standardised treatment protocol for ERWT in children. However, the therapeutic approach is multimodal, based on surgery (resection or biopsy), which is essential for diagnostic confirmation.[2]

In our paediatric oncology unit, we safely utilise fine needle cytological diagnostic procedures for all patients with suspected intra-abdominal malignancies.[7] The histological confirmation of the diagnosis via a second biopsy was essential due to the discordant radiological-cytological picture and the tumour showing minimal response to neo-adjuvant chemotherapy. The subsequent complete surgical excision of the tumour then confirmed the diagnosis of ERWT (with no anaplasia). The poor radiological response to chemotherapy was possibly due to the partially cystic nature of the tumour and the solid component becoming fibrotic. The presence of anaplasia in ERWT and WT, characterised by extreme polyploidy with nuclear and mitotic atypia, indicates a poor prognosis due to increased treatment resistance.[8]

Previous case reports have shown therapeutic heterogeneity in the management of this tumour, and death was reported in only five cases (6.1%) at the end of a 2.5-year median follow-up.[2,5] The causes of death included progressive metastatic disease and relapse. The lack of a longer follow-up period precludes knowledge regarding mid- or long-term relapsed disease and the actual mortality rate. According to both the Children's Oncology Group and SIOP RTSG, despite different treatment approaches, the overall survival rate of ERWT is approximately 90%.[2]

Conclusion

Extrarenal Wilms tumour is extremely rare in children. It should be differentiated from neuroblastoma, teratomas/germ cell tumours and other retroperitoneal tumours. The prognosis in adequately treated ERWT is good if no anaplasia is evidenced in the histopathology.[8,9] There is no standardised treatment pathway, but successful management requires multimodal therapy based on safe surgical resection and adjuvant chemotherapy.

Acknowledgements

Competing interests

The authors, Leilah Schoonraad; Anel van Zyl; Bob Banieghbal and Pawel Schubert, declare that they have no financial or personal relationships that may have inappropriately influenced them in writing this article.

CRediT authorship contribution

Leilah Schoonraad: Conceptualisation, Methodology, Visualisation, Writing – original draft. Anel van Zyl: Writing – review & editing. Bob Banieghbal: Writing – review & editing. Pawel Schubert: Writing – review & editing. All authors reviewed the article, contributed to the discussion of results, approved the final version for submission and publication and take responsibility for the integrity of its findings.

Ethical considerations

Ethical clearance to conduct this study was obtained from the Human Research Ethics Committee (HREC) (Medical) of Stellenbosch University (HREC Reference No: C25/06/021). Written patient parental consent was obtained prior to the submission of this article.

Funding information

This research received no specific grant from any funding agency in the public, commercial or not-for-profit sectors.

Data availability

The authors confirm that the data supporting the findings of this case report are available within the article and its references.

Disclaimer

The views and opinions expressed in this article are those of the authors and are the product of professional research. They do not necessarily reflect the official policy or position of any affiliated institution, funder, agency or that of the publisher. The authors are responsible for this article's results, findings, and content.

References

1. Brits E, Gerber E, Iroka I, et al. Paediatric nephroblastoma at a South African tertiary hospital: A 21-year retrospective analysis. S Afr Med J. 2024;114(12):e2223. https://doi.org/10.7196/SAMJ.2024.v114i12.2223
2. Karim A, Shaikhyzada K, Abulkhanova N, et al. Pediatric extra-renal nephroblastoma (Wilms' tumor): A systematic case-based review. Cancers. 2023;15(9):2563. https://doi.org/10.3390/cancers15092563
3. D'Angio GJ. The national wilms tumor study: A 40 year perspective. Lifetime Data Anal. 2007;13(4):463–470. https://doi.org/10.1007/s10985-007-9062-0
4. Taguchi S, Shono T, Mori D, Horie H. Extrarenal Wilms tumor in children with unfavorable histology: A case report. J Pediatr Surg. 2010;45(9):e19–e22. https://doi.org/10.1016/j.jpedsurg.2010.06.004
5. Van den Heuvel-Eibrink MM, Hol JA, Pritchard-Jones K, et al. Rationale for the treatment of Wilms tumour in the UMBRELLA SIOP–RTSG 2016 protocol. Nat Rev Urol. 2017;14(12):743–752. https://doi.org/10.1038/nrurol.2017.163
6. Pritchard-Jones K, Bergeron C, De Camargo B, et al. Omission of doxorubicin from the treatment of stage II–III, intermediate-risk Wilms' tumour (SIOP WT 2001): An open-label, non-inferiority, randomised controlled trial. Lancet. 2015;386(9999):1156–1164. https://doi.org/10.1016/S0140-6736(14)62395-3
7. Bondera T, Schubert P, Van Zyl A, Pitcher R, Bagadia A. Diagnostic yield and accuracy of paediatric image-guided fine needle aspiration biopsy of deep organ tumours. SA J Radiol. 2022;26(1):2485. https://doi.org/10.4102/sajr.v26i1.2485
8. Teerthanath S. Extrarenal nephroblastoma. J Lab Physicians. 2011;3(1):59–60. https://doi.org/10.4103/0974-2727.78572
9. Kumar S, Sunilkumar MN, Surendran D. Extrarenal nephroblastoma in a 7 year old child: A rare case report with review of literature. Int J Contemp Pediatr. 2015;2(2):155–158. https://doi.org/10.5455/2349-3291.ijcp20150519