SA Journal of Oncology
ISSN: (Online) 2523-0646, (Print) 2518-8704

Comparison of magnetic resonance imaging and B-mode ultrasound findings in children with retinoblastoma

Check for updates

Authors:
Priscilla Magagula[1]
Natasha Naidu[2]
Tanyia Pillay[3]

Affiliations:
[1]Department of Diagnostic Radiology, Faculty of Health Sciences, University of the Witwatersrand, Johannesburg, South Africa

[2]Department of Ophthalmology, Faculty of Health Sciences, University of the Witwatersrand, Johannesburg, South Africa

[3]Department of Radiology, Faculty of Health Sciences, University of Cape Town, Cape Town, South Africa

Corresponding author:
Priscilla Magagula,
priscmagagula@gmail.com

Dates:
Received: 24 Nov. 2025
Accepted: 13 May 2026
Published: 02 July 2026

How to cite this article:
Magagula P, Naidu N, Pillay T. Comparison of magnetic resonance imaging and B-mode ultrasound findings in children with retinoblastoma. S. Afr. j. oncol. 2026;10(0), a366. https://doi.org/10.4102/sajo.v10i0.366

Copyright:
© 2026. The Authors. Licensee: AOSIS. This work is licensed under the Creative Commons Attribution 4.0 International (CC BY 4.0) license (https://creativecommons.org/licenses/by/4.0/).

Read online:
Scan this QR code with your smart phone or mobile device to read online.

Background: Retinoblastoma is the most frequently occurring primary intraocular neoplasm in the paediatric population and has a good prognosis when treated early. Magnetic resonance imaging (MRI) and B-mode ultrasound are both highly sensitive for identifying features of retinoblastoma.

Aim: To compare the detection of intraocular calcification in retinoblastoma patients between MRI and B-mode ultrasound, describe the demographics, disease laterality and extent at presentation.

Setting: Tertiary hospitals in Johannesburg from October 2020 to August 2022.

Methods: This study retrospectively reviewed records of paediatric patients with confirmed retinoblastoma who had a B-mode ultrasound at presentation performed by an ophthalmologist, and MRI of the brain and orbits.

Results: Thirty-six records were reviewed, with 23 meeting the study inclusion criteria. The male-to-female ratio was 1.09. The mean age at presentation was 21.14 months (median 11.3). Of the 23 patients (46 eyes), 35 eyes had retinoblastoma. Both modalities demonstrated 95% sensitivity in the detection of intraocular calcification. Sixty per cent had International Intraocular Retinoblastoma Classification group E disease, followed by 34% group D, while none presented with group A or B disease.

Conclusion: The detection of intraocular calcification in retinoblastoma patients using B-mode ultrasound and MRI is comparable, demonstrating equal sensitivity in this study; however, the two modalities are complementary rather than interchangeable. Magnetic resonance imaging still has advantages for staging beyond the globe.

Contribution: In resource-constrained settings, the high sensitivity of B-mode ultrasound for detecting calcification allows for early and accurate diagnosis even when advanced technology is scarce.

Keywords: retinoblastoma; B-mode ultrasound; MRI; ocular calcification; intraocular neoplasm; ocular imaging; leukocoria.

Introduction

Retinoblastoma is the most frequently occurring primary intraocular neoplasm in the paediatric population, with a good prognosis when treated early.[1,2] It is sporadic in 90% of cases, usually from spontaneous mutation of the RB 1 gene, with the remainder hereditary.[3] Eighty per cent of cases present before the age of 4 years.[1,3] The survival rate in developed countries has increased to up to 97% with advances in evaluation and diagnosis.[4] Although retinoblastoma is curable, outcomes remain poor in resource limited settings, with survival rates as low as 20% – 46% in Africa.[5]

The commonest presenting feature of retinoblastoma is leukocoria, with strabismus and visual loss also frequently observed.[1,2,6] Other signs may include iris rubeosis, hypopyon, hyphaema, buphthalmos, orbital cellulitis and exophthalmia, while in some cases it may be asymptomatic.[7] The diagnosis of retinoblastoma is usually established by the ophthalmologist on the basis of fundoscopy and B-mode ultrasound.[8]

Examination under anaesthesia is crucial for staging and management of retinoblastoma.[2] Ultrasonography enables detailed cross-sectional examination of the entire globe, facilitated by the superficial position of the eye and its cystic composition.[8,9,10] Routine ocular sonography is

performed with B-mode ultrasound with a frequency range of 7.5 MHz – 10 MHz.[10] The advantages of ultrasound include lower cost, rapid acquisition, real-time imaging and ease of use in remote centres.[10,11]

Calcification is a key imaging feature in retinoblastoma, presenting in up to 95% of cases.[1,8] The presence of calcification differentiates retinoblastoma from other simulating lesions including Coats disease, persistent hyperplastic primary vitreous and toxocara endophthalmitis.[12] On B-mode ultrasonography, retinoblastoma is visualised as an intraocular mass with focal areas of high internal reflectivity and posterior acoustic shadowing representing calcifications.[1] B-mode ultrasound detects calcification in 92% – 95% cases of confirmed retinoblastoma.[8] Sensitivity of detecting calcification on B-mode ultrasound decreases with smaller calcifications.[12]

Magnetic resonance imaging (MRI) is an essential imaging modality in the detection of tumours and monitoring response after treatment.[3]

It is valuable in the assessment of tumour extent.[8] The advantages of MRI over B-mode ultrasound include superior soft tissue contrast, enabling definitive confirmation of intraocular mass lesions and assessment of disease extension, both extraocular and intracranial.[3,8] Spread into the optic nerve is associated with higher mortality, 65%, compared to 8% without optic involvement.[8,10] Imaging approaches differ per institution with variations regarding the use of small surface coils or multichannel head coils and imaging at 1.5T or 3T magnet strength.[1,8] Heavily T2 weighted, high-resolution contrast enhanced MRI of the orbits is considered the optimal imaging for detecting retinoblastoma.[1,8] Retinoblastoma demonstrates variable degrees of calcification,[13] which appears as signal voids on susceptibility weighted imaging (SWI) MRI sequences.[1] Gradient echo imaging can also be used to detect calcification; however, SWI is more sensitive[14] and allows for differentiation between calcification and haemorrhages.[14,15]

On MRI, retinoblastoma appears as an intermediate to hyperintense lesion on T1-weighted imaging and hypointense lesion on T2-weighted imaging when compared to vitreous.[8,13] On T1-weighted imaging, calcification is demonstrated as areas of very low signal inside the tumour.[3] Small tumours demonstrate homogenous enhancement, while heterogenous enhancement is often noted in larger tumours as a result of necrosis and haemorrhage.[2,8]

The primary objective of this study was to compare the detection of intraocular calcification in retinoblastoma between MRI and B-scan ultrasound. Additionally, we sought to describe the demographics, tumour laterality and the International Intraocular Retinoblastoma Classification (IIRC) grouping of tumours at presentation. International Intraocular Retinoblastoma Classification divides retinoblastoma into groups A to E, based on size, location and extent and determines treatment options and prognostication.[5] Group A represents the smallest, most localised tumours while group E represents the most advanced and extensive cases.[5,7] Group A and B tumours are confined to the retina. Group C refers to focal subretinal or vitreous seeds, while group D refers to diffuse vitreous or subretinal seeding.[5] Group E refers to globe destroying disease involving more than 50% of the globe, neovascular glaucoma, phthisis bulbi or frank extraocular involvement.[5] International Intraocular Retinoblastoma Classification groups A to C have a good prognosis and high rates of globe salvage, with good response to chemotherapy and focal therapy, while group E tumours require enucleation.[5]

Methods

Study design

This study was a descriptive retrospective review of MRI and B-mode ultrasound reports for paediatric patients with confirmed retinoblastoma.

The study population included paediatric patients aged 0 months to 10 years with confirmed retinoblastoma, who had undergone B-mode ultrasound imaging at St John's Eye Hospital. These patients were subsequently referred to Nelson Mandela Children's Hospital (NMCH) for MRI brain and orbits. The study period was from October 2020 to August 2022.

Data collection

Data were collated from the Picture Archiving and Communication System (PACS) and physical hospital records at the two hospitals by the principal investigator using a database provided by the supervisors. Thirteen patient records were excluded from the study sample as they had incomplete data. This resulted in a cohort consisting of 23 patients. Variables extracted from the reports included patient age, gender, date of examinations, laterality, presence of calcification on B-mode ultrasound and MRI, time lapse between the two studies and IIRC grouping at the time of diagnosis.

Technique

The ultrasound studies were performed at presentation by an ophthalmologist with an interest in paediatric ophthalmology, and the results were documented in the clinic records. A 10 MHz 2 ring array B probe Tomey B-scan UD800 Modular A/B scan was used. This is a high-resolution ultrasound probe used for detailed diagnostic imaging of the eye. The patients then underwent formal examination under anaesthesia with documentation of the clinical findings.

The MRI studies were performed on a General Electric (GE) 3T MRI MR750W at a tertiary children's hospital. The orbital MRI protocol included high-resolution T2-weighted sequences of the orbits, SWI and post contrast T1-weighted imaging. The images were archived on the hospital GE PACS.

Statistical analysis

Data were entered into an Excel sheet from the data collection sheets. A de-identified Excel spreadsheet was imported, using Stata software version 17. Data cleaning processes included checking for duplicates, missing values, recording and categorising variables.

Descriptive statistics were conducted. Categorical variables were presented as frequencies and percentages. The continuous variables, such as the age were presented as mean ± standard deviation and/or median and interquartile range if not normally distributed. The trend in prevalence was presented graphically. Missing information was checked on each variable. Association of categorical variables was assessed using the Fisher exact test. Statistically significant association was set at p-value < 0.05.

Ethical considerations

Ethical clearance to conduct this study was obtained from the University of the Witwatersrand Human Research Ethics Committee (No. M2211109). The requirement for informed consent was waived, as this was a retrospective review of reports of imaging already performed, with no radiation exposure or cost to patients.

Results

Thirty-six patient records of MRI orbits and B-mode ultrasound studies conducted in children with confirmed retinoblastoma from October 2020 to August 2022 were reviewed. Of these, 23 met the study inclusion criteria, with the rest excluded as they had incomplete data (Figure 1).

Of the 23 patients, 12 (52%) were male, and 11 (48%) were female, with a male-to-female ratio of 1.09. The mean age at presentation overall was 21.14 months (median 11.3). The age at presentation for unilateral disease was 28.5 months, with a median of 31.6 months and 9.77 months, with a median of 2.52 months for those with bilateral disease (Table 1). Bilateral disease was noted in 12 out of 23 (52%) of the patients, with 11 out of 23 (48%) presenting with unilateral disease, resulting in retinoblastoma in 35 of the 46 eyes imaged. The average time lapse between B-mode ultrasound at St John's Eye Hospital and MRI at NMCH was 1.39 months.

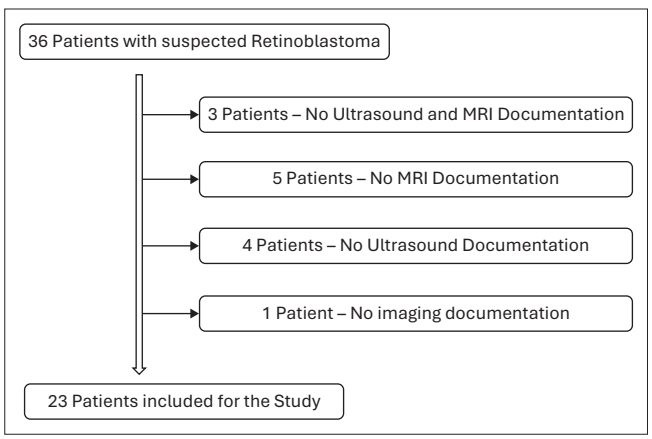

MRI, magnetic resonance imaging.

FIGURE 1: Flow chart for patient selection.

Of the 35 eyes with retinoblastoma, 30 out of 35 (85.71%) demonstrated intraocular calcification on both B-mode ultrasound and MRI, a major finding in patients with retinoblastoma. Two out of 35 (5.71%) did not demonstrate calcification on both B-mode ultrasound and MRI. Three out of 35 (8.57%) had discrepant findings demonstrating calcification on only one modality, either MRI or B-mode ultrasound. There was 91.3% agreement between B-mode ultrasound and MRI finding of intraocular calcification, p-value = 0.034.

The prevalence of detection of calcification on both modalities was 87%, with a sensitivity of 95% and a specificity of 66.7%. The positive predictive value and negative predictive value were 95% and 66.7%, respectively (Table 2). The Cohen Kappa agreement was 0.6167 (substantial agreement), while Gwet's agreement was 0.8875, which on the benchmark scale corresponds to an almost perfect agreement (Table 3).

TABLE 1: Demographic characteristics of the study population (N = 23).

Number of patients	*n*	%	Mean	Median
Gender				
Male	12	52	-	-
Female	11	48	-	-
Laterality				
Unilateral	11	48	-	-
Bilateral	12	52	-	-
Age at presentation				
Overall	-	-	21.14	11.30
Unilateral disease	-	-	28.50	31.60
Bilateral disease	-	-	9.77	2.52

TABLE 2: Sensitivity, specificity of both B-mode ultrasound and magnetic resonance imaging.

Statistic	%	Confidence interval
Prevalence	87.0	66–97.2
Sensitivity	95.0	75.1–99.9
Specificity	66.7	9.43–99.2
PPV	95.0	75.1–99.9
NPV	66.7	9.43–99.2

PPV, positive predictive value; NPV, negative predictive value.

TABLE 3: Agreement between B-mode ultrasound and magnetic resonance imaging.

Statistic	Value	Benchmark scale		*p*-value
		Agreement coefficient range	Interpretation	
Agreement	91.30%	< 0.0000	Poor	0.0016
Expected agreement	77.32%	0.0000–0.2000	Slight	-
Kappa	0.6167	0.2000–0.4000	Fair	-
Gwet's agreement	0.8875	0.4000–0.6000	Moderate	-
Std. error	0.2085	0.6000–0.8000	Substantial	-
Z	2.96	0.8000–1.0000	Almost perfect	-

Std., standard.

Of the 35 eyes with retinoblastoma, 21 out of 35 (60%) had group E disease, followed by group D in 12 out of 35 (34%).

Only 2 out of 35 eyes (6%) presented with group C disease. One hundred per cent of unilateral cases presented with advanced disease (IIRC group D or E) compared to 92% in bilateral cases.

Discussion

B-mode ultrasound and MRI are key imaging modalities in the diagnosis of retinoblastoma and determination of tumour extent.[8]

Calcification is the major imaging feature in retinoblastoma, demonstrated in 87% cases in our study on both B-mode ultrasound (Figure 2) and MRI (Figure 3). This aligns with literature, which states that ultrasound detects calcification in 92% – 95% of confirmed cases of retinoblastoma.[8]

In our study, the two modalities demonstrated equal sensitivity of 95% and specificity of 66.7% in the detection of calcification. There was 93.1% agreement between the two modalities, which corresponds to an almost perfect agreement on the benchmark scale. This confirms that both B-mode ultrasound and MRI are equally effective in the detection of calcification. B-mode ultrasound can therefore be used as a first-line imaging modality in resource limited settings. This will enable early treatment and improve morbidity and mortality.

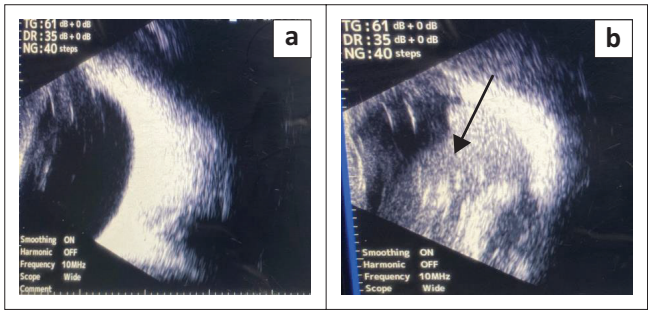

Source: B-mode ophthalmic ultrasound image obtained with permission from St John's Eye Hospital on 23 January 2025.

FIGURE 2: (a) B-scan ultrasonography of a normal eye, demonstrating anechoic vitreous cavity with no evidence of vitreous opacities or retinal detachment. The posterior globe contour remains intact and smooth. (b) B-scan ultrasonography illustrating Group E retinoblastoma: a large intraocular tumour with high reflectivity (black arrow), calcification causing acoustic shadowing and disruption of normal posterior segment anatomy.

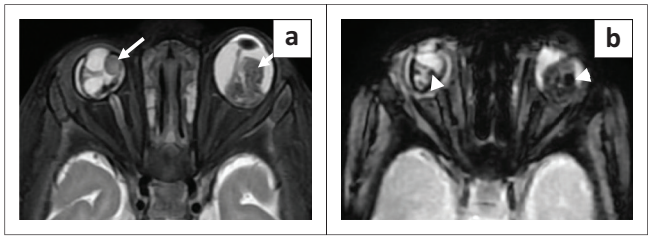

Source: The MRI images were exported with permission from the Nelson Mandela Children's Hospital (NMCH) Picture Archiving and Communication System (PACS) on 23 January 2025.

MRI, magnetic resonance imaging; GRE, gradient echo imaging.

FIGURE 3: Bilateral retinoblastoma in an 11-month-old male. Axial fat saturated T2 weighted MRI (a) demonstrates bilateral lobulated intraocular masses (white arrows) with hypointense signal relative to the vitreous. Axial GRE (b) demonstrates foci of blooming (white arrowheads) within the masses corresponding to areas of calcification.

There was no significant gender predilection in our study, with almost equal distribution of males (52%) and females (48%), concordant with other several previous studies without gender predilection in retinoblastoma.[16,17,18]

Our study demonstrated approximately equal proportions of unilateral versus bilateral disease, 48% and 52%, respectively, consistent with findings by Rojanaporn et al.[17] Other published studies have, however, demonstrated higher rates of unilateral disease.[19] This could be attributed to a small study cohort and convenience sampling. Some of the patients with unilateral disease would be sent for enucleation after B-mode ultrasound without further imaging with MRI, therefore excluded from the study.

The median age at presentation for bilateral disease was significantly lower than for unilateral disease, 2.52 months compared to 31.6 months, which aligns with other published studies where bilateral disease presented earlier.[17,18]

The average time lapse between B-mode ultrasound and MRI was 1.39 months. Six patients had an MRI done before B-mode ultrasound; this was attributed to technical factors such as unavailability of B-mode ultrasound services at the time of presentation.

Majority of the patients presented with advanced tumour (Figure 4), with 60% demonstrating IIRC group E on imaging, followed by group D (34%). Moreover, 100% of unilateral cases presented with advanced disease (IIRC group D or E) compared to 92% in bilateral cases. This is discordant with the findings by Mohammad et al.,[18] who found only 46% of

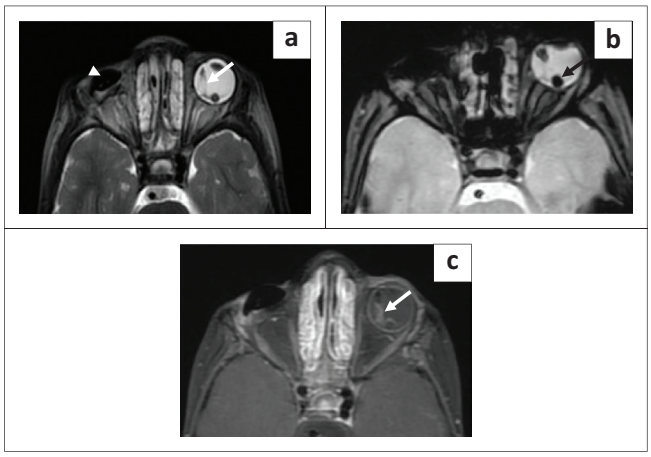

Source: The MRI images were exported with permission from the Nelson Mandela Children's Hospital (NMCH) Picture Archiving and Communication System (PACS) on 23 January 2025.

MRI, magnetic resonance imaging; GRE, gradient echo imaging.

FIGURE 4: Four-year-old female with enucleation for previous right retinoblastoma and a newly diagnosed left retinoblastoma. Axial T2 weighted MRI (a) demonstrates right enucleation with a prosthesis (white arrowhead) and a lobulated left intraocular mass (white arrow). Axial GRE (b) demonstrates foci of blooming (black arrow) in the left globe. Heterogenous tumour enhancement (white arrow) is demonstrated on fat saturated post-contrast axial T1 (c).

advanced disease in bilateral cases and 88% in unilateral cases. No tumours were detected as group A or B disease. This may be attributed to poor health seeking behaviour among the affected population, delayed presentation and poor referral patterns.

Limitations

The study was a descriptive retrospective review with inherent bias. The sample size was limited. The relatively small sample size may affect the robustness of the statistical analysis. There is a need for a prospective study enrolling more participants to provide greater statistical power and more definitive conclusions.

A 10 MHz probe was used in our study, which is the standard practice, but higher frequency probes are sometimes preferred for detecting very small calcifications.

Conclusion

Retinoblastoma is associated with high morbidity and mortality if diagnosed late. Both B-mode ultrasound and MRI are effective at detecting intraocular calcification, which is a major imaging feature in the diagnosis of retinoblastoma. The two modalities are complementary rather than interchangeable. B-mode ultrasound remains an easily accessible, low cost, rapid and reliable tool for confirming calcification, but cannot replace MRI's essential role in staging the disease and assessing potential spread beyond the globe. B-mode ultrasound can therefore be used as a first-line modality to assess patients with suspected retinoblastoma at an early stage in resource limited settings. Ultrasound is non-invasive and repeatable, therefore ideal for serial examinations to monitor serial response where frequent MRI follow-up studies are not feasible. Patients with abnormal studies can then be referred for MRI at an earlier stage, as MRI remains important for assessing optic nerve and extraocular extension, which guide treatment options and follow-up.

Acknowledgements

The authors acknowledge the Divisions of Radiation Sciences and Ophthalmology, University of the Witwatersrand for allowing access to the data. They further acknowledge Ms B. Kagodora for performing statistical analysis of the data.

Competing interests

The authors declare that they have no financial or personal relationships that may have inappropriately influenced them in writing this article.

CRediT authorship contribution

Priscilla Magagula: Conceptualisation, Data curation, Formal analysis, Investigation, Methodology, Project administration, Resources, Software, Validation, Visualisation, Writing – original draft, Writing – review & editing. Natasha Naidu: Conceptualisation, Formal analysis, Investigation, Methodology, Project administration, Resources, Supervision, Visualisation, Writing – review & editing. Tanyia Pillay: Conceptualisation, Formal analysis, Investigation, Methodology, Project administration, Resources, Supervision, Visualisation, Writing – review & editing. All authors reviewed the article, contributed to the discussion of results, approved the final version for submission and publication, and take responsibility for the integrity of its findings.

Funding information

This research received no specific grant from any funding agency in the public, commercial or not-for-profit sectors.

Data availability

Data are available on request from the corresponding author, Priscilla Magagula.

Disclaimer

The views and opinions expressed in this article are those of the authors and are the product of professional research. They do not necessarily reflect the official policy or position of any affiliated institution, funder, agency or that of the publisher. The authors are responsible for this article's results, findings and content.

References

1. Silvera VM, Guerin JB, Brinjikji W, Dalvin LA. Retinoblastoma: What the neuroradiologist needs to know. Am J Neuroradiol. 2021;42(4):618–626. https://doi.org/10.3174/ajnr.A6949
2. Pai V, Muthusami P, Ertl-Wagner B, et al. Diagnostic imaging for retinoblastoma: Cancer staging: Guide for providing essential insights for Ophthalmologists and Oncologists. Radiographics. 2024;44(4):e230125. https://doi.org/10.1148/rg.230125
3. Razek AA, Elkhamary S. MRI of retinoblastoma. Br J Radiol. 2011;84(1005):775–784. https://doi.org/10.1259/bjr/32022497
4. Langevin ST, Marr BP. Retinoblastoma: Presentation, evaluation, and diagnosis. In: Alkatan HM, editor. Retinoblastoma – Past, present and future. London: IntechOpen, 2019; p. 3.
5. Houston SK, Murray TG, Wolfe SQ, Fernandes CE. Current update on retinoblastoma. Int Ophthalmol Clin. 2011;51(1):77–91. https://doi.org/10.1097/IIO.0b013e3182010f29
6. Kanukollu VM, Tripathy K. Leukocoria [homepage on the Internet]. Treasure Island, FL: StatPearls Publishing; 2025 [updated 2023 Aug 25; cited 2025 Jul 15]. Available from: https://www.ncbi.nlm.nih.gov/books/NBK560794/
7. Aerts I, Lumbroso-Le Rouic L, Gauthier-Villars M, Brisse H, Doz F, Desjardins L. Retinoblastoma. Orphanet J Rare Dis. 2006;1:31. https://doi.org/10.1186/1750-1172-1-31
8. De Graaf P, Göricke S, Rodjan F, et al. Guidelines for imaging retinoblastoma: Imaging principles and MRI standardization. Paediatr Radiol. 2012;42(1):2–14. https://doi.org/10.1007/s00247-011-2201-5
9. Bedi DG, Gombos DS, Ng CS, Singh S. Sonography of the eye. Am J Roentgenol. 2006;187(4):1061–1072. https://doi.org/10.2214/AJR.04.1842
10. Sen KK, Parihar JKS, Saini M, Moorthy RS. Conventional B-mode ultrasonography for evaluation of retinal disorders. Med J Armed Forces India. 2003;59(4):310–312. https://doi.org/10.1016/S0377-1237(03)80142-9
11. Sutton S, Fisher KL. Sonographic detection of unilateral retinoblastoma. J Diagn Med Sonogr. 2016;32(4):228–233. https://doi.org/10.1177/8756479316650871
12. Rodjan F, De Graaf P, Van der Valk P, et al. Detection of calcifications in retinoblastoma using gradient-echo MR imaging sequences: Comparative study between in vivo MR imaging and ex vivo high-resolution CT. Am J Neuroradiol. 2015;36(2):355–360. https://doi.org/10.3174/ajnr.A4163
13. Kaste SC, Jenkins JJ, 3rd, Pratt CB, Langston JW, Haik BG. Retinoblastoma: Sonographic findings with pathologic correlation in pediatric patients. Am J Roentgenol. 2000;175(2):495–501. https://doi.org/10.2214/ajr.175.2.1750495
14. Soman S, Holdsworth SJ, Barnes PD, et al. Improved T2* imaging without increase in scan time: SWI processing of 2D gradient echo. Am J Neuroradiol. 2013;34(11):2092–2097. https://doi.org/10.3174/ajnr.A3595
15. Gasparotti R, Pinelli L, Liserre R. New MR sequences in daily practice: Susceptibility weighted imaging. A pictorial essay. Insights Imaging. 2011;2(4):335–347. https://doi.org/10.1007/s13244-011-0086-3

16. Fabian ID, Rosser E, Sagoo MS. Epidemiological and genetic considerations in retinoblastoma. Community Eye Health. 2018;31(101):29–30.

17. Rojanaporn D, Attaseth T, Dieosuthichat W, et al. Clinical presentations and outcomes of retinoblastoma patients in relation to the advent of new multimodal treatments: A 12-year report from single tertiary referral institute in Thailand. J Ophthalmol. 2020;2020:4231841. https://doi.org/10.1155/2020/4231841

18. Mohammad M, Mehyar M, Halalsheh H, et al. The impact of tumor laterality (unilateral vs. bilateral) on presentation and management outcome in patients with retinoblastoma. J Clin Med. 2024;13(7):2146. https://doi.org/10.3390/jcm13072146

19. Kaliki S, Patel A, Iram S, Ramappa G, Mohamed A, Palkonda VAR. Retinoblastoma in India. Retina. 2019;39(2):379–391. https://doi.org/10.1097/IAE.0000000000001962