SA Journal of Oncology
ISSN: (Online) 2523-0646, (Print) 2518-8704

The young breast cancer patient: A tertiary institution's experience

Check for updates

Authors:
Yvonne K. Ruhinda-Radebe[1]
Maureen Joffe[2]
Oluwatosin A. Ayeni[2,3]
Thandi E. Buthelezi[1]

Affiliations:
[1]Division of Diagnostic Radiology, Faculty of Health Sciences, University of the Witwatersrand, Johannesburg, South Africa

[2]Strengthening Oncology Services Research Unit, Faculty of Health Sciences, University of the Witwatersrand, Johannesburg, South Africa

[3]Division of Radiation Oncology, Faculty of Health Sciences, University of the Witwatersrand, Johannesburg, South Africa

Corresponding author:
Yvonne Ruhinda-Radebe,
2644223@students.wits.ac.za

Dates:
Received: 28 Sept. 2025
Accepted: 01 June 2026
Published: 04 Sept. 2026

How to cite this article:
Ruhinda-Radebe YK, Joffe M, Ayeni OA, Buthelezi TE. The young breast cancer patient: A tertiary institution's experience. S. Afr. j. oncol. 2026;10(0), a358. https://doi.org/10.4102/sajo.v10i0.358

Copyright:
© 2026. The Authors. Licensee: AOSIS. This work is licensed under the Creative Commons Attribution 4.0 International (CC BY 4.0) license (https://creativecommons.org/licenses/by/4.0/).

Read online:
Scan this QR code with your smart phone or mobile device to read online.

Background: Breast cancer (BC) in sub-Saharan Africa affects not only older females but also those aged ≤40 years. At Chris Hani Baragwanath Academic Hospital (CHBAH), females with suspicious breast lesions undergo combined mammography and ultrasound with integrated Breast Imaging Reporting and Data System (BI-RADS) assessment to guide biopsy. The diagnostic performance of this approach in younger females remains clinically relevant because of increased breast density.

Aim: To assess the concordance between bimodal BI-RADS classification and histopathological diagnosis in females aged ≤40 years with biopsy-confirmed BC.

Setting: Chris Hani Baragwanath Academic Hospital, Johannesburg, South Africa, using data from the South African Breast Cancer and HIV Outcomes (SABCHO) cohort.

Methods: A retrospective review of females aged ≤40 years diagnosed with invasive BC over seven years was performed. Clinical and demographic characteristics were described, and concordance between bimodal BI-RADS classification and histopathological diagnosis was assessed.

Results: Of 354 patients identified, 309 met the inclusion criteria. The mean age was 35.2 ± 3.9 years, and invasive ductal carcinoma was the predominant subtype (93.5%). Concordance between bimodal BI-RADS classification and histopathological diagnosis was 97.7%. BI-RADS 5 was the most common imaging category, while discordant cases were confined to stage I, stage II and stage III disease. Most patients presented with locally advanced disease.

Conclusion: Bimodal BI-RADS assessment showed high concordance with histopathological diagnosis in females aged ≤ 40 years with biopsy-confirmed BC, supporting the use of combined mammography and ultrasound for evaluating suspicious breast lesions in this setting.

Contribution: This study adds evidence on the concordance of bimodal BI-RADS assessment with histopathological diagnosis in young females with BC in sub-Saharan Africa.

Keywords: BI-RADS; breast cancer; breast ultrasound; diagnostic imaging; histopathology; mammography; South Africa; young female.

Introduction

Breast cancer (BC) is the most frequently diagnosed cancer among females worldwide and the leading cause of cancer-related mortality globally. According to GLOBOCAN 2024, BC accounted for an estimated 2.4 million new cases of breast cancer, and approximately 690 000 deaths occurred globally.[1] In sub-Saharan Africa (SSA), the burden of BC is escalating because of increased life expectancy and lifestyle-related risk factors, with mortality-to-incidence ratios more than double those seen in high-income countries (HICs).[2] Notably, an estimated 26% of new BC cases in SSA occur in females under 50 years of age.[3]

In South Africa, BC is the most common malignancy among females of all racial groups, with a reported lifetime risk of 1 in 28.[4] Females in SSA, including South Africa, often present at younger ages and with more advanced disease stages compared to females in HICs.[5] This issue is further compounded in human immunodeficiency virus (HIV)-endemic areas. Previous studies from our institution have shown that 22% of women with BC were also living with HIV, and these females were diagnosed at a median age of 45 years, approximately 10 years younger than their HIV-negative counterparts.[6,7,8] Most women living with HIV (WLWH) in the cohort self-identified

as being of African ancestry. While HIV status did not significantly influence stage at diagnosis,[6] WLWH presented with more aggressive tumour biology.[7]

Globally, approximately 8% of BC cases occur in females under 40 years, with incidence rising in low- and middle-income countries (LMICs) where populations are generally younger.[8] Breast cancer accounts for nearly 30% of cancer diagnoses among adolescents and young adults (AYAs), defined as individuals aged 15 years – 39 years.[9] The definition of 'young' in breast oncology varies, but most literature uses the cut-off of 40 years.[10] Key risk factors in younger females include early menarche (before age 12 years), nulliparity and family history of BC.[10] In 97% of cases, young females themselves first detect a breast abnormality.[10] This group often presents with biologically aggressive tumours, advanced-stage disease and higher rates of local recurrence following breast-conserving therapy,[10] contributing to a 39% higher mortality rate compared to older females.[9]

Breast cancer detection in younger females is challenging. Dense breast tissue reduces the sensitivity of mammography, making it less effective in younger age groups.[11] This is especially relevant for females, who tend to have denser breasts even after adjusting for age, body mass index (BMI) and other factors.[12] Physiological changes during pregnancy and lactation further complicate detection.[11] As a result, both ultrasound and mammography may fail to identify early-stage disease,[13] and patients themselves often discover abnormalities.[10]

Histologically, the majority of BCs are ductal in origin, with invasive ductal carcinoma accounting for about 80% of cases[14] and fibroadenoma as the most common benign lesion.[15]

Early-stage diagnosis, along with timely treatment, remains the most critical determinant of survival in young BC patients. Standard diagnostic workup includes clinical breast examination, ultrasound or mammography and image-guided core biopsy.[16,17,18] Because of higher breast density in younger females, mammography alone is often insufficient, with ultrasound generally showing higher sensitivity in females under 45 years, whereas mammography alone performs better in older populations.[19]

In South Africa and globally, asymptomatic screening mammography is recommended starting at age 40 years,[4] and there is no formal screening programme for females under 40 years of age. Females generally present with self-detected breast symptoms. Magentic resonance imaging (MRI) may be used in selected cases to further characterise breast lesions and provide additional diagnostic information.[20] Unfortunately, MRI services are in short supply in the South African public healthcare system. Instead, young females with suspicious ultrasound findings receive a mammogram to confirm the need for subsequent image-guided core biopsies. Because mammography relies on detecting dense masses, its utility in young females with dense breast tissue is regarded as limited.

This study is therefore aimed at evaluating the diagnostic utility of mammography and breast ultrasound in symptomatic females aged 40 years and younger. We assessed the concordance between bimodal Breast Imaging Reporting and Data System (BI-RADS) and histopathology diagnostic findings in young females who were subsequently diagnosed with BC at Chris Hani Baragwanath Academic Hospital (CHBAH).[21,22]

Methods

The South African Breast Cancer and HIV Outcomes (SABCHO) study is an ongoing, multicentre cohort investigating outcomes in South African females newly diagnosed with invasive BC. Initiated in 2015, the study is conducted across six tertiary public hospitals in the Gauteng and KwaZulu-Natal provinces: (1) CHBAH, (2) Charlotte Maxeke Johannesburg Academic Hospital (Johannesburg), (3) Inkosi Albert Luthuli Central Hospital (Durban), (4) Addington Hospital (Durban), (5) Ngwelezane Hospital (Empangeni) and (6) Grey's Hospital (Pietermaritzburg).[21,22] This retrospective analysis focuses on data collected from January 2016 to December 2022, including females aged 18 years – 40 years who were enrolled at the CHBAH site and subsequently diagnosed with BC.

Chris Hani Baragwanath Academic Hospital, commonly referred to as Bara, located at 26 Chris Hani Road, Diepkloof, Soweto, Johannesburg, was established in September 1942.[23] It is the largest hospital in the southern hemisphere, spanning 173 acres with approximately 3200 beds and over 6760 staff members.[23] The hospital serves millions of residents in Soweto and is a teaching facility affiliated with the University of the Witwatersrand.[23]

We included all females aged 18 years – 40 years with newly diagnosed BC who underwent diagnostic imaging (breast ultrasound and followed by mammogram for suspicious lesions with a BI-RADS of $\geq$ 3) and histopathological confirmation. Patients with bilateral BC were included if they fulfilled the study inclusion criteria. Imaging findings and histopathological diagnoses were assessed according to the lesion undergoing diagnostic evaluation and biopsy confirmation. We excluded females who were known to have a BC diagnosis (BI-RADS 6) where imaging was used solely for surgical planning, those unable to provide informed consent and females with missing BI-RADS classification or absence of histological diagnostic reports. The BI-RADS assessments were made based on breast imaging findings and not on lymph node involvement.

This retrospective study was conducted at CHBAH, and the study forms part of the doctoral thesis completed by the third author at the University of the Witwatersrand.

Data collection

De-identified sociodemographic and clinical data were extracted from patient records. Collected variables

included: (1) sociodemographic characteristics (age and year of diagnosis), (2) risk factors (fibroglandular tissue composition), (3) clinical characteristics (BI-RADS classification), (4) clinical stage and (5) histological diagnosis from core biopsy (including cancer type and stage at diagnosis). Mammography and ultrasound-histological concordance were defined as cases with BI-RADS 4 or BI-RADS 5 assessments confirmed as malignant on core biopsy.

Descriptive statistics were generated using Stata version 16. Means ± standard deviation (s.d.) were calculated for continuous variables, and median (interquartile range [IQR]) was used for skewed data. Categorical variables were summarised using frequencies and percentages.

Ethical considerations

Ethical approval for this study was granted by the University of the Witwatersrand Human Research Ethics Committee (Reference Number: M230971).

Results

Three hundred and fifty-four females aged ≤ 40 years were diagnosed with BC at CHBAH during the study period. Of these, 28 had missing BI-RADS data and were excluded, as were a further 17 females with a known BC diagnosis (BI-RADS 6) for whom imaging was performed to assist surgical treatment. A total of 309 females were included in the final analysis (Figure 1).

The mean ± s.d. age was 35.2 ± 3.9 years, with categorical age distributions of 13.6% for ≤ 30 years of age, 32.0% for ages 31 years – 35 years and 54.4% for those aged 36 years – 40 years. The percentage of females ≤ 40 years diagnosed with BC per year from 2016 to 2022 ranged from 10.7% to 19.7%, with 2021 having the highest percentage. The percentage of females aged ≤ 40 years per year was thus not unduly affected by the coronavirus disease 2019 (COVID-19) pandemic lockdown period, which began in March 2020 (Table 1).

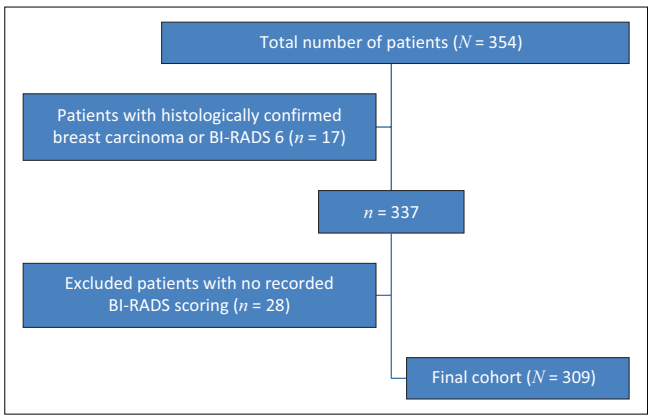

BI-RADS, Breast Imaging Reporting and Data System.

FIGURE 1: Flow chart of patients enrolled in the South African Breast Cancer and HIV Outcomes study at the Chris Hani Baragwanath Academic Hospital site for the period January 2016 to December 2022.

The prevalence of HIV in the cohort at diagnosis was 40.0%; of these, 74.0% were previously diagnosed with HIV and on antiretroviral therapy (ART), and 26.0% were newly diagnosed with HIV.

Clinical characteristics of the cohort are summarised in Table 2. Most patients presented with advanced-stage disease, comprising 48% with stage III (locally advanced) disease and 12 % with stage IV disease.

A concordance rate of 97.7% was observed between bimodal BI-RADS assessment and histopathological diagnosis. Notably, all discordant cases occurred in patients with non-metastatic stage I, stage II and stage III disease (Figure 3).

Discussion

This study evaluated the concordance between bimodal BI-RADS imaging assessment and histopathological diagnosis in females aged 40 years and younger presenting with BC at a tertiary referral centre in South Africa. A high level of agreement was observed between combined mammography and breast ultrasound-based BI-RADS classification and histopathological confirmation of malignancy. These findings support the utility of multimodal breast imaging in the diagnostic evaluation of young females, a population in whom image interpretation may be complicated by dense breast tissue and overlapping benign imaging characteristics.[24,25,26] Similarly, Dehar et al. reported that ultrasound combined with diagnostic mammography represents an appropriate imaging strategy for evaluating breast symptoms in females aged 30 years – 50 years.[27]

Although discordance between imaging assessment and histopathological diagnosis occurred in only a small proportion of cases, these findings remain clinically important. Dense fibroglandular tissue may obscure subtle lesions on mammography, thereby reducing the conspicuity of malignant masses. Furthermore, certain BCs may demonstrate atypical or less suspicious imaging features, including relatively smooth or well-circumscribed margins, potentially resulting in lower BI-RADS categorisation despite underlying malignancy. These limitations underscore the

TABLE 1: Sociodemographic characteristics of females ≤40 years old diagnosed with breast cancer at Chris Hani Baragwanath Academic Hospital for the period January 2016 to December 2022 (*N* = 309).

Characteristics	*N*	%	Mean	s.d.
Age (years)	-	-	35.2	± 3.9
≤30	42	13.6	-	-
31–35	99	32.0	-	-
36–40	168	54.4	-	-
Year of diagnosis				
2016	37	11.9	-	-
2017	33	10.7	-	-
2018	54	17.5	-	-
2019	42	13.6	-	-
2020	39	12.6	-	-
2021	61	19.7	-	-
2022	43	13.9	-	-

s.d., standard deviation.

TABLE 2: Clinical characteristics of females ≤40 years old in the South African Breast Cancer and HIV Outcomes cohort (Chris Hani Baragwanath Academic Hospital) for the period January 2016 to December 2022 (N = 309).

Characteristics	N	%
HIV status (*n* = 300)		
Negative	180	60.0
Positive	120	40.0
HIV-positive proportion on ART (self-reported) (*n* = 120)		
No	31	25.8
Yes	89	74.2
Clinical stage at diagnosis (*n* = 308)		
I	13	4.2
II	108	34.9
III	149	48.2
IV	38	12.3
Side of breast cancer (*n* = 308)		
Left	149	48.2
Right	159	51.5
Histological diagnosis (*n* = 309)		
DCIS	6	1.9
Invasive ductal	289	93.5
Invasive lobular	8	2.6
Other histological types	6	1.9
Breast composition or fibroglandular tissue categories (*n* = 218)		
A	18	8.2
B	133	61.0
C	52	23.9
D	14	6.4
B–C	1	0.5
Mammography BI-RADS category (*n* = 309)		
BI-RADS 2	2	0.6
BI-RADS 3	5	1.6
BI-RADS 4	62	20.1
4A	5	-
4B	14	-
4C	43	-
BI-RADS 5	240	77.7
Mammogram concordance with histologically confirmed BC diagnosis (*n* = 309)		
No (BI-RADS 2–3)	7	2.3
Yes (BI-RADS 4–5)	302	97.7

Note: Missing: HIV status (*n* = 9), clinical stage at diagnosis (*n* = 1), side of BC (*n* = 1), breast composition or fibroglandular tissue categories (*n* = 91).

ART, antiretroviral therapy; DCIS, ductal carcinoma in situ; BI-RADS, Breast Imaging Reporting and Data System; BC, breast cancer.

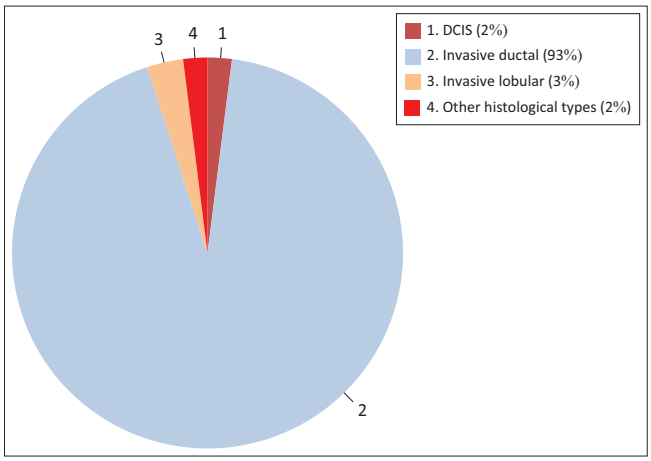

Note: Other histological subtypes (metaplastic [*n* = 2], mucinous [*n* = 3]).

DCIS, Ductal carcinoma in situ.

FIGURE 2: Pie chart showing the distribution of the histology of females ≤40 years diagnosed with breast cancer in the South African Breast Cancer and HIV Outcomes cohort from January 2016 to December 2022.

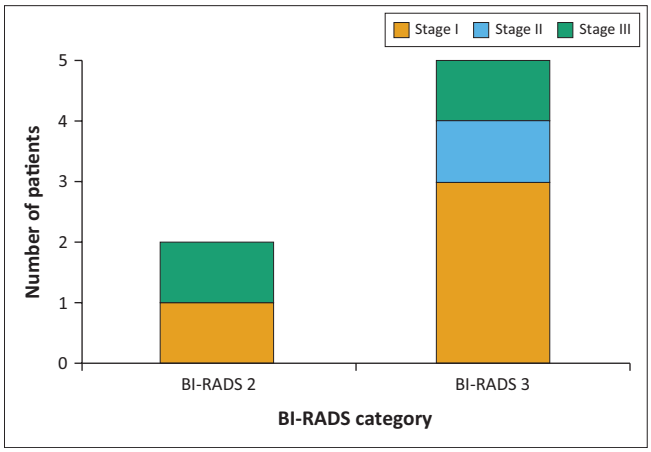

BI-RADS, Breast Imaging Reporting and Data System.

FIGURE 3: Distribution of discordant Breast Imaging Reporting and Data System classifications according to clinical stage among females with biopsy-confirmed breast cancer in the South African Breast Cancer and HIV Outcomes cohort at the Chris Hani Baragwanath Academic Hospital site, for the period January 2016 to December 2022.

importance of correlating imaging findings with clinical assessment and maintaining a low threshold for tissue diagnosis when clinical or radiological suspicion persists.

Recent evidence suggests that contrast-enhanced mammography may improve lesion detection in females with dense breast tissue by highlighting tumour vascularity and improving lesion conspicuity.[28] Although this modality was not assessed in the present study, it may represent a valuable adjunct to conventional breast imaging in healthcare settings where access to MRI remains limited. Additional emerging imaging techniques, including ultrasound elastography, automated breast ultrasound (ABUS), artificial intelligence (AI)-assisted imaging, molecular breast imaging and radiomics, may further enhance breast imaging performance and diagnostic accuracy in the SSA public healthcare sector.

The demographic profile of this cohort is consistent with patterns reported in other studies of BC among young females. The age distribution observed in this study is comparable to findings by Sabiani et al., who reported a similar mean age among young BC patients.[29] These findings further support the recognition of BC in females younger than 40 years as a clinically distinct subgroup that may require tailored diagnostic and management approaches.

Breast cancer diagnosed at younger ages is frequently associated with more aggressive tumour biology and a more advanced stage at presentation. The predominance of locally advanced disease observed in this cohort mirrors findings from other studies conducted in low-income and middle-income countries, where delayed presentation, limited screening programmes and reduced awareness of early symptoms contribute to later-stage diagnosis.[30,31,32] These findings underscore the importance of reliable imaging pathways that support early evaluation of suspicious breast

abnormalities and facilitate timely histopathological confirmation.

A substantial proportion of females in this cohort were HIV positive, reflecting the ongoing intersection between HIV and BC in South Africa. Previous South African studies have demonstrated that WLWH may present with BC at a younger age and with more advanced-stage disease than their HIV-negative counterparts.[33,34,35] Although the present study was not designed to evaluate the influence of HIV status on BI-RADS classification, imaging concordance or stage at presentation, the high HIV prevalence observed highlights the importance of integrated oncological and HIV care pathways. Further research is warranted to determine whether HIV infection influences imaging characteristics, diagnostic concordance or patterns of disease presentation in young females with BC.

Tumour laterality did not demonstrate a clear predominance in this cohort, in contrast to reports describing a higher frequency of left-sided BCs.[36] Abdou et al. previously reported associations between left-sided BC and more aggressive tumour biology, as well as potential long-term treatment implications related to radiation exposure.[36] The absence of a clear laterality pattern in the present study may reflect population-specific variation in BC presentation.

The histological profile observed in this cohort was consistent with established epidemiological patterns, with invasive ductal carcinoma representing the predominant tumour subtype (Figure 2). This finding aligns with global data identifying invasive ductal carcinoma as the most common histological form of BC worldwide.[37] Similar observations have been reported in African populations, suggesting that the histological spectrum of BC in younger females remains broadly comparable to that seen in the general BC population.[38]

Several previous studies have evaluated the concordance and predictive utility of BI-RADS classification in identifying breast malignancy. Chavan et al. reported a high agreement between BI-RADS assessment and histopathological diagnosis in females presenting with breast lumps although their cohort included a broader age range extending to 75 years.[39] Studies focusing specifically on younger females have generally demonstrated slightly lower concordance rates, likely reflecting the challenges associated with dense breast tissue and less conspicuous imaging features in this population. Similarly, Wang et al. reported an 84.4% concordance between mammography and histopathology in females under the age of 40 years.[40]

Given the limited literature from SSA, these findings contribute important context-specific data regarding the concordance between bimodal BI-RADS assessment and histopathological diagnosis in young females presenting with BC, consistent with findings from recent radiological-pathological correlation studies.[41,42]

The clinical utility of BI-RADS classification in stratifying the likelihood of malignancy has been well established. The seminal work by Orel et al. demonstrated a strong association between BI-RADS categorisation and histopathological malignancy.[43,44] The predominance of BI-RADS 5 lesions in the present cohort likely reflects the symptomatic nature of disease presentation in this population, where patients commonly present with clinically apparent breast masses rather than screen-detected abnormalities.

Breast density remains an important consideration in imaging younger females, as increased fibroglandular tissue may reduce mammographic sensitivity.[45] Despite the recognised limitation, the findings of the present study support the continued utility of combined mammography and ultrasound in the evaluation of breast lesions within this population.

These findings are particularly relevant in resource-limited healthcare settings, where access to advanced imaging modalities such as breast MRI remains limited. In many South African public sector hospitals, mammography and ultrasound continue to form the foundation of breast imaging assessment. Optimising the use of these readily available modalities within a structured BI-RADS framework may assist in guiding biopsy decisions and facilitating timely histopathological diagnosis and management of BC.[46,47]

Strengths and limitations

A key strength of this study is its setting in the largest hospital in the southern hemisphere, enabling access to a substantial cohort of young females affected by the most common female malignancy. However, the sample size limited further analysis of variables that might influence the concordance between bimodal BI-RADS assessment and histopathological diagnosis. The retrospective design of this study introduces the possibility of selection and information bias. In addition, our study was conducted at a single tertiary referral centre, which may limit the generalisability of the findings to other healthcare settings. Imaging interpretation may also be subject to inter-observer variability, which was not formally assessed in this analysis.

As the cohort was restricted to females with biopsy-confirmed breast malignancies, the findings do not constitute a comprehensive assessment of diagnostic performance measures such as sensitivity or specificity. The reported concordance reflects agreement between bimodal BI-RADS assessment and histopathological diagnosis within a malignant cohort and may be interpreted as reflecting the positive predictive value of suspicious imaging findings in this population. Because benign and false-positive cases were not included, false-positive rates and specificity could not be assessed.

Implications and recommendations

Breast cancer in females aged ≤40 years represents an important clinical challenge in SSA, where many patients continue to present with advanced-stage disease. The high concordance observed between bimodal BI-RADS assessment and histopathological diagnosis in this study supports the continued use of combined mammography and ultrasound in the evaluation of suspicious breast lesions in young females. Efforts to promote earlier presentation, increase BC awareness and facilitate timely access to diagnostic imaging and biopsy services may contribute to earlier diagnosis and improved clinical outcomes in this population.

Conclusion

In conclusion, this study demonstrated a high level of concordance between bimodal BI-RADS imaging assessment and histopathological diagnosis in females aged ≤40 years with biopsy-confirmed BC. These findings support the utility of combined breast ultrasound and mammography in the evaluation of supicious breast lesions in young females. In resource-constrained healthcare settings, the effective use of these widely available imaging modalities remains essential for facilitating timely diagnosis and management of BC.

Acknowledgements

The authors would like to express their sincere gratitude to the South African Breast Cancer and HIV Outcomes (SABCHO) study team for their contribution to data collection and management. The authors thank the women who participated in this study. Their courage and willingness to share their medical journeys have not only advanced the understanding of BC in young females but will hopefully contribute to better diagnostic and treatment outcomes for future patients.

This article is based on research originally conducted as part of Oluwatosin A. Ayeni's doctoral thesis titled 'Multimorbidity and breast cancer in sub-Saharan Africa: Profile and impact on stage at diagnosis and breast cancer treatment decisions', submitted to the Faculty of Health Sciences, University of the Witwatersrand in 2021. The thesis was supervised by Shane Norris and Maureen Joffe. The supervisor Shane Norris was not involved in the preparation of this article and were not listed as co-authors. The thesis was reworked, revised, and adapted into a journal article for publication. The original thesis is available at: https://wiredspace.wits.ac.za/server/api/core/bitstreams/95048b76-0392-4a39-bb8c-a30ae83b1627/content, and three journal articles were published from the thesis.

Competing interests

The authors declare that they have no financial or personal relationships that may have inappropriately influenced them in writing this article.

CRediT authorship contribution

Yvonne K. Ruhinda-Radebe: Conceptualisation, Data curation, Formal analysis, Investigation, Methodology, Project administration, Visualisation, Writing – original draft. Maureen Joffe: Supervision, Writing – review & editing. Oluwatosin A. Ayeni: Supervision, Formal analysis, Writing – review & editing. Thandi E. Buthelezi: Supervision, Writing – review & editing. All authors reviewed the article, contributed to the discussion of results, approved the final version for submission and publication and take responsibility for the integrity of its findings.

Funding information

The authors received no financial support for the research, authorship and/or publication of this article.

Data availability

The data that support the findings of this study are not openly available and are available from the corresponding author, Yvonne K. Ruhinda-Radebe, upon reasonable request.

Disclaimer

The views and opinions expressed in this article are those of the authors and are the product of professional research. They do not necessarily reflect the official policy or position of any affiliated institution, funder, agency or that of the publisher. The authors are responsible for this article's results, findings and content.

References

1. Sung H, Filho AM, Laversanne M, et al. Global cancer statistics 2024: GLOBOCAN estimates of incidence and mortality worldwide for 34 cancers in 186 countries. CA Cancer J Clin. 2026;e70090. https://doi.org/10.3322/caac.70090
2. Anyigba CA, Awandare GA, Paemka L. Breast cancer in sub-Saharan Africa: The current state and uncertain future. Exp Biol Med. 2021;246(12):1377–1387. https://doi.org/10.1177/15353702211006047
3. McCormack VA, Febvey-Combes O, Ginsburg O, Dos-Santos-Silva I. Breast cancer in women living with HIV: A first global estimate. Int J Cancer. 2018;143(11): 2732–2740. https://doi.org/10.1002/ijc.31722
4. Cancer Association of South Africa (CANSA). Incidence of cancer in South Africa according to the National Cancer Registry - 2024 [Internet]. Johannesburg: CANSA; 2026 [cited 2026 Aug 29]. Available from: https://www.cansa.org.za/files/2026/04/Incidence-of-Cancer-in-South-Africa-According-to-the-National-Cancer-Registry-2024.pdf
5. Grover S, Martei YM, Puri P, et al. Breast cancer and HIV in sub-Saharan Africa: A complex relationship. J Glob Oncol. 2018;4:1–11. https://doi.org/10.1200/JGO.2016.006585
6. Mapanga W, Norris SA, Craig A, et al. Drivers of disparities in stage at diagnosis among women with breast cancer: South African breast cancers and HIV outcomes cohort. PLoS One. 2023;18(2):e0281916. https://doi.org/10.1371/journal.pone.0281916
7. Reddy P, Ebrahim S, Singh B, Ramklass S, Buccimazza I. Breast cancer and HIV: A South African perspective and a critical review of the literature. S Afr J Surg. 2017;55(1):10–15.
8. Dia JM, Touré M, Yao I, et al. Breast cancers in young woman under 40 years in sub-Saharan Africa: Experience of the Gynecology Department of the University and Hospital Center of Treichville (Abidjan – Cote d'Ivoire). J Cancer Ther. 2017; 8(8):714–725. https://doi.org/10.4236/jct.2017.88062
9. Cathcart-Rake EJ, Ruddy KJ, Bleyer A, Johnson RH. Breast cancer in adolescent and young adult women under the age of 40 years. JCO Oncol Pract. 2021;17(6): 305–313. https://doi.org/10.1200/OP.20.00793
10. Eiriz IF, Vaz Batista M, Cruz Tomás T, Neves MT, Guerra-Pereira N, Braga S. Breast cancer in very young women – A multicenter 10-year experience. ESMO Open. 2021;6(1):100029. https://doi.org/10.1016/j.esmoop.2020.100029

11. Lee HB, Han W. Unique features of young age breast cancer and its management. J Breast Cancer. 2014;17(4):301–207. https://doi.org/10.4048/jbc.2014.17.4.301
12. Mccarthy AM, Keller BM, Pantalone LM, et al. Racial differences in quantitative measures of area and volumetric breast density. J Natl Cancer Inst. 2016;108(10): djw104. https://doi.org/10.1093/JNCI/DJW104
13. Salem DS, Kamal RM, Mansour SM, Salah LA, Wessam R. Breast imaging in the young: The role of magnetic resonance imaging in breast cancer screening, diagnosis and follow-up. J Thorac Dis. 2013;5(Suppl. 1):S9–S18. https://doi.org/10.3978/j.issn.2072-1439.2013.05.02
14. Nascimento RG, Otoni KM. Histological and molecular classification of breast cancer: What do we know? Mastology. 2020;30:e20200024. https://doi.org/10.29289/25945394202020024
15. Surridge CA, Goodier MDM. An analysis of diagnostic practices in a mammography unit in a tertiary hospital in South Africa. S Afr J Radiol. 2017;21(1):a1059. https://doi.org/10.4102/sajr.v21i1.1059
16. American Society of Clinical Oncology (ASCO). Guidelines [Internet]. Alexandria (VA): ASCO; 2025 [cited 2025 Apr 4]. Available from: https://www.asco.org/guidelines?categories=Breast%20Cancer
17. National Comprehensive Cancer Network (NCCN). Recently updated guidelines [Internet]. Plymouth Meeting (PA): NCCN; 2025 [cited 2025 Apr 4]. Available from: https://www.nccn.org/guidelines/recently-published-guidelines
18. South African National Department of Health. Breast Cancer Prevention and Control Policy [homepage on the Internet]. Pretoria: National Department of Health; 2017 [cited 2025 Jan 12]. Available from: https://knowledgehub.health.gov.za/system/files/elibdownloads/2023-04/Breast-Cancer-Policy-2017.pdf
19. Devolli-Disha E, Manxhuka-Kërliu S, Ymeri H, Kutllovci A. Comparative accuracy of mammography and ultrasound in women with breast symptoms according to age and breast density. Bosn J Basic Med Sci. 2009;9(2):131–136. https://doi.org/10.17305/bjbms.2009.2832
20. Mann RM, Cho N, Moy L. Breast MRI: State of the art. Radiology. 2019;292(3): 520–536. https://doi.org/10.1148/radiol.2019182947
21. Mapanga W, Ayeni OA, Chen WC, et al. The South African breast cancer and HIV outcomes study: Profiling the cancer centres and cohort characteristics, diagnostic pathways, and treatment approaches. PLOS Glob Public Health. 2023;3(10): e0002432. https://doi.org/10.1371/JOURNAL.PGPH.0002432
22. Cubasch H, Ruff P, Joffe M, Norris S, Chirwa T, Nietz S, et al. South African breast cancer and HIV outcomes study: Methods and baseline assessment. J Glob Oncol. 2017;3(2):114–124. https://doi.org/10.1200/JGO.2015.002675
23. Chris Hani Baragwanath Academic Hospital Trauma Directorate. About [Internet]. 2024 [cited 2025 Sep 28]. Available from: https://www.baragwanathtrauma.com/aboutus
24. Boyd NF, Guo H, Martin LJ, et al. Mammographic density and the risk and detection of breast cancer. N Engl J Med. 2007;356(3):227–236. https://doi.org/10.1056/NEJMOA062790
25. Ghaemian N, Tehrani NHG, Nabahati M. Accuracy of mammography and ultrasonography and their BI-RADS in detection of breast malignancy. Caspian J Intern Med. 2021;12(4):573–579. https://doi.org/10.22088/CJIM.12.4.573
26. American College of Radiology. ACR BI-RADS® Atlas: Breast Imaging Reporting and Data System. 5th ed. Reston (VA): American College of Radiology; 2013.
27. Dehar N, Jabs D, Hopman W, Mates M. A retrospective analysis of diagnostic breast imaging outcomes in young women at a Tertiary Care Center. Curr Oncol. 2024;31(7):3939–3948. https://doi.org/10.3390/CURRONCOL31070291
28. Patel BK, Lobbes MBI, Lewin J. Contrast enhanced spectral mammography: A review. Semin Ultrasound CT MRI. 2018;39(1):70–79. https://doi.org/10.1053/J.SULT.2017.08.005
29. Sabiani L, Houvenaeghel G, Heinemann M, et al. Breast cancer in young women: Pathologic features and molecular phenotype. Breast. 2016;29:109–116. https://doi.org/10.1016/j.breast.2016.07.007
30. Hussein A, Khoury KE, Dbouk H, Khalil LE, Mouhieddine TH, El Saghir NS. Epidemiology and prognosis of breast cancer in young women. J Thorac Dis. 2013;5(Suppl 1):S2–S8. https://doi.org/10.3978/j.issn.2072-1439.2013.05.24
31. Chaane N, Kuehnast M, Rubin G. An audit of breast cancer in patients 40 years and younger in two Johannesburg academic hospitals. S Afr J Radiol. 2024;28(1):a2772. https://doi.org/10.4102/SAJR.V28I1.2772
32. Roodt L, Malherbe F. Breast cancer in young African Women: Unique challenges and perspectives. J Young Womens Breast Cancer Health. 2024;1(1 & 2):27–35. https://doi.org/10.4103/YWBC.YWBC_5_24
33. Ayeni OA, Joffe M, Mapanga W, et al. Multimorbidity and overall survival among women with breast cancer: Results from the South African Breast Cancer and HIV Outcomes Study. Breast Cancer Res. 2023;25(1):7. https://doi.org/10.1186/S13058-023-01603-W
34. Phakathi B, Cubasch H, Nietz S, et al. Clinico-pathological characteristics among South African women with breast cancer receiving anti-retroviral therapy for HIV. Breast. 2019;43:123–129. https://doi.org/10.1016/J.BREAST.2018.12.005
35. Van Zyl N, Minné C, Mokone DH. Human immunodeficiency virus infection in breast cancer patients: The prevalence thereof and its effect on breast cancer characteristics at Dr. George Mukhari Academic Hospital Breast Clinic, Ga-Rankuwa, South Africa. S Afr J Radiol. 2018;22(2):a1361. https://doi.org/10.4102/SAJR.V22I2.1361
36. Abdou Y, Gupta M, Asaoka M, et al. Left sided breast cancer is associated with aggressive biology and worse outcomes than right sided breast cancer. Sci Rep. 2022;12(1):13377. https://doi.org/10.1038/s41598-022-16749-4
37. World Health Organization (WHO). Breast cancer [Internet]. Geneva: World Health Organization; 2026 [cited 2026 Mar 13]. Available from: https://www.who.int/news-room/fact-sheets/detail/breast-cancer
38. Jedy-Agba E, McCormack V, Adebamowo C, Dos-Santos-Silva I. Stage at diagnosis of breast cancer in sub-Saharan Africa: A systematic review and meta-analysis. Lancet Glob Health. 2016;4(12):e923–e935. https://doi.org/10.1016/S2214-109X(16)30259-5
39. Chavan SG, Sree Ganesh B, Vemuri N. Diagnosis of breast lumps based on breast imaging reporting and data system score and histopathological examination: A comparative study. Int Surg J. 2019;7(1):144–149. https://doi.org/10.18203/2349-2902.isj20195960
40. Wang J, Chang KJ, Kuo WH, Lee HT, Shih TT-F. Efficacy of mammographic evaluation of breast cancer in women less than 40 years of age: Experience from a single medical center in Taiwan. J Formos Med Assoc. 2007;106(9):736–747. https://doi.org/10.1016/S0929-6646(08)60035-2
41. Ghunaim HA, Alatawi RE, Borhan WM, et al. Accuracy of imaging of BI-RADS 4 subcategorizations in breast lesion diagnosis: Radiologic-pathologic correlation. Saudi Med J. 2024;45(11):1228. https://doi.org/10.15537/SMJ.2024.45.11.20240001
42. Jaber HH, Muner QAE-R. Predictive value of ultrasound BIRADS in conjunction with cytological and histopathological outcomes in breast disease management. Surg Open Sci. 2025;27:171–178. https://doi.org/10.1016/J.SOPEN.2025.08.005
43. Orel SG, Kay N, Reynolds C, Sullivan DC. BI-RADS categorization as a predictor of malignancy1. Radiology. 1999;211(3):845–850. https://doi.org/10.1148/radiology.211.3.r99jn31845
44. Zonderland H, Smithuis R. BI-RADS for mammography and ultrasound 2013 [Internet]. Amsterdam: The Radiology Assistant; 2014 [cited 2025 Jan 12]. Available from: https://radiologyassistant.nl/breast/bi-rads/bi-rads-for-mammography-and-ultrasound-2013
45. Lin J, Ye S, Ke H, et al. Changes in the mammary gland during aging and its links with breast diseases: Aged mammary gland and breast diseases. Acta Biochim Biophys Sin. 2023;55(6):1001–1019. https://doi.org/10.3724/ABBS.2023073
46. Dan Q, Zheng T, Liu L, Sun D, Chen Y. Ultrasound for breast cancer screening in resource-limited settings: Current practice and future directions. Cancers. 2023;15(7):2112. https://doi.org/10.3390/CANCERS15072112
47. Sardanelli F, Magni V, Rossini G, Kilburn-Toppin F, Healy NA, Gilbert FJ. The paradox of MRI for breast cancer screening: High-risk and dense breasts-available evidence and current practice. Insights Imaging. 2024;15(1):96. https://doi.org/10.1186/S13244-024-01653-4