African Vision and Eye Health
ISSN: (Online) 2410-1516, (Print) 2413-3183

Early implementation of gonioscopy-assisted transluminal trabeculotomy for glaucoma in Kibagabaga District Hospital, Rwanda

Check for updates

Authors:
Agnes C. Owete[1,2]
Eric Manirakiza[2,3]
Leon W. Herndon[1]
John M. Cropsey[2]

Affiliations:
[1]Department of Ophthalmology, Duke University Eye Centre, Duke Hospital, Durham, NC, United States

[2]Rwanda International Institute of Ophthalmology, Kigali, Rwanda

[3]Department of Ophthalmology, Hôpital Espoir de Kibuye, Hope Africa University, Kibuye, Burundi

Corresponding author:
Agnes Owete,
agnes.owete@duke.edu

Dates:
Received: 10 Dec. 2025
Accepted: 30 Mar. 2026
Published: 15 May 2026

How to cite this article:
Owete AC, Manirakiza E, Herndon LW, Cropsey JM. Early implementation of gonioscopy-assisted transluminal trabeculotomy for glaucoma in Kibagabaga District Hospital, Rwanda Afr Vision Eye Health. 2026;85(1), a1155. https://doi.org/10.4102/aveh.v85i1.1155

Copyright:
© 2026. The Author(s). Licensee: AOSIS. This work is licensed under the Creative Commons Attribution 4.0 International (CC BY 4.0) license (https://creativecommons.org/licenses/by/4.0/).

Read online:
Scan this QR code with your smart phone or mobile device to read online.

Background: Glaucoma is a progressive, vision-threatening condition that can be managed with topical treatments initially but often eventually requires surgical management.

Aim: This study aimed to review the efficacy and safety of the first gonioscopy-assisted transluminal trabeculotomy (GATT) operations in Rwanda. This is a retrospective case series.

Setting: Out of 260 consecutive surgical records dated between 01 January 2023 and 28 August 2023, 11 eyes that had undergone GATT procedures were identified and included in this study. These were the first patients to undergo GATT in Rwanda.

Methods: All available pre-operative, operative and post-operative data were collected and reported for visits through 01 February 2024. Cases were classified as either a success, a qualified success or a failure based on pre-determined criteria. Outcomes included post-operative intraocular pressure (IOP) at multiple time points, the number of glaucoma medications needed post-GATT, the number of glaucoma surgeries post-GATT, visual acuity and post-operative complications.

Results: Patients had an average IOP decrease of 13 mmHg (standard deviation = 6.8) at 3 months post-operation compared with pre-operation IOP on medical treatment. Eight eyes (73%) achieved complete success, two eyes (18%) achieved qualified success and one eye met failure criteria (9%). No patients had a decline in visual acuity at the last visit after receiving GATT. Two cases of IOP spike (18%) were noted (both resolved within 1-week post-operation), two cases of hyphema (18%) and one case each of mild corneal oedema (9%) and a small Descemet detachment (9%).

Conclusion: Gonioscopy-assisted transluminal trabeculotomy is a useful tool in the arsenal of pressure-reducing treatments with unique utility in lower-resource settings.

Contribution: This retrospective analysis of the first 11 cases of GATT in Rwanda demonstrates GATT as a safe and feasible tool for the treatment of glaucoma, with specific utility in lower-resource settings.

Keywords: minimally invasive glaucoma surgery; global ophthalmology; glaucoma; glaucoma outcomes research; trabeculotomy; glaucoma treatment; global surgery; eye health.

Introduction

Background

Gonioscopy-assisted transluminal trabeculotomy (GATT) is a minimally invasive glaucoma surgery (MIGS) with impressive potential for treatment in lower-resource settings. We report the first cases of GATT in Kigali, Rwanda.

Gonioscopy-assisted transluminal trabeculotomy is a time and cost-effective, one-time procedure that safely reduces intraocular pressure (IOP), making it an ideal and accessible treatment for glaucoma. Minimally invasive glaucoma surgeries are rapidly changing the landscape of glaucoma care; however, many of these procedures require devices that are associated with high costs. Gonioscopy-assisted transluminal trabeculotomy is a MIGS technique that utilises an ab-interno suture or catheter to create a 360-degree trabeculotomy, first described by Grover et al.[1,2] When successful, the cannulation and opening of the trabecular meshwork reduces IOP while

Note: Additional supporting information may be found in the online version of this article as Online Appendix 1.

sparing the conjunctiva and sclera if trabeculectomy is later needed.[1,2] Importantly, this technique does not necessitate a specific device or implant; instead, a simple 5-0 Prolene suture can be used to create the trabeculotomy.

Gonioscopy-assisted transluminal trabeculotomy has been found to be as effective as, or more effective than, other MIGS procedures in reducing IOP and treating multiple types of glaucoma.[2,3,4] When compared with trabeculectomy, there is a lower risk of postoperative hypotony, suture complications and bleb-related complications.[5] Gonioscopy-assisted transluminal trabeculotomy is also more cost-effective than other MIGS techniques, not requiring specific devices or implants, making it of particular utility in lower-resource settings, which often have higher incidences of glaucoma and more advanced disease.[6,7,8] Identifying effective and accessible therapeutic and surgical strategies to address the burden of glaucoma in low- and middle-income countries is a global ophthalmology imperative.

We report a retrospective case series reviewing the outcomes of the first 11 eyes to undergo GATT surgeries in Rwanda. The surgeries were performed at the Kibagabaga District Hospital a public teaching hospital, in Kigali, Rwanda, with ophthalmologists from the Rwanda International Institute of Ophthalmology. Kibagabaga Hospital was the only institution in Rwanda offering this procedure at the time of the study. We present the preliminary results to assess the specific utility of this procedure in the regional and socioeconomic context of East Africa.

Research methods and design

We conducted a retrospective analysis of the first 11 consecutive eyes from nine patients who underwent GATT at Kibagabaga Hospital between 01 January 2023 and 28 August 2023. Patients were identified using manual review of electronic and paper surgical records (using the key terms 'GATT' and 'gonioscopy assisted transluminal trabeculotomy'). Glaucoma was diagnosed in patients with characteristic optic nerve head changes, visual field defects and thinning of the retinal nerve fibre layer as measured by optical coherence tomography. Gonioscopy was performed on all patients. Exclusion criteria for consideration of GATT as a treatment option included active neovascular glaucoma and lack of an adequate view of the angle on gonioscopy (including due to cicatricial angle closure) to perform GATT safely. A total of 260 eye surgeries were performed at Kibagabaga during this period, of which 11 were GATT procedures. The full surgical technique is described in Online Appendix 1. A summary of the technique is as follows: Using a surgical, direct-viewing gonioscopy lens, a 23G needle was passed into the anterior chamber and used to perform a 2 mm – 3 mm nasal goniotomy. 5-0 Prolene suture (needle removed and blunted) was threaded into the goniotomy incision using 23G intraocular forceps. The proximal flanged end of the suture was retrieved at the goniotomy incision. While holding the flanged end intraocularly, the extraocular, distal end of the suture was grasped with a needle driver and pulled, tearing the intraocular suture through the trabecular meshwork. This created a 360-degree, ab interno goniotomy.

All patients were recommended to follow-up at a minimum on post-operative day 1 (POD1), post-operative week 1 (POW1), post-operative month 1 (POM1) and post-operative month 3 (POM3). These intervals were modelled with few modifications after the original Grover et al. paper describing this surgical technique, unless specific post-operative concerns merited closer follow-up.[3,7] All available data were collected and reported from visits through 01 February 2024. All patients had at least one visit more than 3 months post-operatively that included a full exam, apart from one patient who was lost to follow-up (LTFU).

Our primary outcome was IOP reduction from medically treated, baseline pre-operative IOP on the last exam before surgery. An outcome of complete success was defined as a post-operative IOP between 5 mmHg and 21 mmHg while demonstrating at least a 20% reduction from pre-operative baseline IOP (after POM1) without glaucoma medication or further glaucoma procedures (Table 1). A qualified success was defined as an IOP between 5 mmHg and 21 mmHg with a 20% lowering from baseline IOP with glaucoma medication after POM1. Failure was defined as IOP $\geq$ 21 mmHg and < 5 mmHg at the last visit, worsening of vision from baseline at the last visit or the need for additional glaucoma surgery[7,9](Table 1). Other outcomes of interest included the number of glaucoma medications needed post-GATT, the number of surgeries post-GATT and visual acuity. Intraocular pressure was measured either using an iCare tonometer (Vantaa, Finland) or with Goldmann applanation (Haag-Streit Diagnostics, Switzerland) by ophthalmology residents at Kibagabaga.

Study data were collected and managed using REDCap electronic data capture tools hosted at the Perelman School of Medicine.[10,11] Research Electronic Data Capture (REDCap; Vanderbilt University, Nashville, TN, United States) is a secure, web-based software platform designed to support data capture for research studies, providing: (1) an intuitive interface for validated data capture; (2) audit trails for tracking data manipulation and export procedures; (3) automated export procedures for seamless data downloads to common statistical packages; and (4) procedures for data integration and interoperability with external sources.

The data collected were entered, analysed and processed using Stata BE statistical software, version 18.0 (StataCorp, College Station, TX, United States). The *p*-value and 95% confidence interval were calculated, and a Chi-square test with Fisher's exact test was used to compare success across surgical categories, given the small sample size. Results were statistically significant when the *p*-value was < 0.05.

Ethical considerations

This study was determined to be non-human subjects research and was approved by the Institutional Review

TABLE 1: Criteria for outcomes of success, qualified success and failure.

Success	Qualified success	Failure
5 < IOP < 21 mmHg and ≥ 20% reduction from baseline IOP on no glaucoma medications (after POM1) nor further glaucoma procedures	5 < IOP < 21 mmHg AND ≥ 20% reduction from baseline IOP on glaucoma medications (after POM1)	IOP ≥ 21 mmHg or < 5 mmHg at the last visit, or worsening of vision from baseline at the last visit, and need for additional glaucoma surgery

Source: Adapted from Shaarawy T, Grehn F, Sherwood M. WGA guidelines on design and reporting of glaucoma surgical trials [Internet]. The Hague: Kugler Publications; 2009 [cited 2024 Feb 13];83. Available from: http://site.ebrary.com/id/10505611

IOP, intraocular pressure; POM1, post-operative month 1.

Board (IRB) and Ethics Committee of Kibagabaga District Hospital (No. 898/HOP.KIBAG/2023).

Results

Our case series included 11 operative eyes in 9 patients, two of whom underwent bilateral surgery, with chronic angle closure glaucoma (CACG) and primary open angle glaucoma (POAG) as the most common glaucoma diagnoses Table 2 and Table 3). This patient population had severe glaucoma; the only patients who underwent GATT with mild-to-moderate glaucoma were paediatric patients with either congenital or steroid-induced glaucoma (3, 27%). In these younger patients, the higher predicted years lived with disability if left untreated motivated the utilisation of GATT as an earlier surgical option versus trabeculectomy. The mean baseline treated IOP was 25 mmHg, with a standard deviation of 7.7 mmHg. A majority of eyes (7, 64%) had pre-operative best-corrected visual acuity worse than 6/12. We report pre-operative IOP on optimised medical treatment; while on treatment, 8 (73%) eyes still had IOPs greater than 21 (Table 3).

The change in IOP after treatment is shown in Figure 1 and Table 4. The mean IOP at POM3 was 13 mmHg (s.d. 4.7). Success was observed across all surgical types: standalone GATT, GATT and manual small incision cataract surgery (MSICS), and GATT with phacoemulsification cataract surgery (phaco) (Table 4; Figure 2). All patients who underwent GATT with phaco achieved success. At POM3, all patients achieved at least a 20% reduction in IOP, as shown in Figure 3. One case that had undergone a standalone GATT met failure criteria due to a spike in pressure to 25 mmHg on their POM6 visit after consistent pressures lower than 21 mmHg. One patient who had also undergone a standalone GATT was LTFU after POW4, but at this visit, they had met criteria for a qualified success.

Fifty five percent of patients did not require any glaucoma drops after surgery. Four patients required glaucoma drops in the first 90 days post-operatively, one of whom only required drops within the first 3 post-operative days. This also includes a patient who was LTFU, presumably continued IOP-lowering drops more than 90 days after surgery. No patients had any other glaucoma surgeries in the follow-up period. A best corrected visual acuity of greater than 6/12 was seen in 9 eyes (82%) post-operatively, meeting the WHO-recommended threshold for a 'good quality visual outcome'.[12] Visual improvement was likely because of cataract surgery rather than GATT itself; importantly, no patients had a decline in visual acuity after receiving GATT surgery. Complications stratified by surgical type are detailed in Table 5.

TABLE 2: Pre-operative patients' characteristics (N = 11).

Characteristics	Variable	*n*	%
Eyes operated on	-	11	100
Sex	Male	6	55
	Female	5	45
Baseline visual acuity (best corrected)	6/6	0	0
	6/12	2	18
	6/24	3	27
	6/36	2	18
	6/60	1	9
	Fix and follow (infant)	2	18
	Hand motion	1	9

Note: Age: Median = 67; Interquartile range: 34 years – 75 years.

Discussion

This retrospective case series demonstrates that GATT is a useful tool in the arsenal of pressure-reducing treatments for the patients of the Kibagabaga District Hospital and the Rwanda International Institute of Ophthalmology. A majority of patients, many of whom had severe glaucoma, achieved successful pressure reduction and experienced few complications. We also re-demonstrate that lensectomy, where appropriate, concurrent with the GATT procedure, often yields a positive pressure-reducing effect.[12,13]

One case met criteria for failure; however, its unique context merits further discussion. This patient was a teenager post-traumatic cataract extraction with intraocular lens implant with a history of persistent pseudophakic cystoid macular oedema treated medically with injections of anti-vascular endothelial growth factor and eventually sub-Tenon's triamcinolone. He then developed steroid response glaucoma with pressures in the 40s mmHg whenever oral acetazolamide was tapered off. This necessitated surgical intervention. Post-operatively, he had a pressure spike to 25 mmHg at POM6. Although this pressure measurement exceeded our desired cutoff, the therapeutic reduction of 20 mmHg is significant (> 30%) and may be sufficient to prevent further damage to the optic nerve at his age. However, according to our predetermined criteria, this clinically significant outcome still must be listed as a failure. They were restarted on glaucoma medications in the operative eye at their last visit.

Although we cannot predict outcomes for success or failure given our small sample size, some observations can be made. A Fisher's exact test showed no statistically significant difference between the degree of IOP reduction with GATT when stratified by type of glaucoma or by GATT alone versus GATT with lensectomy. Another similar study reports greater rates of successful GATT surgery in POAG patients.[14] All patients with narrowing of the angles at play (CACG and mixed mechanism) achieved medication-sparing pressure reduction success. All patients, except one who received lensectomy (phaco or MSICS) in addition to

TABLE 3: Glaucoma characteristics (N = 11).

Characteristics	Variable	Mean	s.d.	*n*	%
Type of glaucoma	POAG	-	-	3	27
	CACG	-	-	4	36
	Congenital glaucoma	-	-	2	18
	Mixed mechanism	-	-	1	9
	Steroid induced	-	-	1	9
Cup-to-disc ratio	-	0.76	0.32	-	-
Pre-op IOP on medical treatment	-	25	7.7	7	64
	11–21	-	-	2	18
	21–30	-	-	6	55
	31–40	-	-	2	18
Number of glaucoma medications	-	1.4	0.7	-	-
Type of glaucoma medications	Beta-blockers	-	-	9	82
	Carbonic anhydrase inhibitor	-	-	5	46
	Prostaglandin analogues	-	-	1	9
Number of OR surgeries before GATT	0	-	-	11	100

CACG, chronic angle closure glaucoma; GATT, gonioscopy-assisted transluminal trabeculotomy; POAG, primary open angle glaucoma; s.d., standard deviation, IOP, intraocular pressure; Op, operative; OR, operating room.

TABLE 4: Follow-up and surgical outcomes (N = 11).

Characteristics	Variable	Mean	s.d.	Total (*n*)	%
Operation performed	Standalone GATT	-	-	4	36
	GATT and temporal MSICS	-	-	5	46
	GATT and phacoemulsification	-	-	2	18
Follow-up per recommendation	Yes	-	-	8	73
	No	-	-	3	27†
Months followed (mos)	-	6	3.5	-	-
Number lost to follow-up	-	-	-	1	9
Return to OR post-op	Yes	-	-	0	-
Required glaucoma drops post-op	No drops needed	-	-	6	-
	Early (< 90 days)	-	-	4	36
	Late (> 90 days)	-	-	1‡	9
Decline in best corrected visual acuity	-	-	-	0	0
POM3 IOP	-	13	4.7	-	-
Change in IOP (pre-op to post-op), mmHg	-	-13	6.8	-	-
Outcome	Complete success	-	-	8	73
	Qualified success (on medication)	-	-	2	18
	Failure (insufficient pressure reduction)	-	-	1	9

Note: Months followed (mos) range: 1.5–12.

GATT, gonioscopy-assisted transluminal trabeculotomy; IOP, intraocular pressure; MSICS, manual small incision cataract surgery; POM1, post-operative month 1; POM3, post-operative month 3; LTFU, lost to follow-up; POW1, post-operative week 1; OR, operating room; Op; operative.

†, one patient missed POW1 visit, another missed POM1 visit, and one LTFU; ‡, one patient was LTFU and during their last visit POM 1 was on pressure-reducing medication. It is possible patient continued this medication for longer than 90 days.

GATT, met success or qualified success criteria, possibly highlighting the known pressure-reducing effect of lensectomy.[12,13]

Intraocular pressure spikes are a known complication of GATT surgery.[15,16,17] In our case series, this complication was not seen in patients who also underwent lensectomy. The pressure spikes seen in two patients resolved within POW1 after short-term pressure-reducing treatment, and all patients with spikes achieved complete success. Hyphema, another previously documented complication of GATT, was also seen in two patients who achieved qualified success.[15,17] Descemet detachment was seen in a patient who underwent GATT; thus, the endothelial detachment could have been because of the cataract surgery itself.[18] The detachment was small and did not require further surgical intervention.

TABLE 5: Post-operative complications (N = 11).

Variable	Solo GATT (*n* = 4)	GATT and MSCICS (*n* = 5)	GATT and Phaco (*n* = 2)
Hyphema	1	1	0
IOP spike	2	0	0
Corneal oedema	1	0	0
Descemet detachment	0	1	0

GATT, gonioscopy-assisted transluminal trabeculotomy; IOP, intraocular pressure; MSCICS, manual small incision cataract surgery; Phaco, Phacoemulsification.

In a few patients, peripheral anterior synechiae (PAS) were noted in the angle at POM6 and later visits. This has been observed in other studies but has not been demonstrated to affect IOP outcomes.[15,16] Surgical traumas to the trabecular meshwork likely promote fibrin deposition and scar formation, explaining this finding. We saw more PAS in our younger patients and hypothesise that their age may contribute to a more robust fibrotic reaction. Prevention and

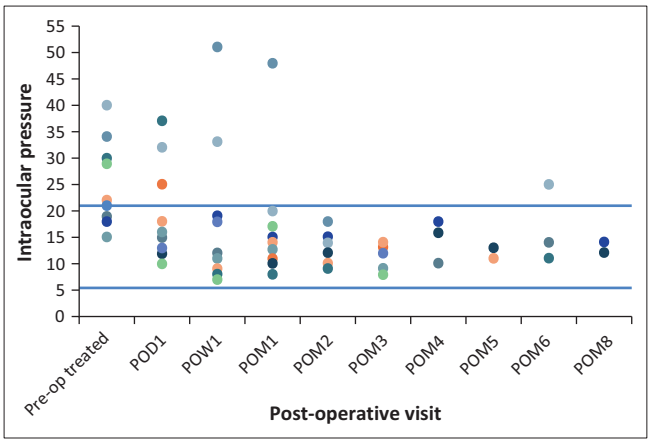

Note: Each coloured point indicated a different patient. Indicator lines at 5 mmHg and 21 mmHg demonstrate the cutoffs described in our success criteria.

Op; operative; POD1, post-operative day 1; POW1, post-operative week 1; POM1, post-operative month 1; POM2, post-operative month 2; POM3, post-operative month 3; POM4, post-operative month 4; POM5, post-operative month 5; POM6, post-operative month 6; POM8, post-operative month 8; IOP, intraocular pressure.

FIGURE 1: Change in intraocular pressure from before surgery through the follow-up period.

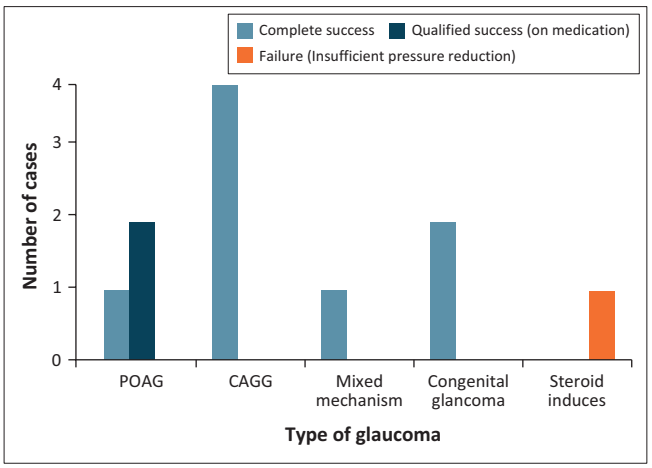

CACG, chronic angle closure glaucoma; POAG, primary open angle glaucoma.

FIGURE 2: Primary outcomes (success, qualified success or failure) stratified by type of glaucoma. Fisher's exact test: *P*-value = 0.067.

control of hyphema and inflammation have been postulated as ways to reduce the risk of PAS formation.[16] Using topical pilocarpine 1% twice daily beginning 1 week postoperatively could also be considered, with its miotic action serving to retract the peripheral iris, thereby preventing angle scarring.

There are limitations to this case series. Our sample size is small, limiting statistical power, the ability to perform multivariate or subgroup analysis and generalisability. Additionally, this is a retrospective study with limited follow up. A prospective, larger, long-term study would be helpful to improve validity and further assess outcomes of this procedure. Our baseline IOP was measured on treatment with no untreated values or washout period, largely because not all patients had recorded untreated pre-operative IOP. This can also be remedied with a prospective study. Given our baseline was treated pre-op IOP, we also highlight that there is likely an even greater degree of pressure-lowering potential after GATT than captured in our data. There was difficulty with patient adherence to preferred follow-up

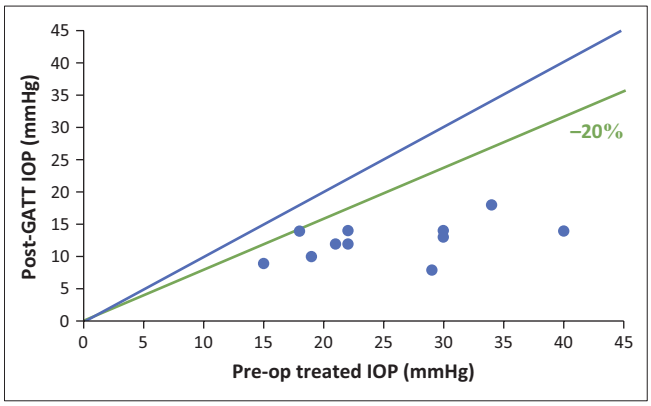

Note: Each point indicated the pre-operative intraocular pressure on the abscissa plotted against the intraocular pressure at 3 months postoperatively on the ordinate. The blue oblique line indicates no change; the green oblique line indicates a 20% reduction in pressure from pre-operatively to post-operatively. Points below and the green line indicate greater than 20% reduction at post-operative month 3.

GATT, gonioscopy-assisted transluminal trabeculotomy; IOP, intraocular pressure.

FIGURE 3: Scattergram comparing pre-operative IOP to post-operative month 3 intraocular pressure.

timelines. Despite this, we were able to get valuable post-operative evaluations for most patients. Qualitative data collected from patients demonstrated that transportation and travel distance were clear barriers to follow-up and scheduled IOP checks. This highlights a known social determinant of health, neighbourhood and built environment, that has been documented to affect access and utilisation of eye care.[19] This also emphasises the great need to not only increase the number of highly skilled ophthalmologists in Rwanda but also their spread to rural areas in order to decrease the travel burden placed on patients who seek care. The various forms of medical records (paper and electronic concurrently) also created some inconsistencies and gaps in records. It is possible that some visits were not captured in these records and have not been included in our data set. Additionally, visual field data were not consistently available for all patients and, therefore, could not be included in the analysis. In the future, the clinic is working to streamline its medical record system to avoid these kinds of challenges. A single surgeon performed the surgeries, providing an internal control. Intraocular pressure was measured by other physicians to avoid bias.

Conclusion

This case series demonstrates that GATT is an accessible MIGS option for patients with various forms of glaucoma in lower-resource settings.[20] Our patient cohort saw a mean IOP decrease of 13 mmHg at POM3 compared to their pre-op treated IOP. As efforts continue to increase equitable access to MIGS options around the world, we highlight GATT as a validated procedural option and encourage training in this procedure.

Acknowledgements

We would like to acknowledge the Rwanda International Institute of Ophthalmology for supporting these academic projects. We would also like to acknowledge the American Academy of Ophthalmology and the Association of University Professors of Ophthalmology for providing

grant funding to support this research partnership. Some of this material has previously been presented at the American Academy of Ophthalmology annual meeting 2024 and Global Ophthalmology Summit 2024.

This article is based on a conference poster originally presented at the American Academy of Ophthalmology (AAO) annual meeting, held in Chicago, Illinois, on 18 October – 21 October 2024. The conference poster, titled 'Implementation of Gonioscopy Assisted Transluminal Trabeculotomy (GATT) in Kibagabaga District Hospital, Kigali, Rwanda' was subsequently expanded and revised for this journal publication.

During the preparation of this work, the authors used Claude AI, 3.5 for grammatical review. The content was reviewed and edited by the authors, who take full responsibility for its accuracy.

Competing interests

The authors disclosed receipt of the financial support for the research included in this article. This work was supported by the Minority Ophthalmology Mentoring Program, through a partnership between the American Academy of Ophthalmology and the Association of University Professors of Ophthalmology. The authors has fully disclosed this funding and implemented an approved plan for managing any potential conflicts arising from their involvement. The terms of these funding arrangements have been reviewed and approved by the affiliated university in accordance with its policy on objectivity in research.

CRediT authorship contribution

Agnes C. Owete: Conceptualisation, Data curation, Formal analysis, Funding acquisition, Investigation, Methodology, Project administration, Resources, Software, Validation, Visualisation, Writing – original draft, Writing – review & editing. Eric Manirakiza: Conceptualisation, Data curation, Formal analysis, Investigation, Methodology, Project administration, Writing – review & editing. Leon W. Herndon: Conceptualisation, Methodology, Resources, Supervision, Validation, Visualisation, Writing – review & editing. John M. Cropsey: Conceptualisation, Data curation, Formal analysis, Funding acquisition, Investigation, Methodology, Project administration, Software, Supervision, Validation, Visualisation, Writing – review & editing. All authors reviewed the article, contributed to the discussion of results, approved the final version for submission and publication, and take responsibility for the integrity of its findings.

Funding information

This work was supported by the Minority Ophthalmology Mentoring Program 2023 Research Grant supported by the American Academy of Ophthalmology and the Association of University Professors of Ophthalmology.

Data availability

The data that support the findings of this study are not openly available and are available from the corresponding author, Agnes C. Owete, upon reasonable request.

Disclaimer

The views and opinions expressed in this article are those of the authors and are the product of professional research. They do not necessarily reflect the official policy or position of any affiliated institution, funder, agency or the publisher. The authors are responsible for the article's results, findings and content.

References

1. Grover DS, Godfrey DG, Smith O, Feuer WJ, Montes de Oca I, Fellman RL. Gonioscopy-assisted transluminal trabeculotomy, ab interno trabeculotomy: Technique report and preliminary results. Ophthalmology. 2014;121(4):855–861. https://doi.org/10.1016/j.ophtha.2013.11.001
2. Grover DS, Smith O, Fellman RL, et al. Gonioscopy-assisted transluminal trabeculotomy: An Ab interno circumferential trabeculotomy: 24 months follow-up. J Glaucoma. 2018;27(5):393–401. https://doi.org/10.1097/ijg.0000000000000956
3. Hamze H, Mohite AA, Pandey P, Sung VCT, Masood I. Comparison of 1-year surgical outcomes of combined cataract surgery and gonioscopy-assisted transluminal trabeculotomy (GATT) versus cataract surgery and iStent Inject. Graefes Arch Clin Exp Ophthalmol. 2021;259(10):3035–3044. https://doi.org/10.1007/s00417-021-05133-z
4. Aboalazayem F, Elhusseiny AM, El Sayed YM. Gonioscopy-assisted transluminal trabeculotomy: A review. Curr Eye Res. 2023;48(4):329–338. https://doi.org/10.1080/02713683.2022.2084113
5. Maheshwari D, Gupta S, Tara TD, Pillai MR, Drishti C, Ramakrishanan R. Gonioscopy-assisted transluminal trabeculotomy: Passing the right way decoding suture. Indian J Ophthalmol. 2022;70(10):3746. https://doi.org/10.4103/ijo.ijo_1104_22
6. Chen PP. Risk and risk factors for blindness from glaucoma. Curr Opin Ophthalmol. 2004;15(2):107–111. https://doi.org/10.1097/00055735-200404000-00009
7. Elhusseiny AM, Yannuzzi NA, Khodeiry MM, Lee RK, Smiddy WE. Is MIGS cost effective? Invest Ophthalmol Vis Sci. 2021;62(8):2644.
8. Eslami Y, Amini H, Zarei R, et al. Socioeconomic factors and disease severity at glaucoma presentation. Iran J Ophthalmol. 2011;23:19–26.
9. Shaarawy T, Grehn F, Sherwood M. WGA guidelines on design and reporting of glaucoma surgical trials [Internet]. The Hague: Kugler Publications; 2009 [cited 2024 Feb 13];83. Available from: http://site.ebrary.com/id/10505611
10. Harris PA, Taylor R, Thielke R, Payne J, Gonzalez N, Conde JG. Research electronic data capture (REDCap) – A metadata-driven methodology and workflow process for providing translational research informatics support. J Biomed Inform. 2009;42(2):377–381. https://doi.org/10.1016/j.jbi.2008.08.010
11. Harris PA, Taylor R, Minor BL, et al. The REDCap consortium: Building an international community of software platform partners. J Biomed Inform. 2019;95:103208. https://doi.org/10.1016/j.jbi.2019.103208
12. Berdahl JP. Cataract surgery to lower intraocular pressure. Middle East Afr J Ophthalmol. 2009;16(3):119–122. https://doi.org/10.4103/0974-9233.56222
13. Brízido M, Rodrigues PF, Almeida AC, Abegão Pinto L. Cataract surgery and IOP: A systematic review of randomised controlled trials. Graefes Arch Clin Exp Ophthalmol. 2023;261(5):1257–1266. https://doi.org/10.1007/s00417-022-05911-3
14. Aktas Z, Ucgul AY, Bektas C, Sahin Karamert S. Surgical outcomes of prolene gonioscopy-assisted transluminal trabeculotomy in patients with moderate to advanced open-angle glaucoma. J Glaucoma. 2019;28(10):884–888. https://doi.org/10.1097/ijg.0000000000001331
15. Sato T, Hirata A, Mizoguchi T. Prospective, noncomparative, nonrandomized case study of short-term outcomes of 360° suture trabeculotomy ab interno in patients with open-angle glaucoma. Clin Ophthalmol. 2015;9:63–68. https://doi.org/10.2147/opth.s75739
16. Gunay M, Turk A, Ozturk H, Bulanik FT, Uzlu D. Evaluation of peripheral anterior synechia formation following gonioscopy-assisted transluminal trabeculotomy surgery. Int Ophthalmol. 2023;43(9):3045–3053. https://doi.org/10.1007/s10792-023-02704-3
17. Knight G, Du BM, Kruse C, Pons J. Surgical outcomes of 5/0 polypropylene gonioscopy-assisted transluminal trabeculotomy (GATT) for primary management of open-angle glaucoma in Eswatini. S Afr Ophthalmol J. 2023;18(4):14–19.
18. Thakur SK, Dan A, Singh M, Banerjee A, Ghosh A, Bhaduri G. Endothelial cell loss after small incision cataract surgery. Nepal J Ophthalmol. 2011;3(2):177–180. https://doi.org/10.3126/nepjoph.v3i2.5273
19. Andoh JE, Ezekwesili AC, Nwanyanwu K, Elam A. Disparities in eye care access and utilization: A narrative review. Annu Rev Vis Sci. 2023;9:15–37. https://doi.org/10.1146/annurev-vision-112122-020934
20. Adunola O, Godswill N. Minimally invasive glaucoma surgery: Viability in Africa [homepage on the Internet]. European Society of Medicine; 2025 [cited 2026 Mar 10]. Available from: https://esmed.org/minimally-invasive-glaucoma-surgery-viability-in-africa/