
CASE REPORT AND REVIEW OF THE LITERATURE

Postoperative ophthalmic complication – what's the diagnosis?

RN Dunn MBChB(UCT), MMed(Orth)UCT, FCS(SA)Orth
Consultant Spine and Orthopaedic Surgeon
Associate Professor, University of Cape Town
Head: Orthopaedic Spinal Services Groote Schuur Hospital
Spine Deformity Service Red Cross Children's Hospital
Private Practice: Constantiaberg Medi-Clinic Hospital

Reprint requests:

Prof RN Dunn
Groote Schuur Hospital
Tel: 021 404-5387
Fax: 021 404-5389
email: info@spinesurgery.co.za

Case report

A 45-year-old female patient (*Figures 1 and 2*) was admitted following a motor vehicle accident as an unrestrained passenger. She was fully orientated. Her only injury was that of a C7/T1 distraction flexion injury (*Figure 3*). She was C5 motor and sensory complete with a zone of partial preservation from C6–T1. She was admitted to the Acute Spine Injury Unit high care and managed with routine supportive care.

Two days later she underwent surgical stabilisation. Once anaesthetised, the Mayfield clamp was applied. She was positioned prone and a midline posterior approach utilised to expose the cervico-thoracic junction.

A large collection of clear fluid dorsal to lamina at the injury level with obvious disruption of the ligamentum flavum was noted. This was suctioned off to facilitate visualisation. The dural sac appeared haemorrhagic but C7 and T1 pedicle screws were placed and the fusion performed. No effort was made to identify the dural tear or repair it. There was no ongoing drainage. A 3 mm closed drain was placed and the wound closed. The patient returned to the high care environment postoperatively.

The next morning the bilateral loss of lateral gaze was noted. Bilateral sixth cranial nerve palsy was diagnosed.

There had been minimal drainage overnight (30 ml) but the low CSF pressure was a concern as a cause and the drain was immediately removed. By three-month follow-up the palsies were still present and the patient was being managed by the ophthalmologists by means of alternate eye patches.

Discussion

Abducens (sixth) nerve palsy is the most common encountered extra-ocular muscle palsy with an incidence is 11.3 per 100 000 people.¹ In the spine literature, this palsy is a well-recognised complication of halo traction. However there are many causes due to the anatomical properties of the nerve.

Berlit *et al*² evaluated 165 patients suffering from abducens nerve palsy as the main presenting symptom. They found a vascular origin (29.7%) to be the commonest, followed by inflammatory diseases (19.4%) and tumours (10.9%), while traumatic abducens paresis (3.1%) was rare.

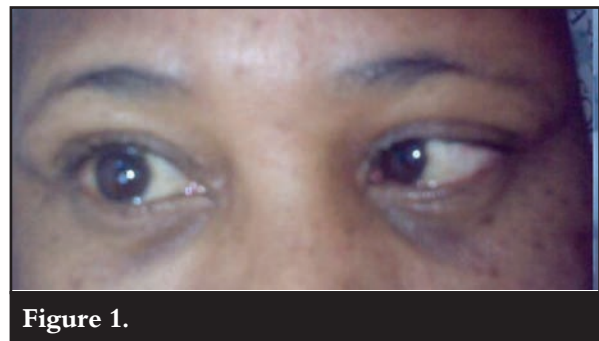


Figure 1.

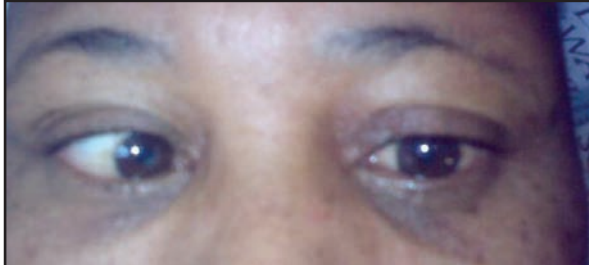

Figure 2.

An earlier paper by Moster confirms the above aetiology and states that the vascular pathologies are due to diabetes mellitus, hypertension and atherosclerosis. He found the vascular group to be older. In the younger group, multiple sclerosis and tumours were more common as a cause.³

In the surgical environment, abducens palsy is a recognised complication of lumbar puncture or spinal anaesthesia with multiple case reports.^{3,4,5} This is due to an acutely lowered CSF pressure and downward sagging of the brain stem with traction on the cranial nerve. This is usually associated with a post-lumbar puncture headache. This was thought to be the cause of our patient's condition.

The abducens nucleus is located in the pontine tegmentum, just ventral to the fourth ventricle, and axons of the seventh cranial nerve loop around the abducens nucleus. Fascicles emerging from the nucleus course forward through the pontine tegmentum to emerge from the ventral surface of the brain stem.

The nerve consists of intra-cisternal, intra-cavernous and intra-orbital parts. After exiting the ponto-medullary sulcus, it courses through the pre-pontine cistern and inside Dorello's canal which is a short osteofibrous channel between the petrous apex and Gruber's ligament. It then joins the cavernous sinus in the petroclival region and innervates the lateral rectus muscle of the eye.

The abducens is vulnerable at three angulation points during its course in the petroclival region, viz. at the dural entry point, the petrous apex and at the point where it joins the lateral wall of the internal carotid artery. The mechanism of traumatic abducens nerve palsy may be direct mechanical injury or an indirect injury. The former results from nerve compression by a haematoma or a surrounding structure such as ligament or dura matter. The latter results from nerve ischaemic change due to vessel compression or vasospasm.^{6,7}

Traditionally, the abducens nerve's susceptibility to injury has been attributed to its long intra-cranial course. This has been challenged as in fact the trochlear nerve has a longer course. Subsequently the abducens' vulnerability was postulated to be due to its oblique or transverse course rather than length. Others suggested strangulation by the basilar artery.

To this end, Hansen and colleagues performed an anatomical study of the sixth nerve and compared it to the fourth.

Paediatric autopsies were performed in 26 consecutive cases. They established that the fourth and sixth CN grew at similar rates and that the fourth remained three times longer.⁸

The intracranial portion of the abducens is vulnerable to injury from distortion of the brain by mass lesions or transtentorial herniation. The portion of the nerve within Dorello's canal and the cavernous sinus is extradural. The fibrous and osseous tissue within Dorello's canal fixes the rostral end of the abducens nerve. It is also tethered caudally at its point of emergence from the medullopontine junction. During transtentorial herniation, the parahippocampal gyri are forced past the free edge of the tentorium. Simultaneously, the brainstem (including the medullopontine junction) moves caudally towards the foramen magnum. Consequently, the abducens cranial nerve is stretched and may become necrotic where it turns into Dorello's canal.⁶⁻⁸

In our case the loss of CSF resulted in the caudal migration of the brainstem, traction on the abducens and the resultant palsy. Care should be taken in such a case of a large CSF leak, possibly stemming the intra-operative loss with patties and dura repair if possible.

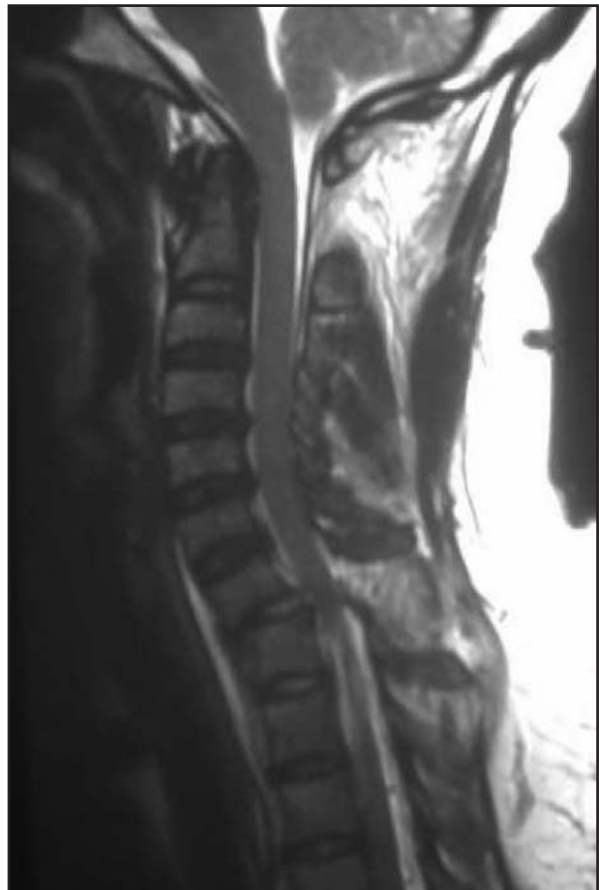

Figure 3.
Pre-operative MRI of the C7/T1 trauma

References

1. Patel SV, Mutyala S, Leske DA, Hodge DO, Holmes JM: Incidence, associations, and evaluation of sixth nerve palsy using population-based method. *Ophthalmology* 2004; **111**:369-75.
2. Berlit P, Reinhardt-Eckstein J, Krause KH. [Isolated abducens paralysis: a retrospective study of 165 patients.] *Fortschr Neurol Psychiatr* 1989;**57**:32-40.
3. Moster M, Savino PJ, Sergott RC *et al.* Isolated sixth-nerve palsies in younger adults. *Arch Ophthalmol* 1984;**102**:1328-30.
4. Niedermuller U, Trinkla E, Bauer G. Case report: Abducens palsy after lumbar puncture. *Clinical Neurology and Neurosurgery* 2002;**104**:61-63.
5. Johnson R, Lyons G, Bamford J. Visual problems following dural puncture. *Postgrad Med J* 1998;**74**:47-58.
6. Kim M, Cho M, Kim S. Delayed bilateral abducens nerve palsy after head trauma. *J Korean Neurosurg Soc* 2008;**44**:396-98.
7. Abducens Paralizi Hastaların Gözden Geçirilmesi. Review of a series with abducens nerve palsy. *Turkish Neurosurgery* 2008;**18**(4):366-73.
8. Hanson RA, Ghosh S, Gonzalez-Gomez I, *et al.* Abducens length and vulnerability? *Neurology* 2004 January (1 of 2);**62**:33-36.