
CLINICAL ARTICLE

The medical management of spinal tuberculosis

R Dunn MBChB(UCT), MMed(UCT), FCS(SA)Orth
Consultant Orthopaedic and Spine Surgeon, Associate Professor University of Cape Town, Head
Orthopaedic Spine Services: Groote Schuur Hospital

Reprint requests:

Prof Robert Dunn

Tel: (021) 404-5387

Fax: (021) 404-5389

Email: info@spinesurgery.co.za

Abstract

The overall prevalence of spinal tuberculosis (TB) in South Africa is currently 948 per 100 000. All trends are upward, including incidence of sputa positive cases, relapses and retreatment rates, as well as new extra-pulmonary cases. This is driven by the co-existent HIV endemic and the effect of HIV on TB re-activation.¹ Autopsy studies confirm that 30-40% of HIV-positive patients die of TB and 44% of TB patients have HIV.² Musculoskeletal manifestations of TB are more frequent in the HIV host, reported as high as 60% compared to the normal 3-5% incidence.³

TB is largely a public health issue and will only be controlled when the problems of abject poverty such as malnutrition, overcrowding and early access to medical care is improved. To this end it is notifiable by law in an effort to allow preventative measures to be effected.

TB spine represents about 1% of overall cases but places a large demand on resources due to the costs of paraplegia and tertiary level care. Although surgery is indicated in selected cases, medical care remains the key component. Medical care involves both the diagnostic process and the medical intervention by means of supportive care and anti-tuberculous chemotherapy.

Diagnosis of TB spine

The presenting complaints are usually axial back pain and may be associated with neurological deficit. The presentation is typically delayed due to the insidious nature of the disease as well as the poor access to care in the community it frequently affects.

Tuberculin skin tests

Intra-dermal skin testing to elicit an inflammatory response has been widely used. These include the Mantoux, Heaf and Tine tests. They are relatively inexpensive and technically easy to administer. Unfortunately they need to be read at a definite point following inoculation. This may lead to inaccuracies if the patient does not return at the prescribed time. There are false positive results due to patients being sensitised by BCG vaccination or exposure to environmental mycobacterium.

False negatives occur due to immunosuppression from HIV, cytotoxics or even overwhelming TB infection.

Sputum

Sputum is frequently used to diagnose pulmonary TB by the presence of acid-fast bacilli (AFB). The yield is dependent on the number of serial tests, whether direct staining or concentrated methods are employed as well as the method of collection (*Table I*).⁴ Expecterated sputum is positive in 55%, induced sputa 38% and lavage 26%.⁵

Bloods

The white cell count is typically normal and the ESR markedly raised. It averages in the 80's but may often exceed 100 mm/hour.³ There may be anaemia of chronic disorder or related to the malnutrition. Likewise the albumin is reduced.

Table I: Accumulative positive rates from sputa for acid-fast bacilli if the culture is eventually positive

No. of daily samples	1	2	3
Direct	57%	76%	81%
Concentrated	74%	83%	91%

Newer tests

Selective immunological tests are being developed.⁶ TB antigens induce early secretive antigen 6. This can be tested on blood in the laboratory. It is not influenced by BCG or other mycobacteria.

Nucleic acid amplification by polymerase chain reaction (PCR) is possible in a few hours but requires strong laboratory capacity and is relatively expensive. It is not possible to distinguish between live and dead mycobacteria. There is a high specificity but variable sensitivity and it should therefore be used in conjunction with other data.

The PCR technique can be used to identify drug resistance rather than wait for the definitive culture and sensitivities.

Culture

Traditionally mycobacterium is cultured using the Lowenstein-Jensen slope or broth media. This takes 2-4 weeks if microscopy is positive and up to 8 weeks if microscopy is negative. Newer techniques (BACTEC) may reduce culture times by earlier recognition of bacterial growth.

Histology

The presence of caseous granuloma with AFBs is diagnostic. Granuloma on its own is suggestive and the diagnosis is dependent on the clinical context.

Patients are frequently initiated on anti-TB medication prior to diagnostic confirmation by primary care physicians. Thus the presence of AFBs on staining and positive culture results are reduced. In these cases the histological results are often the only confirmation. It is important to utilise all diagnostic modalities available to confirm the diagnosis. *Figure 1* depicts the incidence of positive results in the author's series (unpublished data). Overall a high level of diagnostic confirmation is achieved.

Imaging

The typical features of apical radiographic changes on the chest X-ray have a positive predictive value of 61% with 67% specificity.⁷

The features of spine TB are that of paraspinal shadow in the thoracic spine indicating the presence of an abscess. In the lumbar area the pus dissipates in the psoas muscle and thus the discrete paraspinal collection is not seen.

There is vertebral body destruction with a focal kyphosis (*Figures 2 and 3*). Typically at least two bodies are involved, with juxta-discal endplate destruction and collapse. There may be preservation of the disc space in the early phase.

CT and MRI are useful to further delineate bony destruction and soft tissue elements especially in the case of neurological abnormality (*Figure 4*). Non-contiguous infection is as high as 16% and a full length MRI scout is recommended.⁸ If not possible, full spine X-rays should be employed.

Nuclear scintigraphy (bone scan) may be useful to detect other non-contiguous lesions, both in the spine and limbs.

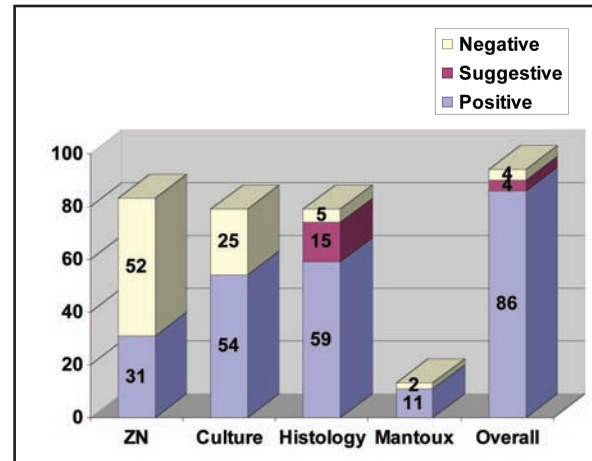
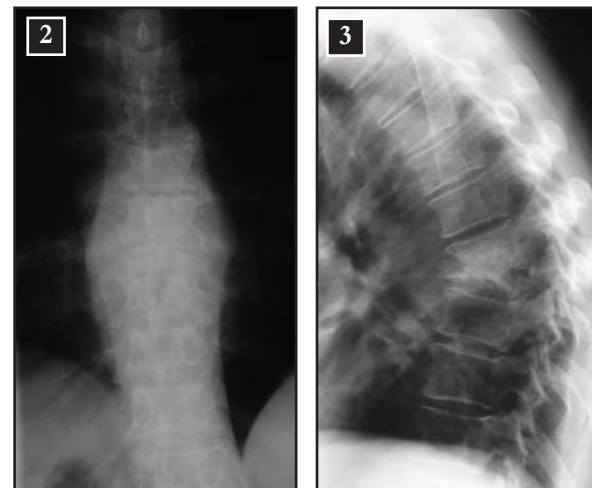


Figure 1: Chart depicting the incidence of positive results for each diagnostic modality employed in the author's cohort (unpublished data)



Figures 2 and 3: AP and lateral thoracic spine demonstrating paraspinal abscess and focal kyphosis due to vertebral body destruction

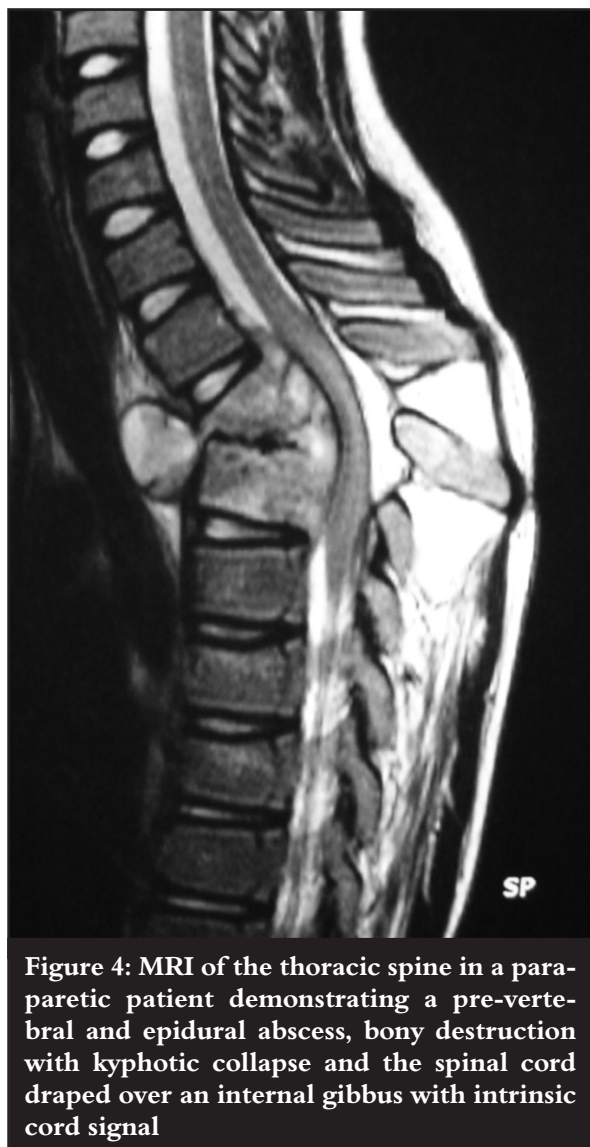

Figure 4: MRI of the thoracic spine in a paraparetic patient demonstrating a pre-vertebral and epidural abscess, bony destruction with kyphotic collapse and the spinal cord draped over an internal gibbus with intrinsic cord signal

This technology has largely been superseded by MRI, but with access problems in some hospitals, bone scan may still have a role. Unfortunately it does not delineate the soft tissue extent of the disease.

TB is the current great mimicker. Spine pathology in a known pulmonary TB patient should not be assumed to be due to TB. In high incidence areas such as ours, they are frequently unrelated and should be investigated independently. Other infections, eosinophilic granuloma and metastatic disease can be confused with spinal TB with dire consequences if not recognised and appropriately managed.⁹

To this end biopsy is mandatory. CT-guided fine biopsy has a poor yield as insufficient tissue is provided for histology and TB spine is a pauci-bacterial disease. Multiple cores with a Jamsheedie or Harlow-Wood needle are recommended. This requires a general anaesthetic in theatre.

The lumbar spine can be biopsied via the posterolateral insertion of the needle, 7 cm from the midline, directed at 45° to reach the vertebral body. Cores are taken under lateral image guidance. The author prefers the lateral decubitus position, left side up, to reduce anaesthetic requirements. Thoracic and thoracolumbar levels are best approached via the percutaneous transpedicular route. Should there be an associated large abscess, a costotransversectomy is recommended and the pus/tissue removed for biopsy. Likewise a large psoas abscess can be drained/biopsied via a small intermuscular retroperitoneal approach. The author performs open cervical biopsies.

Medical intervention

The TB spine patient is frequently malnourished and may present with complications of paraparesis such as decubitus ulcers and contractures. The albumin level should be checked and appropriate nutritional support implemented. Pressure care and physiotherapy are important to treat and prevent these complications.

Anti-tuberculous medication

Isoniazid (INH) is the most effective bactericidal drug but rifampicin (RIF) is also important in this regard. RIF and pyrazinamide (PZA) are the most important sterilising drugs. They are utilised to kill the 'persisters' which are mycobacterium that are sealed off by the inflammatory process and remain latent for later reactivation. INH and RIF are most effective at preventing resistance to other drugs and this is why multiple drug therapy is important. The drug regimen is administered on a daily basis. In SA, the 'directly observed treatment short-course' (DOTS) system is employed to improve compliance. Completion rates for pulmonary TB have been shown to be 61% when not supervised, 86% with DOTS and 91% with an incentivised DOTS system.¹⁰ In SA there is a financial incentive as TB patients receive a financial grant while on the TB medication.

The duration of drug therapy in spine TB is controversial. The typical management of pulmonary TB is 2 months' intensive phase with four drugs followed by a continuation phase of two drugs for 4 months. In spine TB however there is dead bone and tissue with probably poorer antibiotic penetration and thus the argument for longer duration at higher doses. Shorter duration is tempting as one would expect better compliance, a lower incidence of side effects and a lower burden on the health system. The risk, of course, is higher recurrence rates.

The literature is replete in terms of exact duration of treatment in musculoskeletal TB. The British Thoracic Society recommends 6 months' duration for spine unless there is central nervous system involvement. Should this be the case, they recommend RIF and INH for 12 months.^{11,12} The Canadian Thoracic Society¹³ recommends that bone and joint TB should be treated for longer but are not prescriptive.

The MRC study in Hong Kong reviewed TB spine management with drugs and aggressive surgery. At 5 years' follow-up, both the 6-month and 9-month groups using INH/RIF/streptomycin, had favourable results. At 14 years, the 6-, 9-, and 18-month groups had similar clinical results.^{14,15}

The Madras study used medication alone with no surgery. They reported on 6- versus 9-month duration with a respective 91% and 98% favourable status. At 10 years' follow-up, there was no difference.¹⁶

Ge *et al* reported on the drug penetration of the spine with good results with only 4.5 months' treatment. The study was not focused on duration but only mentioned in the methodology, and long-term recurrence rates are not available.¹⁷

NICE recommends daily dosing with combination agents but does not mention duration.¹²

The Groote Schuur experience is that of four-drug therapy daily throughout the course, i.e. no reduction after the first two months as in pulmonary TB

Wang compared three protocols of different drug combinations and duration combined with surgical debridement. The ultra-short group was 4.5 months (2 months INH/RIF/PZA followed by 2.5 months INH and bi-weekly RIF/PZA), the short course 8 months (3 on strep/INH/RIF/PZA followed by 5 months INH and bi-weekly INH/RIF/PZA) and a 12 month (3 Strep/INH/RIF/PZA followed by 9 months INH and bi-weekly RIF/PZA). They found similar clinical effect with higher frequency of drug side effects the longer the duration of treatment. They did not report disease recurrence and it is unclear how many patients reached the planned 5-year follow-up period.¹⁸

The Groote Schuur experience is that of four-drug therapy daily throughout the course, i.e. no reduction after the first two months as in pulmonary TB. INH/RIF/ethionamide/PZA are used in a combination tablet (Rifafour). The dose is weight-related. This is usually combined with surgery. Duration is for a minimum of 9 months. If the patient was on medication pre-operatively, the 9 months is calculated from the date of surgery irrespective of the pre-operative medication period. At 9 months clinical, radiological and ESR is assessed and frequently the duration is extended to 12 months if there are any concerns. Clinically there should be resolution of axial pain, the ESR should be normal and the X-rays confirm bony healing. Once the drugs are stopped the patient is reviewed 3 months later to confirm the ESR remains normal. The ESR is less useful in the HIV patient and may well be overridden by the other criteria.

During medical treatment the patient should be monitored for side effects from the anti-TB drugs. Visual acuity should be monitored and ethionamide can result in irreversible deterioration. This is why it should not be used in children where visual testing is not easily performed.

Streptomycin and ethambutol may affect renal function.

Many of the agents are hepatotoxic. Although not routinely tested, any concerns such as nausea should raise the possibility of hepatitis. Should the transaminases (AST/ALT) be raised but less than 2x normal, re-testing in 2 weeks is indicated. If greater than 2x normal, retest weekly for 2 weeks, then every second week until normal. If $\geq 5x$ normal or increased bilirubin, the INH, RIF and PZA should be stopped. If clinically unwell, one can continue with streptomycin or ethambutol. Once the transaminases normalise, the drugs can then be serially re-introduced with an initial low dose escalating every few days.

Multi-drug resistance (MDR) is 1.8%¹ overall but 5% in the author's personal series. This usually manifests by failure of medical therapy and confirmed later by sensitivities. The availability of PCR sensitivities will reduce the wait time. Once MDR is recognised, the treatment regimen should be changed to amikacin or kanamycin (6 months), ofloxacin, ethionamide, ethambutol (or terizidone but expensive), PZA. INH and RIF can be considered in addition as not all mycobacterium may be resistant. This is best discussed with the local infectious diseases team. The use of the MDR protocol is logistically difficult as the aminoglycosides need to be administered parenterally. This may require inpatient care should the home circumstances not be conducive to good compliance. A subcutaneous port should be considered, especially in children, to avoid the daily painful intra-muscular injections.

Effect of HIV on TB

Not only does HIV potentiate TB spine by negatively affecting the immune system, but it also modifies the course of the disease creating therapeutic challenges.

In TB endemic areas such as sub-Saharan Africa, most people have been exposed to TB. During this exposure a cellular immunity is established. In 85% the disease is terminated by the host's immune system, in 10-15% it is incompletely sterilised with residual bacteria lying dormant, and in a few patients progressive active disease ensues.

As HIV negatively impacts the cellular immunity, it reduces the host's reaction to TB. This manifests in poor control of the initial infection or poor ability to control the residual TB foci with reactivation of disease.

Effect of TB on HIV

TB reactivation is not only a result of the HIV-reduced immune system but a driver of accelerated HIV disease. TB increases activation of the immune system with increased secretion of pro-inflammatory mediators such as interleukin and TNF- α . These in turn increase HIV replication with CD4 cell loss and a negative effect on the mono- and lymphocytes with accelerated HIV-related disease process.^{2,3}

Immune restoration inflammatory syndrome (IRIS)

This immunocological relationship causes management challenges which can be life-threatening in their own right. There is a risk of the host with a severely depressed immune state developing IRIS with the initiation of anti-retroviral treatment (ARVs). ARVs may dramatically improve the cellular immune response and lead to an overwhelming reaction to the TB antigens with a dangerous decline in patient health. This period often requires steroids to dampen the acute associated inflammatory response. Should the patient be both HIV-positive with a low CD4 count and infected with TB, advice should be sought from the local infectious diseases specialists as these patients can rapidly become increasingly ill with medical intervention. In this context, initiation of ARVs must be delayed until the anti-TB medication is effective.

Surgical indications

While many patients are managed non-operatively and all require the abovementioned management, the clinician should be vigilant to those who require additional surgical decompression and stabilisation. Instability with both anterior and posterior column involvement requires urgent intervention. The neurological indications are less clear as medical treatment alone can reverse paraparesis. Deteriorating neurological status requires surgical consideration and neurological recovery may well be accelerated with decompression, in the author's opinion.

Conclusion

As TB continues to increase, so will TB spine. Many of these cases do not require reconstruction surgery and medical care remains the mainstay of management. Diagnostic confirmation, rather than presumption, is mandatory and requires a biopsy to differentiate it from the many other conditions that TB mimics.

Due to the increasing incidence many patients may need to be cared for outside the tertiary centres by generalists, necessitating a general awareness of appropriate medical care.

No commercial benefits were or will be derived from this paper.

References

- World Health Organisation. WHO REPORT 2009 Global Tuberculosis Control. Website <http://www.who.int>.
- Martin DJ. Epidemiology, pathology and clinical presentation of HIV/TB. *Medical Chronicle* 2009; Feb: 79.
- Govender S, Parbhoo AH, Kumar KPS, Annamalai K. Anterior spinal decompression in HIV-positive patients with tuberculosis A prospective study. *J Bone Joint Surg [Br]* 2001;**83-B**:864-7.
- Peterson EM, Nakasone A, Platon-DeLeon JM, Jang Y. Comparison of direct and concentrated acid-fast smears to identify specimens culture positive for *Mycobacterium* spp. *Journal of Clinical Microbiology* 1999;**37**(11):3564-8.
- Yajko DM, Nassos PS, Sanders CA, Madej JJ, Hadley WK. High predictive value of the acid-fast smear for *Mycobacterium tuberculosis* despite the high prevalence of *Mycobacterium avium* complex in respiratory specimens. *Clinical Infectious Diseases* 1994;**19**(2):334-6.
- Nahid P, Pai M, Hopewell P. Advances in the diagnosis and treatment of tuberculosis. *Proc Am Thorac Soc* Vol 3. pp 103-110, 2006 DOI: 10.1513/pats.200511-119JH.
- Wilcke JT, Kok-Jensen A. Diagnostic strategy for pulmonary tuberculosis in a low-incidence country: results of chest X-ray and sputum culture for *Mycobacterium tuberculosis*. *Respiratory Medicine* 1997;**91**(5):281-5.
- Polley P, Dunn RN. Non-contiguous spinal tuberculosis – incidence and management. *European Spinal Journal* 2009;**18**:1096-101 DOI 10.1007/s00586-009-0966-0.
- Zondag I, Dunn RN. Spinal tuberculosis: Diagnostic biopsy in mandatory. *SAMJ* May 2008;**98**(5):360-2.
- Chaulk CP, Kazandjian VA. Directly observed therapy for treatment completion of pulmonary tuberculosis: Consensus Statement of the Public Health Tuberculosis Guidelines Panel. *JAMA* 1998;**279**:943-8.
- Joint Tuberculosis Committee of the British Thoracic Society. Chemotherapy and management of tuberculosis in the United Kingdom: recommendations 1998. *Thorax* 1998;**53**:536-48.
- National Collaborating Centre for Chronic Conditions. *Tuberculosis: clinical diagnosis and management of tuberculosis, and measures for its prevention and control*. London: Royal College of Physicians, 2006. ISBN 1 86016 277 0.
- Canadian tuberculosis standards 6th edition. Published online by authority of the Minister of Health 2007. HP40-18/2007E-PDF. ISBN 978-0-662-45955-2.
- Darbyshire J. A 15-year assessment of controlled trials of the management of tuberculosis of the spine in Korea and Hong Kong *J Bone Joint Surg [Br]* 1998;**80-B**:456-62.
- Upadhyay SS, Saji MJ, Yau AC. Duration of antituberculosis chemotherapy in conjunction with radical surgery in the management of spinal tuberculosis. *Spine* 1996;**21**(16):1898-903.
- Medical Research Council Working Party on tuberculosis of the spine five-year assessment of controlled trials of short-course chemotherapy regimens of 6, 9 or 18 months' duration for spinal tuberculosis in patients ambulatory from the start or undergoing radical surgery. *International Orthopaedics* 1999;**23**(2):73-81.
- Ge Z, Wang Z, Wei M. Measurement of the concentration of three antituberculosis drugs in the focus of spinal tuberculosis. *Eur Spine J* (2008) **17**:1482-7.
- Wang Z, Ge, Z, Jin, W, et al. Treatment of spinal tuberculosis with ultrashort-course chemotherapy in conjunction with partial excision of pathologic vertebrae. *The Spine Journal*. 2007;**7**:671-81.