

Multiple tendon ruptures in ochronosis: case report and review of prophylactic therapy

MV Ngcelwane MBChB(Natal), FCS(SA)Orth, MSc(Orth)(London)
Department of Orthopaedics, Steve Biko Academic Hospital, University of Pretoria
M Mandaba MBChB(Cape Town), FC(Orth)(SA)
Department of Orthopaedics, Livingstone and Mercantile Hospitals, Port Elizabeth
TQ Bam MBChB(Medunsa), FC(Orth)(SA)
Department of Orthopaedics, Livingstone Hospital, Port Elizabeth

Reprint requests:

Prof MV Ngcelwane
Department of Orthopaedics
Steve Biko Academic Hospital
University of Pretoria
P/Bag X169
Pretoria
0001
Tel: 012 354-2851
Fax: 012 354-2821
Email: mthunzi.ngcelwane@up.ac.za

Abstract

Ochronosis is dark pigmentation of connective tissue in patients with alkaptonuria. The dark pigmentation is caused by accumulation of homogentisic acid (HGA) and its metabolites in the connective tissues, due to deficiency of an enzyme that degrades HGA in the tyrosine degradation pathway. The deposition of HGA in connective tissue causes weakness of the tendon and subsequent rupture, especially the large tendons in the body.

Rupture of isolated tendons has been reported in many case reports in the literature. We report on a patient with multiple sequential tendon ruptures, and review the literature to see if there is a way of preventing subsequent tendon ruptures after an initial rupture in this condition.

Key words: ochronosis, multiple tendon ruptures, medical prophylaxis in ochronosis

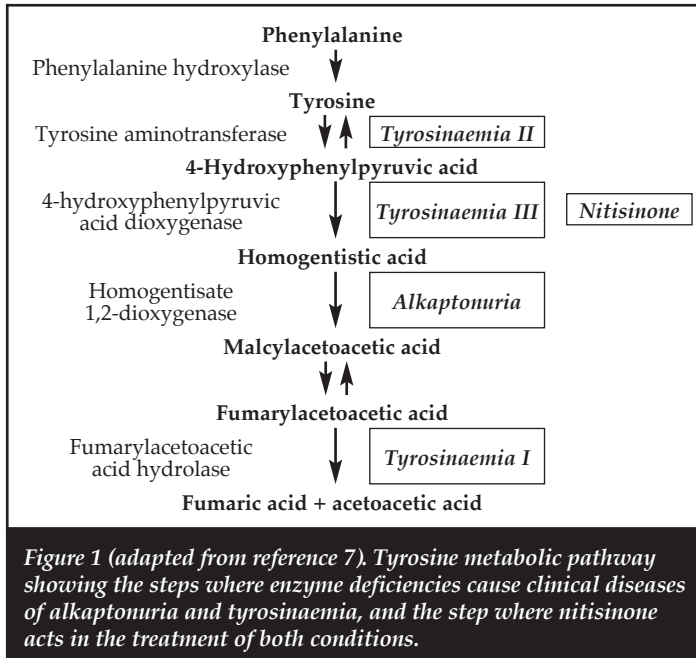
Introduction

Ochronosis is the deposition of products of homogentisic acid (HGA) in the connective tissue resulting in bluish-black discoloration of connective tissue. This is easily visible in the cartilage of the ear. Ochronosis is a major manifestation of alkaptonuria, a rare autosomal recessive disorder of metabolism.

The basic cause is the deficiency of the enzyme HGA 1,2-dioxygenase¹, which is an enzyme in the tyrosine degradation pathway (Figure 1). This results in accumulation of HGA. The HGA is oxidised to benzoquinones that polymerise and bind to connective tissue and cartilage. This leads to weakness and subsequent rupture of tendons, and early degeneration of articular cartilage. The massive accumulation of HGA in urine causes urine to darken on standing or on exposure to alkaline conditions.

There are a few reports in the literature of isolated rupture of the Achilles tendon.^{1,3} We report on a patient who had a rupture of the quadriceps tendon, followed by rupture of the Achilles tendon some months later, and then rupture of tendons around the knee after a further few months. To the knowledge of the authors there have been no reports in the literature describing multiple sequential ruptures. This multiple sequential tendon rupture raises the question whether we should look at prophylaxis methods after an initial tendon rupture, just as it is done after an initial fragility fracture in osteoporosis.

Ochronosis is a major manifestation of alkaptonuria, a rare autosomal recessive disorder of metabolism



Case report

A 49-year-old male patient was admitted to hospital following a twisting injury to the foot. He felt a snap in the back of the right heel. Clinical history revealed that he had had surgery to the right knee some two years earlier for a quadriceps tendon rupture. Examination showed a positive Thompson test (calf comprehension test). Ultrasound confirmed a rupture of the Achilles tendon.

After discussing the treatment options, he was taken to theatre for open repair of the Achilles tendon. At surgery the striking feature was that the soft tissue and the bone were stained black. Specimens were taken for histopathology. The tendon ends were debrided, approximated and repaired with no. 5 fibre wire suture and a running nylon suture for the paratenon. He had an uneventful post-operative recovery. He was lost to follow-up before we could find the cause of the dark stained tissue.

He presented again 11 months later with bilateral knee swellings and an inability to walk. This happened when he was involved in a scuffle. He reported that the previous operation to the heel had healed and he had good function of that leg. Clinically the Achilles tendon had healed. He had good dorsiflexion of the ankle. There was a healed surgical scar on the right knee. A diagnosis of a torn right patella tendon and left quadriceps tendon was made.

He was taken to theatre for surgical repair. The surgeon (TQB) noted that the tissues were black, as had been noted in the previous surgical records. There was advanced osteoarthritis with eburnation of cartilage and exposed, black sub-chondral bone. Interestingly, the previously repaired quadriceps tendon on the right side had healed well. The tendons were repaired in a standard manner.

The pathologist was asked to review the histology, which was initially reported as 'necrotic bone spicules, cause not known, no haemosiderin, no crystals present, and no evidence of neoplasm'. The revised report read: '... features of tendon rupture consistent with ochronosis.'

Urine examination showed elevated levels of HGA. X-ray of the lumbar spine showed calcification of the inter-vertebral disc (*Figure 2*). The knees showed osteoarthritic changes (*Figure 3*). On further questioning, the patient admitted that his urine was dark.

Our investigations thus confirmed that ochronosis was the cause of his multiple tendon ruptures.

Discussion

Ochronosis is a very rare autosomal-recessive disorder of metabolism. It results from a deficiency of the enzyme HGA oxidase, which is involved in the degradation of tyrosine. This results in accumulation of HGA and its degradation products in the tissues. It occurs worldwide but the prevalence is lower than 1:250 000 in most populations.²

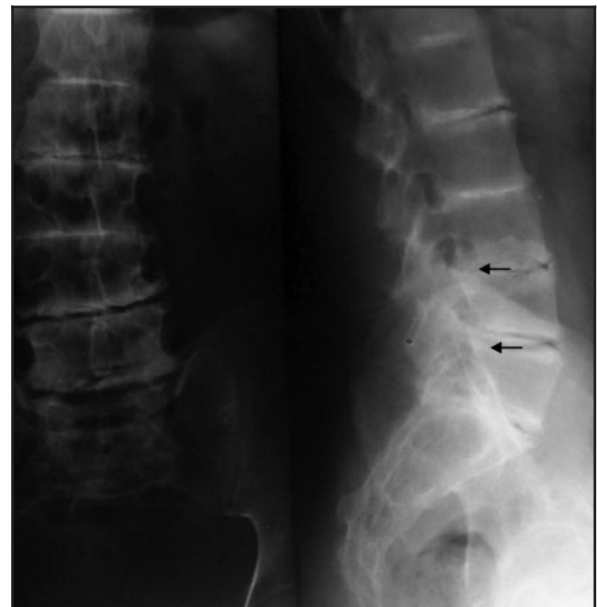

Figure 2. Calcification of the inter-vertebral discs (see arrows)

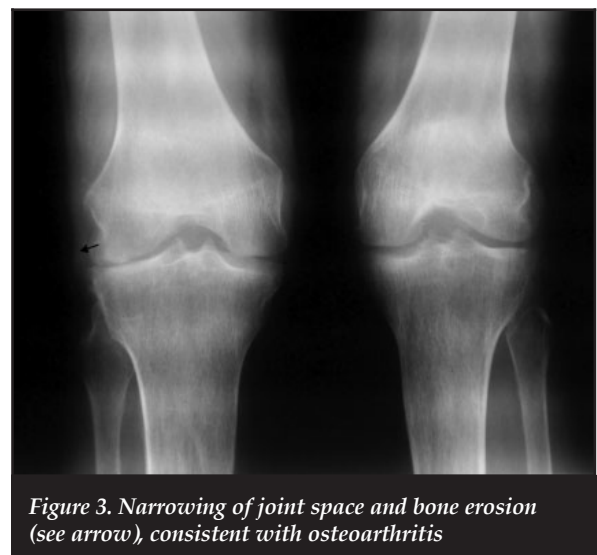


Figure 3. Narrowing of joint space and bone erosion (see arrow), consistent with osteoarthritis

The disease often manifests itself in adult life after the fourth decade. Our patient presented with the disease at 49 years of age. The accumulation of HGA degradation products are responsible for the dark staining of the connective tissue, from which the term ochronosis is derived. Darkening of the urine is often the first sign, but is seldom reported by the patient. Darkening of the sub-cutaneous cartilage, especially that of the ear is a very common clinical sign. This is, however, not easily seen in dark-skinned individuals, like our patient.

Orthopaedic manifestations of the disease are caused by deposition of HGA in connective tissue.¹ This weakens the connective tissue, leading to rupture of tendons and early degeneration of the cartilage.

The orthopaedic manifestations are the following:

1. Back pain.
It is due to dystrophic calcification of the inter-vertebral disc, as seen in our patient's X-ray (Figure 2).
2. Tendon rupture.^{2,3}
This is caused by weakening of the tendons. The most reported tendon rupture is the tendo-Achilles.
3. Arthritis.^{4,5}
This involves mainly the large joints, like hip and knee. It is due to deposition of the HGA metabolites into the articular cartilage, causing early degeneration of the articular cartilage, as shown in our patient's knee (Figure 3). Joint degeneration often manifests itself after the third decade.

The accumulation of HGA degradation products are responsible for the dark staining of the connective tissue, from which the term ochronosis is derived

Non-orthopaedic manifestations are important. The orthopaedic surgeon needs to be aware of the other organs that may be affected, especially if surgical treatment is being planned.

There is deposition into the heart valves, causing dystrophic calcification of the valves, aortic stenosis, and coronary artery disease. Kidneys are also affected causing renal stones, and deposition into ocular tissue leads to disturbances of vision.¹

Treatment of the orthopaedic complications of alkaptonuria is determined by the nature of the particular orthopaedic condition, namely, repair of a tendon rupture, conservative treatment of osteoarthritis initially, up to total joint replacement.

All reported cases of tendon rupture involve isolated tendons. Ochronosis is a systemic disease. It is therefore understandable that other tendons are also involved and will rupture with time, as happened with this patient. This is similar to an isolated hip fracture in osteoporosis; with time it will be followed by other fragility fractures. It is for this reason it is recommended that these patients be started on treatment for osteoporosis.

This raises the need to look for prophylactic therapy in patients with tendon rupture in ochronosis. Perhaps our patient would not have had the subsequent tendon ruptures had he been started on effective prophylactic therapy after the first injury.

Cases of successful medical treatment have been reported in the literature. Morava *et al*⁶ reported on a child with alkaptonuria where symptoms of joint pain, darkening of urine, and radiologic signs of joint involvement were reversed by 1) putting the child on a diet that restricts the intake of tyrosine, thus reducing HGA formation, and 2) adding a reducing agent, ascorbic acid. They recommended that patients with Alkaptonuria be put on a diet, restricting protein intake to 1.3 g/kg/day and take ascorbic acid at a dose of 0.5 to 1 g/day.

Other approaches to medical treatment involve reducing HGA production. This involves administration of 2-(2-nitro-4-trifluoronitryl)-1,3-cyclohexanedione or nitisinone.⁷ This compound inhibits 4-hydroxy phenylpyruvic deoxygenase, the enzyme that produces HGA, as shown in Figure 1.

Nitisinone has been used to decrease the formation of toxic oxidising metabolites in tyrosinaemia type I children and constitutes the treatment of choice in this otherwise fatal disease. Low-dose nitisinone has been shown to reduce urinary excretion of HGA by 67% and more.⁸

Although medical treatment is promising in the treatment and prevention of orthopaedic complications of ochronosis, there are not enough clinical trials to support the routine use of medical treatment in this disease.⁸ Also because the condition is so rare, progress in this field of medicine is probably going to be slow.

Conclusion

Ochronosis is a rare metabolic disease, leading to orthopaedic complications of tendon rupture, osteoarthritis and back pain. It is possible that we may reduce the complications by a combination of protein restriction diet, ascorbic acid and nitisinone. Clinical trials need to continue before these treatment modalities can be used routinely in this disease. The available medical evidence shows that medical treatment is the treatment of the future in this rare condition.

The content of this article is the sole work of the authors. No benefits of any form have been received or will be received from a commercial party related directly or indirectly to the subject of this article.

References

1. Babanagare SV, Deshmukh SD, Khadilkar MS, Patil AA. Ochronosis: a report of three cases and review of the literature. *Indian journal of pathology & microbiology*, 2011;54(3):626-28.
2. Khaled A, Kerkeni N, Hawilo A, Faza'a B, Kamoun MR. Endogenous ochronosis: case report and a systematic review of the literature. *Int J Dermatol*. 2011 Mar;50(3):262-67.
3. Prakash V, Boston DA, Packer GJ, Raza SA. Rupture of a black tendon: ochronotic tendo-Achilles rupture. *The Foot*, 2003 Mar;13(1):49-50.
4. Carrier DA, Harris CM. Bilateral hip and bilateral knee arthroplasties in a patient with ochronotic arthropathy. *Orthop Rev*. 1990 Nov;19(11):1005-1009.
5. Laskar FH, Sargison KD. Ochronotic arthropathy. A review with four case reports. *J Bone Joint Surg Br*. 1970 Nov;52(4):653-66.
6. Morava E, Kosztalanyi G, Engelke UFH, Wevers RA. Reversal of clinical symptoms and radiographic abnormalities with protein restriction and ascorbic acid in alkaptonuria. *Ann Clin Biochem*, 2003 Jan;40(Pt 1):108-11.
7. Suwannarat P, O'Brien K, Perry MB, Sebring N, Bernardini I, Kaiser-Kupfer MI, Rubin BI, Tsilou E, Gerber LH, Gahl WA. Use of nitisinone in patients with alkaptonuria. *Metabolism*, 2005 Jun;54(6):719-28.
8. Introne WJ, Perry MB, Troendle J, Tsilou E, Kayser MA, Suwannarat P, O'Brien KE, Bryant J, Sachdev V, Reynolds JC, Moylan E, Bernardini I, Gahl WA. A 3-year randomized therapeutic trial of nitisinone in alkaptonuria. *Mol Genet Metab*, 2011 Aug;103(4):307-14.