



## Chronic bilateral anterior shoulder dislocation

A Y Abdulkadir, O A M Adesiyun, O R Jimoh, A O D Amole

**To the Editor:** Chronic bilateral shoulder dislocation (an unreduced dislocated shoulder beyond 3 weeks) is rare.<sup>1-3</sup> A 35-year-old man presented with bilateral anterior dislocation of the shoulder (BADS) with bilateral brachial plexus injuries following a nightmare. He had been undiagnosed for 2 years because he felt the problem was spiritual and had sought unorthodox treatment. He had repeated episodes of tonic-clonic convulsions and increasing limitation of movement across both shoulders while on traditional treatment.

When the patient presented at hospital an initial diagnosis of upper limb neuromuscular disorder was made because he had bilateral and symmetrical loss of deltoid contours and upper limb muscle wasting; was unable to abduct or extend the shoulders beyond a resting position, and had diminished sensation in both hands. In addition there was sagging of both upper limbs in adduction and much reduced upper limb power. The diagnosis of bilateral shoulder dislocation with brachial plexus injury was made on clinical examination and the finding on a plain radiograph that both humeral heads were in a subcoracoid position (Fig. 1). He declined open reduction surgery.

### Discussion

Chronic bilateral shoulder dislocation is rare,<sup>1-3</sup> and we could find only 2 cases in the literature.<sup>4,5</sup> BADS was first described in 1902 in a patient with muscular contraction caused by a camphor overdose.<sup>1</sup> Sports injuries, seizures, electrical shock, electroconvulsive therapy, drug overdose, neuromuscular disorders and psychiatric disturbances have been implicated.<sup>1-6</sup> The presumed causation in our case is seizure disorder, while ignorance resulting in inappropriate care led to the chronicity. Of 32 cases of chronic shoulder dislocation<sup>3</sup> all were unilateral (31 anterior subcoracoid and 1 posterior) dislocations. Clinical diagnoses of dislocation types and associated injuries may be inaccurate without imaging.<sup>1,3,4</sup>

Like our case, which occurred during sleep, BADS in a young insulin-dependent diabetic followed an episode of

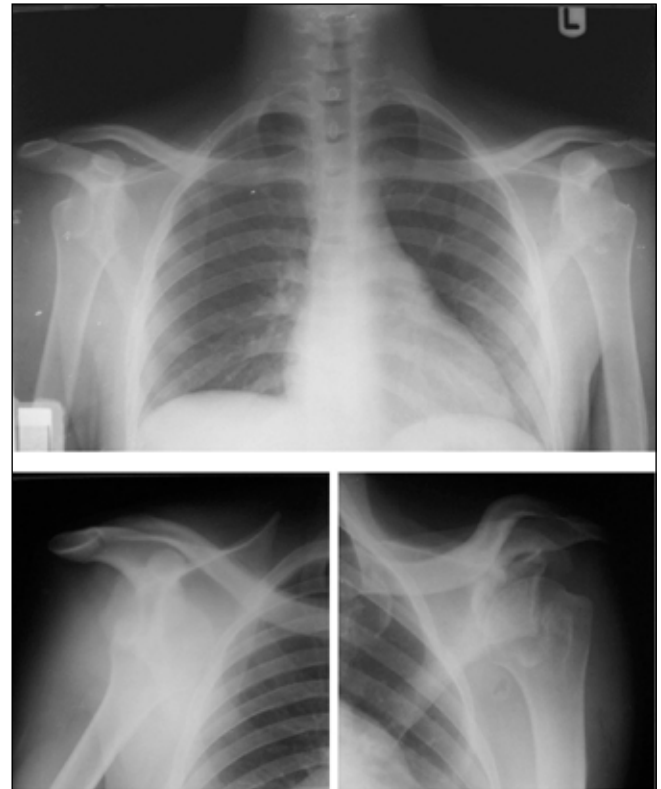


Fig. 1. Radiographs of the chest and shoulders in a 35-year-old man with bilateral sub-coracoid anterior dislocation of the shoulders.

nocturnal hypoglycaemia.<sup>2</sup> Violent muscle contraction during a seizure, with the humeri in external rotation, is the most probable explanation of BADS in these cases.<sup>1,4</sup> Chronic compression of the humeral heads in the sub-coracoid position may cause brachial plexus injury, which may take months to recover, leaving the patient with residual shoulder stiffness.<sup>6</sup> Chronic BADS is treated by open reduction.<sup>1,3,6</sup>

We acknowledge the contribution of Mr Nwajuhor Obinna, the imaging scientist.

### References

- Dunlop CC. Bilateral anterior shoulder dislocation: A case report and review of the literature. *Acta Orthop Belg* 2002; 68: 168-170.
- Litchfield JC, Subhedar VY, Beevers DG, Patel HT. Bilateral dislocation of the shoulders due to nocturnal hypoglycaemia. *Postgrad Med J* 1988; 64: 450-452.
- Goga IE. Chronic shoulder dislocations. *J Shoulder Elbow Surg* 2003; 12: 446-450.
- Costigan PS, Binns MS, Wallace WA. Undiagnosed bilateral anterior dislocation of the shoulder. *Injury* 1990; 21: 409.
- Mihai R, Dixon JH. Bilateral atraumatic dislocation of the shoulder. *J Accid Emerg Med* 1999; 16(6): 460.
- Mehta MP, Kottamasu SR. Anterior dislocation of the shoulders with bilateral brachial plexus injury. *Ann Emerg Med* 1989; 18: 589-591.

Accepted 21 January 2009.

Department of Radiology, University of Ilorin Teaching Hospital, Ilorin, Kwara State, Nigeria

A Y Abdulkadir, MB BS, FMCR  
O A M Adesiyun, MB BS, FWACS  
A O D Amole, MB BS, FWACS

Division of Orthopaedic Surgery, University of Ilorin Teaching Hospital

O R Jimoh, MB BS, FWACS

Corresponding author: A Y Abdulkadir (akyisau@yahoo.com)