

Temporary vascular shunting in vascular trauma: A 10-year review from a civilian trauma centre

J C Oliver, H Gill, A J Nicol, S Edu, P H Navsaria

Trauma Centre, Groote Schuur Hospital, and Faculty of Health Sciences, University of Cape Town

J C Oliver, MRCS

H Gill, MB ChB, FCS (SA)

A J Nicol, FCS (SA), PhD

S Edu, MB ChB, FCS (SA)

P H Navsaria, MMed (Surg), FCS (SA)

Corresponding author: P H Navsaria (pradeep.navsaria@uct.ac.za)

Background. Temporary intravascular shunts (TIVSs) can replace immediate definitive repair as a damage control procedure in vascular trauma. We evaluated their use in an urban trauma centre with a high incidence of penetrating trauma.

Method. A retrospective chart review of all patients treated with a TIVS in a single centre between January 2000 and December 2009.

Results. Thirty-five TIVSs were placed during the study period: 22 were part of a damage control procedure, 7 were inserted at a peripheral hospital without vascular surgical expertise prior to transfer, and 6 were used during fixation of a lower limb fracture with an associated vascular injury. There were 7 amputations and 5 deaths, 4 of the TIVSs thrombosed, and a further 3 dislodged or migrated. Twenty-five patients underwent definitive repair with an interposition graft, 1 primary anastomosis was achieved, and 1 extra-anatomical bypass was performed. Five patients with non-viable limbs had the vessel ligated.

Conclusions. A TIVS in the damage control setting is both life- and limb-saving. These shunts can be inserted safely in a facility without access to a surgeon with vascular surgery experience if there is uncontrollable bleeding or the delay to definitive vascular surgery is likely to be more than 6 hours. A definitive procedure should be performed within 24 hours.

S Afr J Surg 2013;51(1):6-10. DOI:10.7196/SAJS.1504

Vascular trauma is associated with a high mortality rate, approaching 50% in some series of iliac vessel injuries,^[1] and when it is combined with a delay of over 6 hours to surgical reperfusion of a limb, amputation is often necessary.^[2] Many of the innovations in the management of vascular injuries have arisen from experience obtained through care of wartime injuries. During World War I and II injured vessels were mainly ligated, with a high amputation rate. In the Korean and Vietnam conflicts, vascular repair and vein grafts were commonly used. Use of a temporary intravascular shunt (TIVS) was first described in the military as early as 1919. Its role became more prominent during the conflicts in Northern Ireland for fractures with associated vascular injuries^[3] and in the Gulf since 1991, both in the setting of a physiologically unstable patient requiring a damage control procedure, and in the patient with an acutely ischaemic limb in a forwarding hospital where there may be no time for extensive surgical procedures, or expertise or equipment for formal vascular repair.^[4] Since the developments in the Gulf War, use of TIVSs has also been advocated in the civilian trauma patient.^[5] There are, however, only case reports and small case series in the literature describing their use. The aim of this study was to evaluate the use of TIVSs in an urban trauma centre with a high incidence of penetrating trauma, and outcome in patients so treated.

Material and methods

The medical records of all patients with a TIVS treated in the Trauma Centre at Groote Schuur Hospital, Cape Town, South Africa, during the 10-year period 1 January 2000 - 31 December 2009 were reviewed. Data regarding patient demographics, mechanism of injury, admission observations and blood transfusion requirements were retrieved from patient records. Operation notes documented the arteries injured, the method of repair and associated injuries. Admission to the intensive care unit (ICU), duration of ICU and hospital stays, and complications were noted. Injury severity was categorised using the Revised Trauma Score (RTS).

Insertion of the shunt was at the discretion of the trauma surgeon. Embolectomy of the artery was routinely performed and local intra-arterial heparinised saline administered. No systemic anticoagulation was used. All shunts comprised a piece of plastic tubing cut from a high-flow intravenous line, nasogastric tube or chest tube, of similar size to the injured vessel. The TIVS was cut to length to fill the defect with a 2 cm overlap on each side (Fig. 1), and secured in place with a silk tie, tight enough to ensure that the tubing would not fall out, but not so tight that the lumen of the tubing was narrowed. No TIVSs were placed in veins, and all associated venous injuries were ligated. Fasciotomy

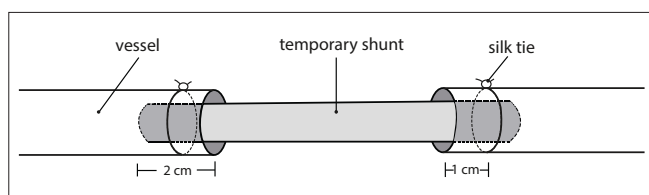


Fig. 1. Illustration of placement of the plastic tubing within a damaged artery to form a temporary intravascular shunt.

was performed if the time to reperfusion was more than 4 - 6 hours, or there was a suggestion of tense compartments after reperfusion.

The indications for placement of a TIVS were divided into three groups. The first group comprised patients with a vascular injury associated with indications for damage control laparotomy, temperature $<34^{\circ}\text{C}$, pH <7.2 , >10 units blood transfusion, systolic blood pressure <90 mmHg for >60 minutes and expected operating time >60 minutes, in line with the recommendations of the *Manual of Definitive Surgical Trauma Care*.^[5] The next group were patients with a peripheral vascular injury, whose initial surgery was performed at a hospital without a surgeon experienced in vascular surgery. For these patients, a TIVS was inserted for two indications: acute limb ischaemia with the limb likely to become non-viable if reperfusion was delayed, or ongoing torrential bleeding. The third group of patients had lower limb fractures with an associated vascular injury. The TIVS was inserted at the start of the procedure, and definitive repair was done once the fracture had been formally fixed.

Results

Thirty-five patients were treated with a TIVS during the 10-year study period. Of these, 22 (62.9%) had the shunt inserted as part of a damage control procedure, 7 patients were referred from a hospital without access to vascular surgical facilities with the TIVS *in situ*, and in the remaining 6 patients the TIVS was inserted during repair of a lower limb fracture with an associated vascular injury.

Damage control procedure

Twenty-two patients had a TIVS inserted as part of a damage control procedure. In 21 cases this was for penetrating trauma; 15 patients had sustained a low-velocity gunshot wound and 6 a stab wound. Table 1 shows the distribution of patient observations during the first 24 hours of treatment. On admission they were acidotic and hypothermic, with a mean pH of 7.21 and a mean core temperature of 34.7°C . Table 2 shows the anatomical distribution of the shunts placed, the most commonly shunted artery being the superficial femoral artery.

The overall mortality rate was 22.7% (5 out of 22 patients), with 5 of the 17 patients who survived (29.4%) requiring an amputation. Six patients did not receive a fasciotomy; there were no adverse complications, and none of these patients underwent amputation.

Among these critically ill patients, 3 did not survive long enough for a relook procedure. In the 19 patients who survived to relook, only 2 of the shunts were thrombosed. One patient with an axillary artery injury that was ligated with no adverse outcome and another with a common iliac artery injury required an above-

Table 1. Initial observations on patients who underwent a temporary vascular shunt for a damage control procedure

Demographics	Mean (SD)
Total number	22
Age (years)	28.7 (9.7)
Systolic blood pressure (mmHg)	78 (26.0)
Heart rate (/min)	112 (18.7)
Revised Trauma Score	5.7 (2.1)
Injury Severity Score	34 (15)
Arterial pH on admission	7.21 (2.1)
Base deficit on admission	-11.8 (5.1)
Haemoglobin concentration on admission (g/dl)	7.2 (2.1)
Core temperature on arrival in the operating theatre ($^{\circ}\text{C}$)	34.7 (1.3)
Packed red blood cells transfused in first 24 hours (units)	12.4 (6.2)

SD = standard deviation.

Table 2. Anatomical distribution of the 22 arteries shunted in the damage control setting, with outcome

Artery	n	Fasciotomy	Amputation	Death
Aorta	1	0	0	1
Common iliac	2	1	1	2
External iliac	5	4	1	1
Common femoral	1	1	1	0
Superficial femoral	6	3	1	1
Popliteal	1	1	1	0
Subclavian	2	0	0	0
Axillary	3	2	0	0
Brachial	1	1	1	0
Total, N	22	13	6	5

knee amputation. Of the 17 grafts that were functioning at relook, 14 were repaired with a saphenous vein or polytetrafluoroethylene (PTFE) graft. One patient with a common iliac artery injury underwent a femoral-femoral crossover graft because of an associated colonic injury. One patient with a subclavian artery injury underwent ligation of the vessel with no further vascular complications, and a common femoral artery was ligated in another patient with a non-viable limb; the patient proceeded to amputation. No arteries were primarily repaired. Three of 15 patients who were successfully grafted (20.0%) required subsequent amputation.

Transferred patients

Seven patients had shunts placed at a peripheral hospital without vascular surgical expertise. Four of these procedures were for an acutely ischaemic limb and the remaining 3 for uncontrolled bleeding. There were no deaths and 1 patient required amputation, as shown in Table 3.

During fracture fixation

Six patients had a TIVS placed prior to an orthopaedic procedure following combined arterial and bone injury. Four had sustained gunshot wounds and 2 blunt trauma. Five superficial femoral artery injuries were associated with a femur fracture, and one popliteal artery injury was associated with fracture of the tibia and fibula. Among these patients the mean pre-operative ischaemic time was 6.2 hours (range 4 - 8.5 hours). Five of the patients required fasciotomy for established compartment syndrome with delayed skin graft closure. Five of the vessels were repaired with a reversed saphenous vein graft, and 1 of the patients with a femur fracture underwent successful primary repair. The patient with the popliteal artery injury developed thrombosis of the definitive vascular repair, which required two revisions; amputation was ultimately necessary.

Shunt complications

Among the 26 patients with a TIVS left *in situ* for optimisation of their condition and/or transfer, 4 shunts were thrombosed at relook. Table 4 shows the distribution of the thrombosed shunts in relation to the length of time between insertion and definitive repair. There were no shunt thromboses within 24 hours of insertion.

There were 2 cases of dislodged shunts. One occurred during an orthopaedic procedure, which immediately proceeded to definitive repair, and the second after a damage control procedure while the patient was being wheeled into the ICU, with a further episode of catastrophic bleeding requiring emergency re-exploration in theatre and repositioning of the shunt, as the patient was too unstable for a definitive repair. This patient subsequently died. One TIVS in the brachial artery migrated distally, requiring removal with an embolectomy catheter. There were no vascular complications from this event.

Discussion

We have described a total of 35 patients treated with a TIVS in the Groote Schuur Hospital Trauma Centre over a period of 10 years. The centre manages in the region of 90 major trauma resuscitations per month, and this low frequency is reflected in the literature, with only 395 TIVSs recorded by the US National Trauma Data Bank during the 4-year period 2001 - 2005. Of these hospitals only 6 inserted more than 5 shunts,^[6] and the most common indication for their use (185, 47%) was during

Table 4. Number of temporary vascular shunts thrombosed in relation to length of time *in situ* before relook among the 26 patients who survived to relook

	≤24 hours	24 - 48 hours	> 48 hours
Number, N	6	9	11
Shunt thrombosed	0	2	2

orthopaedic reconstruction after blunt trauma with combined extremity fracture and vascular injury.

In our series, all the shunts were constructed using a piece of plastic tubing from a high-flow intravenous line, nasogastric tube or chest tube. These are very cheap and immediately available in all operating theatres. Currently, the only commercially available shunts are those designed for use during carotid artery endarterectomy. These include the Pruitt-Inahara shunt (LeMaitre Vascular, Burlington, NJ), with a balloon on each end to secure the shunt, protecting the vessel and avoiding the need for ties. It also includes a T-port for injecting, aspirating or pressure monitoring. This is of no benefit when the TIVS is used for damage control or hospital transfer purposes, and could cause the shunt to displace.^[7] The Argyle shunt (CR Bard, Billerica, MA, USA) is a straight PVC tube which is available as 8, 10, 12 or 14F and can be looped, which again is not helpful when the shunt is left *in situ*. The Javid carotid shunt (Bard Peripheral Vascular, AZ, USA) is similar but with tapered ends, and the Sundt shunt (Integra Neurosciences, Plainsboro, NJ, USA) comprises a silicone tube with stainless steel reinforcements and cone-shaped bulbs to avoid the need for external fixation. The type of shunt used often depends on the vessel injured, with larger vessels such as the common iliac artery or aorta being too large for these commercial tubes. In this situation, successful use of a bifurcated haemodialysis catheter (Mahurkar MAXID; Tyco Healthcare, Mansfield, MA) has been described in a single case report,^[8] or a chest drain cut to size may be inserted. A recent review of the literature suggests that plastic tubing and custom-designed shunts have equally good patency rates when used as a TIVS during orthopaedic fixation.^[9] However, a commercial shunt designed specifically for the trauma setting is currently under review.^[4]

Time to removal of the shunt represents a balance between removing the shunt before it becomes thrombosed, and ensuring that the patient has been sufficiently resuscitated. There were

Table 3. Patients transferred from a hospital without facilities for vascular surgery

Patient number	Mechanism of injury	Artery shunted	Indication for shunt	Fasciotomy	Shunt patent	Procedure	Amputation
1	Stab	Brachial	Acute ischaemia	Yes	Yes	Synthetic graft	No
2	Stab	Brachial	Acute ischaemia	No	No	RSVG	No
3	Stab	Brachial	Bleeding	No	No	RSVG	No
4	Stab	Common carotid	Bleeding	No	Yes	Synthetic graft	No
5	Stab	Subclavian	Bleeding	No	Yes	RSVG	No
6	Stab	Superficial femoral	Acute ischaemia	Yes	Yes	RSVG	No
7	Gunshot	Superficial femoral	Acute ischaemia	Yes	Yes	Ligation	Yes

RSVG = reversed saphenous vein graft.

no shunt thromboses in this series when the shunt was replaced within 24 hours. The longest documented temporary shunt to remain patent was *in situ* for 10 days.^[9] Evidence for the optimal time limit before removal of a TIVS is lacking. The *Manual of Definitive Surgical Trauma Care* recommends removal within 24 hours.^[5] A recent animal study looking at thrombosis rates in a pig superior mesenteric artery model showed that shunts were 100% patent at 3 and 6 hours, but after 9 hours 50% and by 12 hours 100% were occluded.^[10] It has been suggested that rates of thrombosis can be reduced by also shunting an associated venous injury, by performing a fasciotomy, by avoiding looping or movement of the shunt, and by ensuring that the shunt is appropriately sized for the vessel.^[9] After reperfusion of an acutely ischaemic limb, great care must be taken to avoid compartment syndrome, which itself can lead to amputation.^[11] Prophylactic fasciotomy has been advised in these patients; however, early revascularisation reduces this requirement, and work in Belfast compared outcome during the 10 years before and after 1979, when a new policy of shunting both the artery and the vein in complex fractures with vascular injuries was introduced. The authors demonstrated a markedly reduced requirement for fasciotomy and also a reduction in the incidences of contracture and amputation.^[3] Twenty-one of the 32 patients who survived to removal of the shunt had a fasciotomy performed. The need for fasciotomy was lowest in the group whose TIVSs were inserted before transfer, and this may be because these patients had the shortest ischaemic time.

Vascular injuries associated with limb fractures are uncommon, and the operative sequence of which injury to repair first has only been investigated by small case series in the literature. However, these injuries are associated with a high amputation rate and their management requires a very careful multidisciplinary team approach. It is suggested that using a TIVS during repair of these injuries reduces the time to reperfusion, which is of critical importance, because if time to reperfusion is less than 6 hours, the amputation rate is low. After this time period the amputation rate increases dramatically. A second benefit is avoiding the risk of damage to a fragile vascular repair during aggressive orthopaedic procedures. A retrospective study compared the use of TIVSs prior to orthopaedic fixation and then definitive vascular repair in 7 patients with blunt popliteal artery injuries with 10 historical controls.^[12] Mean intra-operative time to reperfusion was 30 minutes less when a temporary shunt was used, and the maximum time to reperfusion was 30 minutes in the TIVS group compared with 80 minutes in the non-shunt group. There was also a decreased need for fasciotomy in the TIVS group, and fewer complications of fasciotomy wounds, leading to shorter total hospital stay. In this study the amputation rate was directly related to total ischaemic time. A potential disadvantage of the TIVS, however, was that no patient who had a shunt inserted was able to undergo subsequent primary repair, compared with 2 patients in the non-shunt group. Another retrospective study of 27 patients over 10 years from the USA, including 9 patients who underwent TIVS,^[13] confirmed that need for a fasciotomy was much greater if the orthopaedic repair was performed first (80% v. 36%), leading to prolonged hospital stay. However, these authors did not demonstrate a difference in outcome if a TIVS was inserted as opposed to if a

formal repair was performed before orthopaedic repair. In our series, despite prolonged pre-operative ischaemic times, there was a low amputation rate following use of the TIVS.

In the hypothermic, acidotic, multiply injured trauma patient, rapid temporary surgical management of the injuries has been demonstrated to substantially improve outcome.^[14] Originally vascular injuries managed in this setting were simply ligated, which can be associated with high amputation rates, although the latter is highly dependent on the vessel injured.^[15] Use of a TIVS in the damage control setting is becoming more widespread, especially by military surgeons.^[16] Successful shunting of all major vessels has been described, even the aorta, with use of a double shunt to the common iliac arteries associated with complete recovery and no limb loss.^[17] Although there are several small series of outcomes following use of a TIVS in the damage control setting, the first evidence to demonstrate its superiority to ligation was published by Ball *et al.* in 2010.^[15] They used historical controls to demonstrate a reduction in the amputation rate from 47% to 0% with use of TIVSs and a reduction in the fasciotomy rate from 93% to 43%. They also showed a reduction in mortality in patients with a TIVS, which they considered could be related to a reduction in septic complications with avoidance of ischaemia. The largest previous civilian series of the use of a TIVS in the damage control setting reported 3 graft thromboses out of 35 cases, compared with 2 out of 19 in our series.^[7]

Use of a TIVS during transfer to a more specialised centre was first described in 1989, when a case in which a shunt was used during a 16-hour air transfer to a regional trauma centre was described. The shunt was patent on arrival, but the limb was later amputated because of missed compartment syndrome.^[18] This type of use has become much more widespread in the military setting. Since the first Gulf conflict in Iraq in 1991, forward operating theatres have been increasingly used to reduce the time between injury and initial surgery. TIVSs have been used successfully in these patients before transfer back to a field hospital and more definitive care.^[19-21] The largest military experience of TIVS prior to transfer identified 64 patients over 4½ years. These authors compared the outcome of these patients with 61 matched controls who did not receive forward surgery.^[19] They showed that forward surgery with a TIVS did not worsen patient outcome, and the two groups showed similar rates of amputation-free survival (TIVS 77% v. controls 78%). However, the TIVS group had a significantly higher Injury Severity Score (TIVS 18 v. controls 15; $p < 0.05$) and higher blood transfusion requirements (TIVS 18 units of blood v. controls 6; $p < 0.01$), and it is therefore likely that the shunts did have some beneficial effect. With the changes in training of general surgeons and the centralisation of vascular care to major centres, it is becoming increasingly likely that a trauma victim will arrive at a local hospital that does not have facilities to provide formal vascular repair. In this setting a TIVS prior to transfer could save the limb. Our experience is the first description of shunting in the civilian setting before hospital transfer. Although our numbers are small, our data show good shunt patency (5 out of 7) and low amputation rates (1 out of 7). These results are similar to those achieved in the military setting.^[20] However, in our series shunts were not routinely inserted into venous injuries at the referral hospitals; these injured vessels were simply ligated, with no complaints of limb swelling up to hospital discharge.

Conclusions

Use of a TIVS can be life- and limb-saving and should be considered an important component of the surgical armamentarium of the general and trauma surgeon. Commercially available shunts are not essential, and the equipment required to produce a shunt is available in any operating theatre. The decision to insert a TIVS must be a careful one, as its use usually necessitates a vascular graft when a primary repair may otherwise have been possible. TIVSs can thrombose or dislodge with disastrous consequences, so patients must be monitored closely. Prophylactic fasciotomy should be performed liberally, but using a shunt early may reduce the need for this procedure.

REFERENCES

- Asensio JA, Petrone P, Roldan G, et al. Analysis of 185 iliac vessel injuries: Risk factors and predictors of outcome. *Arch Surg* 2003;138(11):1187-1193; discussion 1193-1194.
- Sfeir RE, Khoury GS, Haddad FF, Fakh RR, Khalifeh MJ. Injury to the popliteal vessels: The Lebanese war experience. *World J Surg* 1992;16(6):1156-1159.
- Barros D'Sa AA, Harkin DW, Blair PH, Hood JM, McIlrath E. The Belfast approach to managing complex lower limb vascular injuries. *Eur J Vasc Endovasc Surg* 2006;32(3):246-256.
- Hancock CH, Rasmussen LC, Walker SC, Rich CR. History of temporary intravascular shunts in the management of vascular injury. *J Vasc Surg* 2010;52(5):1405-1409. [http://dx.doi.org/10.1016/j.jvs.2010.04.060]
- Boffard KD. *Damage control surgery. Manual of Definitive Surgical Trauma Care, Part 4.* 2nd ed. London: Hodder Arnold, 2007.
- Ball CG, Kirkpatrick AW, Rajani RR, et al. Temporary intravascular shunts: When are we really using them according to the NTDB? *Am Surg* 2009;75(7):605-607.
- Subramanian A, Vercruyse G, Dente C, Wyrzykowski A, King E, Feliciano DV. A decade's experience with temporary intravascular shunts at a civilian level I trauma center. *J Trauma* 2008;65(2):316-324; discussion 324-326. [http://dx.doi.org/10.1097/TA.0b013e31817e5132]
- Choudry R, Schmieder F, Blebea J, Goldberg A. Temporary femoral artery bifurcation shunting following penetrating trauma. *J Vasc Surg* 2009;49(3):779-781. [http://dx.doi.org/10.1016/j.jvs.2008.11.041]
- Ding W, Wu X, Li J. Temporary intravascular shunts used as a damage control surgery adjunct in complex vascular injury: Collective review. *Injury* 2008;39(9):970-977. [http://dx.doi.org/10.1016/j.injury.2008.01.008]
- Ding W, Wu X, Meng Q, et al. Time course study on the use of temporary intravascular shunts as a damage control adjunct in a superior mesenteric artery injury model. *J Trauma* 2010;68(2):409-414. [http://dx.doi.org/10.1097/TA.0b013e31819ea416]
- Hofmeister EP, Shin AY. The role of prophylactic fasciotomy and medical treatment in limb ischemia and revascularization. *Hand Clin* 1998;14(3):457-465.
- Hossny A. Blunt popliteal artery injury with complete lower limb ischemia: Is routine use of temporary intraluminal arterial shunt justified? *J Vasc Surg* 2002;53(4):717-721. [http://dx.doi.org/10.1016/j.jvs.2004.03.003]
- McHenry TP, Holcomb JB, Aoki N, Lindsey RW. Fractures with major vascular injuries from gunshot wounds: Implications of surgical sequence. *J Trauma* 2002;53(4):717-721. [http://dx.doi.org/10.1097/00005373-200210000-00016]
- Rotondo MF, Schwab CW, McGonigal MD, et al. 'Damage control': an approach for improved survival in exsanguinating penetrating abdominal injury. *J Trauma* 1993;35(3):375-382; discussion 382-383. [http://dx.doi.org/10.1097/00005373-199309000-00008]
- Ball CG, Feliciano DV. Damage control techniques for common and external iliac artery injuries: Have temporary intravascular shunts replaced the need for ligation? *J Trauma* 2010;68(5):1117-1120. [http://dx.doi.org/10.1097/TA.0b013e3181d865c0]
- D'Alleyrand JC, Dutton RP, Pollak AN. Extrapolation of battlefield resuscitative care to the civilian setting. *J Surg Orthop Adv* 2010;19(1):62-69.
- Moldovan S, Granchi TS, Hirshberg A. Bilateral temporary aortoiliac shunts for vascular damage control. *J Trauma* 2003;55(3):592. [http://dx.doi.org/10.1097/01.TA.0000031179.72673.8D]
- Johansen K, Hedges G. Successful limb reperfusion by temporary arterial shunt during a 950-mile air transfer: Case report. *J Trauma* 1989;29(9):1289-1291. [http://dx.doi.org/10.1097/00005373-198909000-00020]
- Gifford SM, Aidinian G, Clouse WD, et al. Effect of temporary shunting on extremity vascular injury: An outcome analysis from the Global War on Terror vascular injury initiative. *J Vasc Surg* 2009;50(3):549-555; discussion 555-556. [http://dx.doi.org/10.1016/j.jvs.2009.03.051]
- Woodward EB, Clouse WD, Eliason JL, et al. Penetrating femoropopliteal injury during modern warfare: Experience of the Balad Vascular Registry. *J Vasc Surg* 2008;47(6):1259-1264; discussion 1264-1265. [http://dx.doi.org/10.1016/j.jvs.2008.01.052]
- Rasmussen TE, Clouse WD, Jenkins DH, Peck MA, Eliason JL, Smith DL. The use of temporary vascular shunts as a damage control adjunct in the management of wartime vascular injury. *J Trauma* 2006;61(1):8-12; discussion 12-15. [http://dx.doi.org/10.1097/01.ta.0000220668.84405.17]