

# Retropharyngeal cold abscess without Pott's spine

J Singh, H Velankar, D Shinde, N Chordia, S Budhwani

*Department of ENT, Padmashree Dr D Y Patil Medical College, Sector 5, Nerul, Navi Mumbai, India*

J Singh, MB BS, MS (ENT)

H Velankar, MB BS, MS (ENT)

D Shinde, MB BS

N Chordia, MB BS

S Budhwani, MB BS

**Corresponding author:** J Singh (jotthi@yahoo.com)

Retropharyngeal abscesses are infections deep in the neck space that can pose an immediate life-threatening emergency, with potential for airway compromise and other catastrophic complications. In adults these abscesses can develop as a result of vertebral pyogenic osteomyelitis, tuberculosis of the spine, or external injuries caused by endoscopes or foreign bodies (e.g. fish bones). Tuberculosis of the retropharyngeal space is one of the rare forms of extrapulmonary tuberculosis. Early diagnosis and treatment are necessary to prevent the serious complications of the disease.

We present a case of tuberculous retropharyngeal abscess in an adult woman without tuberculosis of the cervical spine who was managed surgically by aspirating the retropharyngeal abscess transorally, together with antituberculosis treatment.

*S Afr J Surg* 2012;50(4):137-139. DOI:10.7196/SAJS.1383

Retropharyngeal abscess results from suppuration of retropharyngeal lymph nodes in patients with upper respiratory tract infection, or from traumatic perforation of the pharynx or upper oesophagus by a foreign body. The recent literature indicates that the incidence of abscesses deep in the neck space is on the decline because of the availability of more effective antibiotics for upper respiratory infection, but cases of deep neck abscess that do

not respond to conventional antibiotic therapy are on the rise. This increase may be due to reduced immunity, debility, HIV infection, or improper or inadequate treatment. Retropharyngeal cold abscesses caused by involvement of a persistent lymph node in adults without tuberculosis of the cervical spine are rare. Such an abscess requires prompt diagnosis and early management in the form of aspiration or drainage of the abscess to achieve optimal results.

## Case report

A 38-year-old woman presented to the ENT outpatient department at our institution with a complaint of swelling in the oral cavity, which she had first noticed 7 days previously. She also had difficulty in swallowing. On examination a huge post-pharyngeal wall bulge was seen on the right side of the midline (Fig. 1). There was no bony tenderness in the cervical spine, no lymphadenopathy and no splenomegaly.

The patient had no history of ingestion of a foreign body, or of dental extraction, endoscopy or any other invasive procedure. There was also no history of difficulty in breathing, neck pain or earache. However, she had developed a swelling on the right side of the neck 4 months previously. On fine-needle aspiration cytology this was diagnosed as tubercular cervical lymphadenitis. A Mantoux test was positive. A chest radiograph and examination of the sputum for acid-fast bacilli (AFB) were not suggestive of pulmonary tuberculosis. Since then the patient had been on category I antituberculosis treatment (isoniazid 300 mg, rifampicin 600 mg, pyrazinamide 1 500 mg, ethambutol 800 mg daily for 8 weeks, followed by isoniazid 300 mg and rifampicin 600 mg daily for 16 weeks).

A lateral radiograph of the soft tissue of the neck showed a large soft-tissue shadow in the prevertebral space. On plain and contrast computed tomography (CT) scans (Figs 2 and 3) an abnormal well-defined hypodense necrotic lesion from C1 to C4 measuring 4.5×2.5×2.0 cm was seen. There was minimal peripheral rim enhancement in the right lateral wall of the nasopharynx and the posterior wall of the nasopharynx, oropharynx and laryngopharynx, and the appearance was suggestive of an abscess. The lesion extended cranially up to the nasopharyngeal isthmus and the nasopharyngeal roof and involved the right tonsillar fossa, compressing and effacing the right fossa of Rosenmüller, occluding the right eustachian tube opening, and compressing and displacing the right lateral and posterolateral walls of the nasopharynx and laryngopharynx with moderate luminal compromise of the nasopharyngeal airway. No underlying bony erosion was seen. Enzyme-linked immunosorbent assay for HIV was negative.

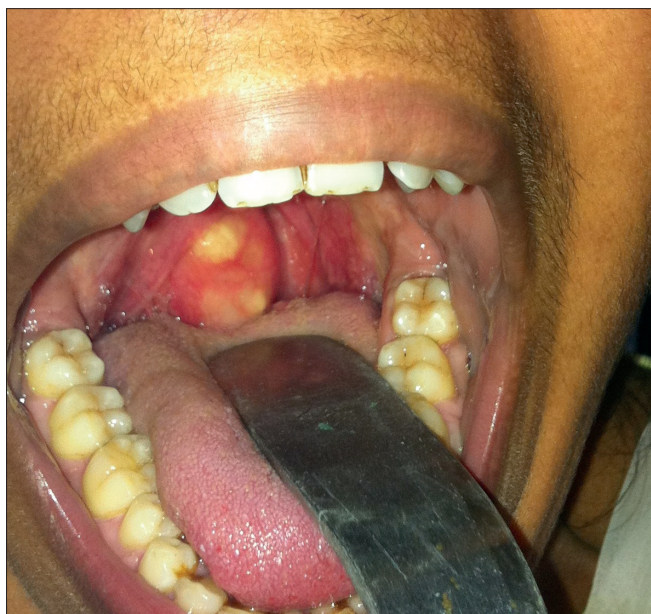

Fig. 1. Pre-operative photograph of the patient's throat.

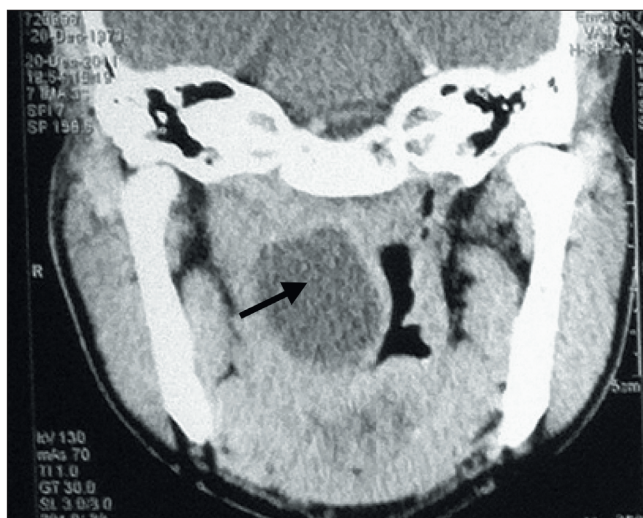


Fig. 2. Computed tomography scan of the neck, coronal section (contrast) showing abscess (well-defined hypodense necrotic lesion with minimal peripheral rim enhancement, arrow).

Wide-bore needle aspiration of the abscess was performed, with all resuscitative measures on standby. About 60 ml of pus was aspirated. The patient was given broad-spectrum antibiotics for 10 days and advised to continue the course of AKT. Pus from the retropharyngeal abscess was negative on routine culture but positive on culture for AFB.

After 2 weeks the abscess had subsided completely, and there has been no recurrence on regular follow-up.

## Discussion

The retropharyngeal space is posterior to the pharynx, bounded by the buccopharyngeal fascia anteriorly, the prevertebral fascia posteriorly and the carotid sheaths laterally. It extends superiorly to the base of the skull and inferiorly to the mediastinum and frequently serves as a conduit for spread of disease from the neck into the chest.<sup>1</sup> It contains loose areolar tissue and a group of lymph nodes.

Retropharyngeal abscess in adults is often pyogenic and usually secondary to pharyngeal or oesophageal perforation or sepsis in the throat or sinuses after a penetrating injury or when the posterior pharyngeal wall is pierced by a foreign body. Retropharyngeal tuberculous abscess is a rare presentation of the disease, even in the presence of extensive pulmonary tuberculosis.<sup>2</sup> A study of 117 patients with head and neck tuberculosis showed only 1 case of retropharyngeal abscess. Of 1 000 cases of tuberculosis of the upper respiratory tract, 99% were laryngeal and only 0 - 9% of patients had pharyngeal or nasal disease.<sup>3</sup> Tuberculous retropharyngeal abscess in adults is usually secondary to tuberculous involvement of the cervical spine; in rare cases it occurs as a result of lymphatic spread to a persistent retropharyngeal lymph node. Occasionally the abscess may be due to haematogenous spread from pulmonary tuberculosis or tuberculosis elsewhere.

In our patient, the retropharyngeal abscess was probably caused by spread of tuberculosis to the persistent lymph node in the retropharyngeal space, which usually disappears after the age of 4 - 5 years,<sup>4</sup> and resulted in intra-oral swelling and dysphagia, the expected presentation in an adult. Also, there was no evidence of tuberculosis of the spine.

The high mortality rate associated with retropharyngeal abscesses is due to its association with airway obstruction, mediastinitis, aspiration pneumonia, epidural abscess, jugular venous thrombosis, necrotising fasciitis, sepsis and erosion into the carotid artery.<sup>5</sup> Clinical diagnosis of retropharyngeal abscess can be difficult, as the symptoms are variable and nonspecific. Signs of infection may be lacking in certain settings of immune suppression, such as diabetes. A plain lateral radiograph is very specific when it shows air in the retropharyngeal space. The diagnosis of retropharyngeal abscess or cellulitis is suggested when the retropharyngeal space at the level of C2 is twice the diameter of the contiguous vertebrae. Contrast-enhanced CT helps in differentiating an abscess from cellulitis and in ascertaining the extent of the disease. Central hypodensity with a surrounding thick rim of enhancement is most suggestive of an abscess. A chest radiograph is also useful in screening for complications such as mediastinitis, pneumonia and pleural effusion.

Surgical drainage is the cornerstone of the management of retropharyngeal abscess, and it should be done under the cover of antibiotics and antituberculosis treatment. If signs of airway compromise are present, the airway should be protected by tracheostomy or intubation before drainage of the abscess. It is safe to drain a retropharyngeal abscess transorally or by an external route.<sup>6</sup> We treated our patient in this case by transoral aspiration of the pus along with antibiotics and conventional antituberculosis therapy.

Needle aspiration has several advantages. It may be repeated if required, and can be used after intubation to relieve pressure from the abscess and upper airway obstruction. It also saves time if a spinal surgery facility is not immediately available. Furthermore, needle aspiration may be used to exclude other differential diagnoses such as a malignant tumour presenting clinico-radiologically as a

prevertebral abscess. It therefore gives the attending medical team time to use their judgement in order to lower the risks involved in anaesthesia and surgery. Surgery may be avoided altogether in selected cases, as massive cold abscesses have been reported to have disappeared on medical treatment alone.<sup>7</sup> In cases where pus cannot be successfully aspirated, surgical drainage may be more appropriate.

## Conclusion

Retropharyngeal abscesses are rare in adults and constitute a serious emergency. A possibility of cold abscess should be borne in mind when the infection does not respond to antimicrobial treatment and the clinical and radiological features suggest tuberculosis. Management is based on antibiotics and drainage along with antituberculosis drugs. Guided needle aspiration is a viable alternative treatment to surgical drainage.

## REFERENCES

1. Lafitte F, Martin-Duverneuil N, Brunet E, et al. Rhinopharynx et espaces profonds de la face: anatomie et applications à la pathologie. *J Neuroradiol* 1997;24(2):98-107.
2. Melchor Diaz MA, Domingo CC, Monge JR, Marion EJ, Ontanon MM. Tuberculous retropharyngeal abscess in an HIV patient. Report of a case. *Acta Otorrinolaringol Esp* 1993;44(6):467-470.
3. Fernandez-Ponjoan E. Practical considerations from the study of one thousand patients with tuberculosis of the upper respiratory tract. *Vida Nueva* 1943;51:146-154.
4. Marques PM, Spratley JE, Leal LM, Cardoso E, Santos M. Parapharyngeal abscess in children: five year retrospective study. *Braz J Otorhinolaryngol* 2009;75(6):826-830.
5. Herzon FS, Martin AD. Medical and surgical treatment of peritonsillar, retropharyngeal, and parapharyngeal abscesses. *Current Infectious Disease Reports* 2006;8(3):196-202.
6. Raj TB, Zarod AP. Acute non-tuberculous retropharyngeal abscess in adults: Case reports of three patients. *J Laryngol Otol* 1985;99(12):1297-1300.
7. Unal O, Kayan M, Akpınar F, Cankaya H, Akdeniz N. MRI demonstration of cervical spondylodiscitis and distal full-length bilateral paraspinal cold abscesses successfully treated by drug regimen only. *Skeletal Radiol* 2004;33:741-743.