

Bilharzia of the breast masquerading as a breast skin papilloma in a pregnant woman

To the Editor: A 21-year-old woman from Khayelitsha, Western Cape, presented with a 3 cm diameter papillomatous growth lateral to her left nipple with satellite lesions around the areola. She was 25 weeks pregnant and was concerned that the mass would interfere with breastfeeding. She was otherwise well. The papilloma was excised, and histological examination showed an exophytic papillary lesion with numerous viable *Schistosoma haematobium* ova (Fig 1.). There was a conspicuous surrounding mixed inflammatory reaction as well as extensive fibrosis, but no evidence of malignancy.

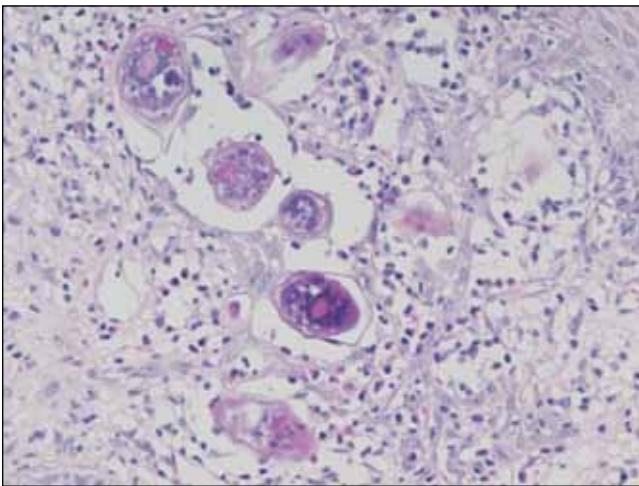


Fig. 1. Histological section showing viable *Schistosoma haematobium* ova.

A full travel history was later taken. The patient had been resident in Cape Town since 2006, before which she had lived in the rural Eastern Cape. Since 2006 she had had recurrent painless haematuria; viable *S. haematobium* was observed in her urine. She was treated with praziquantel.

Schistosoma ova have been described at numerous sites, including the urinary bladder, bowel, liver, eye, skin, cervix, fallopian tubes, ovaries and endometrium,¹⁻⁵ the most common site being the bladder.⁶ The breast is a rare location. The anastomosis between the pelvic venous plexus and subcutaneous veins explains the not infrequent occurrence of ova in the skin overlying the genito-rectal area.⁶ The explanation of how the ova end up in the breast is more complex, for which there are several theories. One is that adult flukes travel against the venous bloodstream to distant sites, where they deposit their eggs in venules. This explains why ectopic ova are clustered rather than widespread.⁶ Another theory is that adult flukes or eggs reach ectopic sites via the vertebral venous system, especially when intra-abdominal pressure is raised by coughing or straining.²

This is only the 10th reported case⁷ of bilharzia of the breast. The first was described by Nkanza in 1989 in a 24-year-old Zimbabwean with a painless left breast lump that had been present for 3 years. Microscopic examination showed a fibro-adenoma that contained many *S. haematobium* ova.⁸

All the patients previously described were from endemic areas. In each case, parasites co-existed in the urine or colon.⁷ In 6 cases, breast calcifications led to diagnosis; these calcifications were of malignant appearance (ACR type 4 or 5) and justified biopsy to exclude cancer.^{9,10} Four of the patients with calcifications had infestation with *S. japonicum* and lived in the Philippines.⁷

To the best of our knowledge, this is the first case to present as an exophytic areolar skin lesion.

C. E. Price

Department of Plastic and Reconstructive Surgery
Groote Schuur Hospital and
University of Cape Town

E. Coetzee

Department of General Surgery
Groote Schuur Hospital and
University of Cape Town

M. Otto

Department of Anatomical Pathology
Groote Schuur Hospital and
University of Cape Town

1. Edington GM, Nwabebo I, Junaid TA. The pathology of schistosomiasis in Ibadan, Nigeria, with special reference to the appendix, brain, pancreas and genital organs. *Trans R Soc Trop Med Hyg* 1975;69:153-162.
2. Mhaka RJ, Mushaike R, Chikolwa NC, Rabatseta NT. Unusual manifestations of schistosomiasis: case reports with review of the literature. *Cent Afr J Med* 1998;4:78.
3. Euderink F, Greyseels B, Van Kampen WJ, DeRegt J. Haematobium schistosomiasis presenting in the Netherlands as skin disease. *Am J Dermatopathol* 1994;16:434-438.
4. Lopez de Farira J. Pulmonary arteriovenous fistula and arterial distribution of eggs of *Schistosoma mansoni*. *Am J Trop Med Hyg* 1956;5:860-862.
5. Pitella JEH, Orifice F. Schistosomal choroiditis II. Report of first case. *Br J Ophthalmol* 1985;69:300-302.
6. Makunike RT, Muronda C. Breast schistosomiasis: a case report. *Histopathology* 2002;41:175-176.
7. Ducarme G, Seine N, Poulet B, Jeantils V, Uzan M. Breast: A rare localization of schistosomiasis. *Eur J Obstet Gynaecol Reprod Biol* 2007;133:247-253.
8. Nkanza NK. Schistosomal ova in a female breast. *Trop Geogr Med* 1989;41:365-367.
9. Lima CA, Cavalcanti AC, Lima MM, Piva N. Pseudoneoplastic lesion of the breast caused by *Schistosoma mansoni*. *Rev Soc Bras Med Trop* 2004;37:63-64.
10. Escobar PF, Patrick RJ, Sebek B, Procop G, Rice J, Crowe JP. Schistosomiasis presenting with microcalcifications on mammography. *Breast J* 2005;11:489-490.