

Solid pseudopapillary epithelial neoplasm – a rare but curable pancreatic tumour in young women

M. FROST, M.D.

Departments of Surgery, University of Cape Town and Oregon Health and Science University, Portland, Oregon, USA

J. E. J. KRIGE, M.B. CH.B., M.SC., F.R.C.S. (ED.), F.A.C.S., F.C.S. (S.A.)

P. C. BORNMAN, M.B. CH.B., M.MED., F.R.C.S. (ED.), F.R.C.S. (GLASG.), F.C.S. (S.A.)

Department of Surgery, University of Cape Town, and Surgical Gastroenterology Unit, Groote Schuur Hospital, Cape Town

E. PANIERI, M.B. CH.B., F.C.S. (S.A.)

Department of Surgery, University of Cape Town

S. J. BENINGFIELD, M.B. CH.B., F.FRAD. (S.A.)

Department of Radiology, University of Cape Town

H. WAINWRIGHT, M.B. CH.B., F.F.PATH. (S.A.)

Department of Anatomical Pathology, University of Cape Town

Summary

Background. Solid pseudopapillary epithelial neoplasms (SPENs) of the pancreas are rare but curable tumours that have a low-grade malignant potential and occur almost exclusively in young women, with an excellent prognosis after complete resection. This study examines the clinicopathological characteristics of these tumours and evaluates the role of surgery in relation to their size and location.

Study design. We reviewed the pre-, intra- and postoperative data on 21 patients with SPENs who underwent resection during a 30-year period. Data including demographic information, presenting symptoms and signs, extent of operation, histology, tumour markers and postoperative complications were evaluated to establish the optimal surgical management.

Results. All 21 tumours occurred in women (mean age 24.6 years, range 13 - 51 years). Sixteen patients presented with nonspecific abdominal complaints and a palpable abdominal mass, in 1 patient the tumour was found during emergency laparotomy for a complicated ovarian cyst, 1 patient presented with severe abdominal pain and shock due to a ruptured tumour, and in 3 patients the tumour was detected incidentally during imaging. The correct pre-operative diagnosis of SPEN was made in 10 patients. Incorrect preoperative diagnoses included hydatid cyst (3 patients), mesenteric cyst (2), pancreatic cystadenoma (2), ovarian cysts (1), islet cell tumour of the pancreas (1), and cavernous haemangioma of the liver (1). The mean diameter of the tumours was 12.5 cm (range 8 - 20 cm), and they occurred in the head (8), neck (5), body (2), and tail (6) of the pancreas. All SPENs were resected. Five patients had a pylorus-preserving pancreaticoduodenectomy, 4 a

central pancreatectomy with distal pancreaticogastrostomy, 8 a distal pancreatectomy, 3 a local resection and one a total pancreatectomy and portal vein graft. In 1 patient, 2 liver metastases were resected in addition to the pancreatic primary tumour. The patient who presented in shock with tumour rupture and bleeding into the lesser sac later died of multiple organ failure after successful resection. Postoperative complications included a stricture at the hepaticojejunostomy after pancreaticoduodenectomy, which resolved after stenting, and a pancreatic duct fistula after local tumour resection, which required a distal pancreatectomy. Other complications were bleeding (2 patients) requiring re-operation and intra-abdominal fluid collections requiring percutaneous drainage (3) or operation (1). Mean postoperative hospital stay was 16 days (range 6 - 40 days). Twenty patients are alive and well without recurrence, including the patient with metastases, with a mean follow-up of 6.6 years (range 6 months - 15 years).

Conclusions. This study demonstrated that SPENs of the pancreas are uncommon, but should be considered in the differential diagnosis of a cystic mass of the pancreas in a young woman. Despite the indolent biological behaviour of SPENs, most patients required major pancreatic resection. Surgery is curative regardless of the size or location of the tumour. Metastases are rare, as is recurrence after complete surgical resection.

Solid pseudopapillary epithelial neoplasms (SPENs) account for less than 10% of cystic pancreatic tumours and are usually readily distinguishable from other cystic tumours of the pancreas by their unusual and distinctive clinicopathological and imaging features and unique biological behaviour.¹⁻⁴ SPENs occur almost

exclusively in young women of childbearing age, are often palpable on presentation with minimal associated signs or symptoms, and have a low malignant potential with a favourable prognosis after complete resection.⁵

SPENs were first described in 1959 and initially named Frantz or Hamoudi tumours after the original authors. Their typical gross and histological features include cystic, solid and pseudopapillary components, which led to a variety of other names including solid cystic tumour, papillary cystic tumour, papillary epithelial neoplasia, solid and papillary epithelial neoplasia, papillary epithelial tumour, solid and papillary tumour, solid-cystic papillary epithelial neoplasm, benign or malignant papillary tumour of the pancreas, and adenocarcinoma of the pancreas in childhood.^{1,6-8} In order to resolve the confusing nomenclature, the World Health Organization (WHO) in 1996 gave the official name of solid pseudopapillary tumours, although the earlier names may still be encountered in the literature.⁶ The WHO defines malignant pancreatic SPENs as those exhibiting angio-invasion, perineural invasion, or deep invasion of surrounding pancreatic parenchyma.⁶

Because SPENs are uncommon, accurate information on optimal management is scant. It is important to recognise these tumours and treat them appropriately because they have a high rate of cure after resection when confined to the pancreas and seldom metastasise due to their low-grade malignant potential.^{1,9} Most of the reported data on SPENs come from case reports and small series, including a previous report of 14 patients from our unit published more than a decade ago.¹⁰ The current study examines the clinicopathological characteristics of a larger number of cases and specifically evaluates the role and extent of surgery in relation to tumour size and location.

Patients and methods

Patient selection

In this single-centre retrospective cohort study, the prospective pancreatic resection database in the Surgical Gastroenterology Unit at Groote Schuur Hospital was used to identify patients who underwent surgery for pancreatic cystic neoplasms between 1979 and 2010. Twenty-one patients had undergone pancreatic resection for SPEN. Demographic, clinical, imaging and pathological data and the findings on special investigations were analysed. Pre-operative data included age at presentation, duration of presenting symptoms, suspected diagnosis and special investigations. Pathological and operative data included location and size of the tumour, type of operation and extent of resection, presence of metastases and postoperative complications. All patients were followed up at the Surgical Gastroenterology Clinic.

A peri-operative surgical complication was defined as one occurring within 30 days of the initial operation. The modified Clavien-Dindo classification¹¹ of surgical complications (grades 1 - 5) was used to score surgical outcomes. A pancreatic fistula was defined using the recommendations of the International Study Group on Pancreatic Fistula.¹²

Results

All 21 patients were female, with a mean age of 24.6 years (range 13 - 51 years). In 3 patients the tumour was asymptomatic and was detected during a medical examination for unrelated complaints. In 1 patient the tumour was found during emergency laparotomy

for a complicated ovarian cyst, 1 patient presented with severe abdominal pain, and the remaining 16 patients presented with nonspecific abdominal complaints and a palpable abdominal mass.

Ultrasonography or computed tomography (CT) scan showed an abdominal mass in 20 patients (Fig. 1). In 12 patients the mass had both solid and cystic components, in 5 the mass was predominantly solid, and in 4 it was mostly cystic. One patient was noted to have fine spicular calcifications within the cystic tumour wall. Pre-operative imaging was not done in 1 patient who presented in shock with an acute abdomen, and the diagnosis was made at laparotomy. Three patients also had endoscopic retrograde cholangiopancreatography (ERCP), 4 visceral angiography, 2 fine-needle aspiration biopsy, 1 an intravenous pyelogram and 1 magnetic resonance imaging, all to assist with pre-operative diagnosis or further delineate associated structures. The correct pre-operative diagnosis of papillary cystic neoplasm was made in 10 patients. Incorrect pre-operative diagnoses included hydatid cyst (3 patients), mesenteric cyst (2), pancreatic cystadenoma (2), ovarian cysts (1), islet cell tumour of the pancreas (1), and cavernous haemangioma of the liver (1). In 2 patients the lesion was incorrectly diagnosed elsewhere as a pseudocyst at the initial laparotomy. Biopsy and histology of the cyst wall revealed the true nature of the lesion.

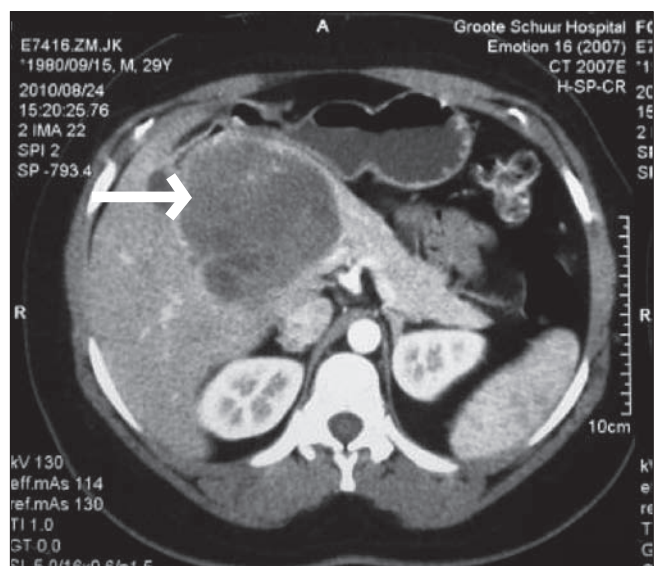


Fig. 1. Computed tomogram showing the heterogeneous densities in a SPEN (arrow) involving the head of the pancreas.

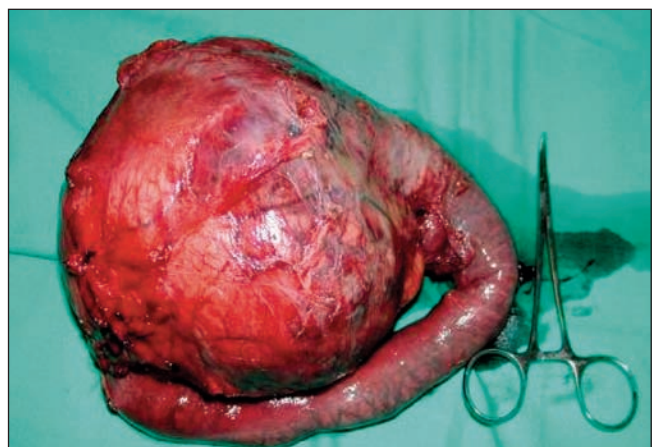

Fig. 2. A pancreaticoduodenectomy specimen of a resected SPEN.

Tumour diameter ranged from 6 to 20 cm (mean 12 cm), and the tumours were located in the uncinete process (1), head (7), neck (5), body (2), and tail (6) of the pancreas (Table I). All 21 patients had complete resection of the primary tumour (Fig. 2). Of the 13 tumours arising in the proximal pancreas from the uncinete process, head or neck of the pancreas, 5 necessitated a pylorus-preserving pancreaticoduodenectomy (PPPD). One of the patients undergoing PPPD developed a postoperative bile leak which required percutaneous ultrasound-guided drainage and resolved,

and another had an anastomotic leak with a subsequent stricture at the hepaticojejunostomy that required temporary transhepatic biliary stenting. Twelve years after stent removal no symptoms have recurred. One patient bled postoperatively from a superior mesenteric artery uncinete branch and required re-laparotomy for haemostasis. Two patients developed steatorrhoea after surgery that required pancreatic enzyme supplementation. One patient had a total pancreatectomy, splenectomy and portal vein resection with an interposition Dacron graft in order to resect the tumour.

TABLE I. PATIENT CHARACTERISTICS INCLUDING AGE, TUMOUR LOCATION, SIZE, OPERATION AND POSTOPERATIVE COMPLICATIONS

Patient	Age (yrs)	Site	Size (cm)	Operation performed	Postoperative complications
1	20	Head	20	PPPD	Steatorrhoea
2	51	Body	13.5	Distal pancreatectomy, splenectomy	Pancreatic leak requiring percutaneous drainage, DM
3	18	Head	7.5	PPPD	Steatorrhoea
4	29	Head	7	Local excision	None
5	17	Uncinate	9	Local excision	None
6	21	Head	12	PPPD	Bile leak requiring percutaneous drainage
7	28	Tail	7	Distal pancreatectomy, splenectomy	None
8	44	Tail	7.5	Distal pancreatectomy, splenectomy	Pancreatic leak requiring open evacuation, DM
9	17	Body	20	Distal pancreatectomy, splenectomy, segmental resection of liver metastases	None
10	21	Tail	20	Distal pancreatectomy, splenectomy	None
11	25	Neck	16	Local excision	Pancreatic fistula requiring distal pancreatectomy, DM
12	17	Head	7	PPPD	Bleeding requiring re-operation
13	34	Tail	8	Distal pancreatectomy, splenectomy	Clostridium difficile requiring colectomy, MSOF, death
14	14	Neck	15	Central pancreatectomy, partial gastrectomy	Bile leak requiring percutaneous drainage
15	15	Neck	15	Central pancreatectomy	None
16	36	Neck	8	Central pancreatectomy	None
17	21	Neck	6	Central pancreatectomy	Bile leak, conservative management
18	13	Head	11	Total pancreatectomy, splenectomy, portal vein resection with interposition Dacron graft	Thrombosis of Dacron graft, oesophageal varices, DM
19	51	Tail	7.5	Distal pancreatectomy, splenectomy	Bleeding requiring re-operation, post-splenectomy thrombocytosis
20	23	Tail	14	Distal pancreatectomy, splenectomy	None
21	29	Head	20	PPPD	None

PPPD = pylorus-preserving pancreatectomy; DM = diabetes mellitus; MSOF = multisystem organ failure.

She subsequently developed thrombosis of the Dacron graft and portal hypertension with oesophageal varices, which were treated by endoscopic band ligation.

Four patients underwent a central pancreatectomy and distal pancreaticogastrostomy incorporating the residual pancreatic body and tail. In 1 of these patients, tumour adherence to the posterior wall of the stomach at the site of a primary cystgastrostomy inappropriately performed at another institution necessitated resection of the gastric antrum and proximal 3 cm of the duodenum. A Billroth I reconstruction was performed, with re-implantation of the pancreatic tail into the posterior stomach. Her postoperative course was complicated by a bile leak that was treated by percutaneous catheter drainage.

In 3 patients the tumour was removed using local excision. Two of these tumours were in the head and 1 in the neck of the pancreas; the latter patient developed a persistent pancreatic fistula that ultimately required a distal pancreatectomy.

Eight patients with tumours in the pancreatic body or tail underwent distal pancreatectomy and splenectomy. Metastases were present in 1 patient, and two liver metastases were excised by wedge resection. The first metastasis was resected during the primary tumour removal, and the second 3 months later. This patient also received postoperative chemotherapy and radiation (Table I).

One patient died. She presented in shock with severe abdominal pain and at operation a ruptured necrotic tumour originating in the tail of the pancreas was found. A distal pancreatectomy was performed. The postoperative course was complicated by adult respiratory distress syndrome and pseudomembranous colitis. She died of multiple organ failure 16 days after surgery.

Postoperative hospital stay ranged from 6 to 40 days (mean 16.4 days). The Dindo-Clavien grades for the 12 patients who had postoperative complications were grade 1 ($N=1$), grade 2 ($N=3$), grade 3 ($N=7$) and grade 5 ($N=1$). Twenty patients are alive and well without recurrence with a mean follow-up of 6.6 years (range 6 months - 15 years).

The histological diagnosis of SPEN was confirmed in all 21 patients. The tumours were large (range 6 - 20 cm), circumscribed with a thick fibrous capsule in 16 patients, and had macroscopically detectable solid and cystic components (Fig. 3) as well as areas of haemorrhage and necrosis in 12 patients. The microscopic appearance was remarkably uniform between patients, but there was considerable histological variation within a given tumour. The solid tumour areas showed sheets and cords of cells arranged around delicate fibrovascular septa, but in discohesive areas the creation of spaces between cells resulted in a pseudopapillary pattern (Fig. 4). Trabecular patterns with hyalinised collagen surrounding blood vessels were common. Most tumours showed evidence of marked degenerative changes with cyst formation, haemorrhage and foamy macrophages. Severe degrees of nuclear atypia and pleomorphism were uncommon and mitotic figures were rare. Although the capsule was often incomplete, overt capsular invasion was uncommon and vascular invasion by tumour cells was not seen. Of the 17 tumours that had immunohistochemical staining completed, 10 were positive for neuron-specific enolase, 7 for vimentin, 7 for alpha-1-antitrypsin, and 5 for progesterone receptors.

Discussion

Cystic neoplasms represent less than 10% of all pancreatic tumours and encompass a wide spectrum of benign, borderline and malignant neoplasms.⁹ Although serous cystadenomas (35%), mucinous cystic cystadenomas (25%) and intraductal papillary mucinous neoplasms (15%) are the cystic pancreatic tumours most commonly encountered in clinical practice, this category also includes rare SPENs of the pancreas.⁹ Although previous studies indicate that SPENs account for only 1 - 2% of all pancreatic tumours, a greater awareness of the tumour has led to increased detection and therefore higher recent recorded incidence rates.^{7,9,13,14} The importance of SPENs lies in the fact that they are low-grade malignant but eminently resectable tumours that have an excellent prognosis after complete resection.¹² Our study is consistent with the literature in that SPENs are found almost exclusively in young women. In a review of 718 published cases, more than 90% were female; the average age was 22 years, with 85% of patients being under 30 years old.^{1,15}

While most patients present with nonspecific abdominal complaints and have a palpable abdominal mass on examination,^{1,14,16} some may present with gastro-intestinal obstruction, jaundice, or pancreatitis,^{1,17} or, as in our series, with an acute abdomen due to tumour rupture.² The differential diagnosis of a partially solid and cystic mass arising from the pancreas in a young woman should include complicated pseudocysts, pancreatic endocrine tumours, serous cystadenomas, mucinous cystic tumours, islet cell tumours and acinar cell carcinomas.^{14,18}

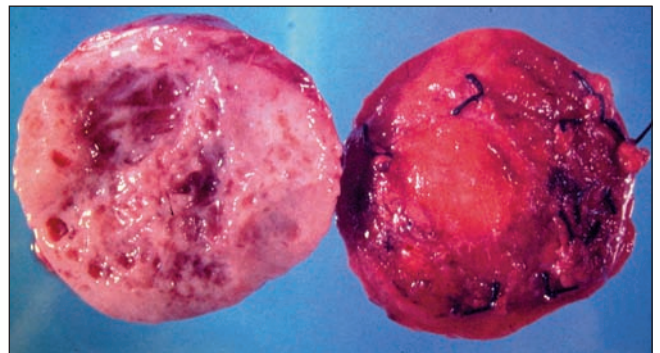


Fig. 3. The cut surface of a resected SPEN showing a well-encapsulated mass with cystic and solid components.

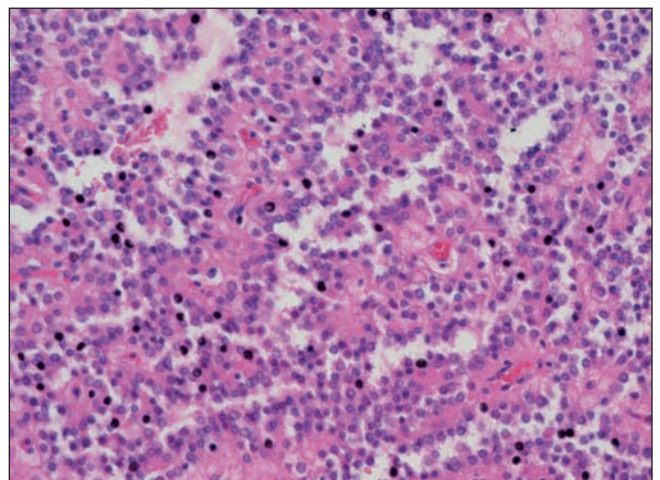


Fig. 4. Haematoxylin and eosin-stained micrograph ($\times 20$) showing a SPEN with typical small uniform cells arranged in a pseudopapillary pattern.

If imaging does not clearly show the origin of the mass, the differential diagnosis widens to include a mesenteric cyst, hydatid cyst, hepatocellular carcinoma or ovarian cyst. Twelve of the patients in our series had a cystic mass arising in or apparently adjacent to the pancreas, and half of all patients were correctly identified pre-operatively as having a SPEN. Two patients underwent an FNA for assistance with diagnosis. Two of the patients in this series were originally misdiagnosed elsewhere as having pseudocysts and underwent cystogastrostomy. Biopsy of the cyst wall demonstrated the unusual and distinctive papillary architecture of the tumour and provided the correct diagnosis and referral to our hospital. Another patient was incorrectly diagnosed as having a hydatid cyst before frozen section of the cyst wall confirmed a SPEN, and the tumour was subsequently completely excised.

Radiological studies are crucial in the pre-operative evaluation of these tumours and, with increasing use of abdominal imaging, SPENs are now also increasingly diagnosed incidentally.^{5,15,16,19} Abdominal radiographs may demonstrate displacement of the adjacent viscera by an extrinsic mass.^{20,21} The appearance of SPEN on ultrasound is of a heterogeneous, encapsulated, hypo-echoic solid or mixed echogenic mass, often with cystic characteristics and areas of calcification. CT typically demonstrates a well-defined, mixed solid and cystic mass which can range from mostly solid to mostly cystic.^{1,14,21,22} Typically the degree of cystic degeneration is greater in larger tumours, while small SPENs may appear entirely solid. Peripheral arterial enhancement of the tumour may occur with solid components of SPEN typically enhancing similar to pancreatic parenchyma on arterial and venous phases, in contrast to the hypo-attenuation of an adenocarcinoma or increased enhancement of neuro-endocrine tumours on the arterial phase on CT.²³ Calcification within the large mass is seldom encountered. When present, however, calcification is usually peripheral and curvilinear, compared with the sunburst pattern described in microcystic adenomas.²⁴ The main features on magnetic resonance imaging are a well-demarcated rim enclosing a multiloculated mass and the presence of internal structures consistent with papillary tumour nodules plus occasional features of haemorrhage.²⁵

The pathological features of SPEN are distinctive, with a mixture of solid, cystic and pseudopapillary patterns in varying proportions.² Grossly, these tumours appear well encapsulated and well demarcated from normal pancreatic parenchyma, with spongy areas of haemorrhage visible on the cut surface alternating with both solid and cystic areas of degeneration, an uncommon feature in benign, slowly growing tumours.²⁶ Some authors speculate that the degenerative central necrosis results from the tumour outstripping its blood supply within a non-expandable fibrotic capsule, but the extent of necrosis has not always been proportional to the size of the tumour.² The hallmark histological pattern of this tumour is a solid and papillary epithelial pattern occurring in a pancreatic neoplasm.²⁷ Microscopically the growth pattern of the tumour is remarkably uniform. The solid areas are composed of sheets and cords of uniform and polygonal epithelioid cells with grooved ovoid nuclei arranged around delicate fibrovascular septa. Degenerative changes result in varying proportions of solid, haemorrhagic cystic or pseudopapillary structures.²⁸ The cystic spaces orient around the vascular stalks in a characteristic rosette and pseudopapillary pattern, giving the tumour its name.¹⁶

Immunohistochemical staining is useful in distinguishing SPENs from other pancreatic neoplasms.¹ SPEN is typically positive for vimentin, α -1-antitrypsin, α -1- antichymotrypsin, neuron-specific enolase and progesterone receptors,²⁸ which is consistent with the findings in the current study.^{1,26} SPEN cells may also reveal focal immunoreactivity for cytokeratin and synaptophysin, and the presence of progesterone receptors, and may express galectin-3, all of which are useful in differentiating SPEN from endocrine pancreatic tumours.^{1,26} Studies of the molecular pathogenesis of SPEN show universal aberrant regulation of the beta-catenin pathway with abnormal nuclear beta-catenin staining. Negative keratin and chromogranin staining with a positive beta-catenin mutation eliminate acinar cell carcinoma, islet cell carcinoma and ductal adenocarcinoma from the diagnosis.^{16,29} While the origin of SPENs is debatable and the immunohistochemical staining pattern does not reveal a specific origin, these tumours are commonly classified with epithelial neoplasms, but the lack of cytokeratin expression indicates that SPENs cannot be purely epithelial.^{1,7} There is general agreement that SPENs are predominantly of exocrine origin due to their expression of alpha-1-antitrypsin and neuron-specific enolase,¹ but because these tumours most often occur in young women and the presence of progesterone receptors is typical, a neuro-endocrine origin has also been suggested.⁶ In addition, the tumours often express neuro-endocrine markers such as CD10 and CD56, but not chromogranin.^{1,30} The tumours also lack oestrogen receptors.¹⁶ Since the tumours can express epithelial, mesenchymal, exocrine and endocrine features, a stem cell origin has been proposed, but the cytological features and low proliferative activity have not substantiated this hypothesis.^{1,7}

Surgery provides the only curative treatment for SPEN.¹ In this study, the large size of the tumours did not preclude resection and all patients underwent resection. Surgical management has been tailored to the slow-growing, non-invasive nature of the tumour, and the operations performed in this series mirror those reported in the literature.¹⁰ Standard therapy involves complete removal of the tumour, involved pancreas, and any extension into adjacent organs.^{1,20,31,32} Local invasion, recurrence, or limited metastases are not contraindications to resection. Portal vein resection has been advised when there is evidence of tumour invasion.³³ For tumour involvement localised to the head or uncinate process of the pancreas, a pylorus-preserving pancreaticoduodenectomy is preferred unless there is a small tumour distant from the pancreatic duct that can be removed safely by enucleation.^{5,15,16,18,19} In this study SPENs involving the neck or body of the pancreas were resected by central pancreatectomy and re-implantation of the pancreatic remnant as a distal pancreaticojejunostomy or pancreaticogastrostomy,^{5,15} with the theoretical benefit of preserving pancreatic parenchyma and spleen. Simple excision without formal pancreatic resection, when technically feasible, is a viable alternative to more extensive surgery, and has not been associated with recurrence in our series. The lesser procedure avoids the need for a pancreatoduodenectomy, which may be technically demanding when the bile duct is small and the pancreatic remnant is soft with a small duct.

Lymphadenectomy is not required as lymph node metastases are rare, having been reported in under 2% of cases.^{2,13,34} Metastases or invasion of nearby structures occur in fewer than 20% of patients. Of these 30% have metastatic disease of the liver, 27% have

invasion of the portal vein, and another 17% have splenic invasion.¹ Synchronous resection of liver metastases is advised, and invasion of the portal vein (as occurred in 1 of our patients) or other nearby organs does not preclude resection. In these instances, *en bloc* resection should be the goal.^{1,14,35} Sperti *et al.*³⁶ reported 17 patients who underwent vascular resection and reconstruction with no deaths. In our study, an infiltrated portal vein was reconstructed with a Dacron graft after *en bloc* resection and the patient remains free of recurrence 2 years later.

Reported peri-operative morbidity rates vary from zero to 62%.¹⁴ The most common complication after surgery for SPEN is a pancreatic fistula due to small duct size and soft pancreatic parenchyma.¹⁴ Pancreatic duct obstruction in SPEN is uncommon, so soft gland texture and a small duct are universal findings.³⁷ In this study, one-third of patients required intervention due to complications arising from the surgery. There was no association between the size or location of the tumour, the operation performed, and the occurrence of a complication in our study. Although morbidity rates can be high, the prognosis after complete resection is excellent. Over 95% of patients with local pancreatic disease are alive at 5 years, and patients with resected metastases often survive beyond 5 years.¹ The rarity of the tumour and its indolent nature make it difficult to identify features predicting aggressiveness. Greater age and male gender appear to be associated with more aggressive tumours.³⁸ A review of 718 patients showed a recurrence rate of 6.6%.^{1,14-16,18} Perineural or vascular invasion and an increased mitotic rate are associated with both metastatic disease and recurrence.^{13,16,39} The role of adjuvant therapy has not yet been clearly defined. Some patients with irresectable, metastatic or recurrent disease have been treated with combinations of chemotherapy and radiation, but so far there have only been case reports or small series that describe the efficacy of these treatments.^{1,14}

In conclusion, this study demonstrated that solid pseudopapillary epithelial neoplasms of the pancreas are uncommon, but should be considered in the differential diagnosis of a large solid or complex cystic mass involving the pancreas in a young woman. Despite the indolent biological behaviour of SPENs, most patients required a major pancreatic resection. Excision is almost always curative regardless of the size or location of the tumour. Metastases are rare, as is recurrence after complete surgical resection. We propose that on the basis of the low recurrence rate and prolonged survival after complete local resection, aggressive attempts at complete resection are justified, even when metastases are present.

REFERENCES

- Papavramidis T, Papavramidis S. Solid pseudopapillary tumors of the pancreas: review of 718 patients reported in English literature. *J Am Coll Surg* 2005;200:965-972.
- Mao C, Guvendi M, Domenico DR, et al. Papillary cystic and solid tumors of the pancreas: a pancreatic embryonic tumor? Studies of three cases and cumulative review of the world's literature. *Surgery* 1995;11:821-828.
- Reddy S, Cameron JL, Scudiere J, et al. Surgical management of solid-pseudopapillary neoplasms of the pancreas (Franz or Hamoudi tumors): a large single-institutional series. *J Am Coll Surg* 2009;208:950-959.
- Butte JM, Brennan MF, Gonen M, et al. Solid pseudopapillary tumors of the pancreas. Clinical features, surgical outcomes, and long-term survival in 45 consecutive patients from a single center. *J Gastrointest Surg* 2011;15:350-357.
- De Castro SM, Singhal D, Aronson DC, et al. Management of solid-pseudopapillary neoplasms of the pancreas: a comparison with standard pancreatic neoplasms. *World J Surg* 2007;31:1129-1134.
- Kloppel G, Solcia E, Longnecker DS, Capella C, Sobin LH. Histological typing of tumors of the exocrine pancreas. In: World Health Organization International Histological Classification of Tumours. 2nd ed. Berlin: Springer, 1996:845/1.
- Santini D, Poli F, Lega S. Solid-papillary tumors of the pancreas: histopathology. *JOP* 2006;7:131-136.
- Uchimi K, Fujita N, Noda Y. Solid cystic tumor of the pancreas: report of six cases and a review of the Japanese literature. *J Gastroenterol* 2002;37:972-980.
- Brugge WR, Lauwers GY, Sahani D, Fernandez-del Castillo C, Warshaw AL. Cystic neoplasms of the pancreas. *N Eng J Med* 2004;351:1218-1226.
- Panieri E, Krige JE, Bornman PC, Graham SM, Terblanche J, Cruse JP. Operative management of papillary cystic neoplasms of the pancreas. *J Am Coll Surg* 1998;186:319-324.
- Dindo D, Demartines N, Clavien P-A. Classification of surgical complications. *Ann Surg* 2004;240:205-213.
- Bassi C, Dervenis C, Butturini G, et al.; International Study Group on Pancreatic Fistula Definition. Postoperative pancreatic fistula: an international study group (ISGPF) definition. *Surgery* 2005;138:8-13.
- Martin RC, Klimstra DS, Brennan MF, Conlon KC. Solid-pseudopapillary tumor of the pancreas: a surgical enigma? *Ann Surg Oncol* 2002;9:35-40.
- Romics L Jr, Oláh A, Belágyi T, Hajdú N, Gyurus P, Ruzsinkó V. Solid pseudopapillary neoplasm of the pancreas - proposed algorithms for diagnosis and surgical treatment. *Langenbecks Arch Surg* 2010;395:747-755.
- Machado MC, Machado MA, Bacchella T, Jukemura J, Almeida JL, Cunha JE. Solid pseudopapillary neoplasm of the pancreas: distinct patterns of onset, diagnosis, and prognosis for male versus female patients. *Surgery* 2008;143:29-34.
- Tipton SG, Smyrk TC, Sarr MG, Thompson GB. Malignant potential of solid pseudopapillary neoplasm of the pancreas. *Br J Surg* 2006;93:733-737.
- Madan AK, Weldon CB, Long WP, Johnson D, Raafat A. Solid and papillary epithelial neoplasm of the pancreas. *J Surg Oncol* 2004;85:193-198.
- Huang HL, Shih SC, Chang WH, Wang TE, Chen MJ, Chan YJ. Solid-pseudopapillary tumor of the pancreas: clinical experience and literature review. *World J Gastroenterol* 2005;11:1403-1409.
- Mortenson MM, Katz MH, Tamm EP, et al. Current diagnosis and management of unusual pancreatic tumors. *Am J Surg* 2008;196:100-113.
- Rustin RB, Broughan TA, Hermann RE, Grundfest-Broniatowski SE, Petras RE, Hart WR. Papillary cystic epithelial neoplasms of the pancreas. A clinical study of four cases. *Arch Surg* 1986;121:1073-1076.
- Yamaguchi K, Hirakata R, Kitamura K. Papillary cystic neoplasm of the pancreas: radiological and pathological characteristics in 11 cases. *Br J Surg* 1990;77:1000-1003.
- Buetow PC, Buck JL, Pantongrag-Brown L, Beck KG, Ros PR, Adair CF. Solid and papillary epithelial neoplasm of the pancreas: imaging-pathologic correlation on 56 cases. *Radiology* 1996;199:707-711.
- Reddy S, Wolfgang CL. Solid pseudopapillary neoplasms of the pancreas. *Adv Surg* 2009;43:269-282.
- Sheen IS, Chang-Chien CS, Wu CS. Solid and papillary neoplasm: a report of an unusual pattern of calcification. *Am J Gastroenterol* 1988;83:789-791.
- Kaloo AN, Nauta RJ, Benjamin SB. Solid and papillary epithelial neoplasm of the pancreas: clinical findings of a rare tumour. *J Clin Gastroenterol* 1990;12:325-328.
- Yu PF, Hu ZH, Wang XB, et al. Solid pseudopapillary tumor of the pancreas: a review of 553 cases in Chinese literature. *World J Gastroenterol* 2010;16:1209-1214.
- Zinner MJ. Solid and papillary neoplasms of the pancreas. *Surg Clin North Am* 1995;75:1017-1024.
- Kosmahl M, Seada L, Janig U, Harms D, Kloppel G. Solid-pseudopapillary tumor of the pancreas: its origin revisited. *Virchows Archive* 1999;436:473-480.
- Chakhachiro ZI, Zaatari G. Solid-pseudopapillary neoplasm: a pancreatic enigma. *Arch Pathol Lab Med* 2009;133:1989-1993.
- Notohara K, Hamazaki S, Tsukayama C, et al. Solid-pseudopapillary tumor of the pancreas: Immunohistochemical localization of neuroendocrine markers and CD10. *Am J Surg Pathol* 2000;24:1361-1371.
- Eason JD, Eason JH, George SM, et al. Solid and papillary epithelial neoplasm of the pancreas. *South Med J* 1991;84:247-249.
- Sanfey H, Mendelsohn G, Cameron JL. Solid and papillary neoplasm of the pancreas: a potentially curable surgical lesion. *Ann Surg* 1983;197:272-275.
- Dales RL, Garcia JC, Davies RS. Papillary cystic carcinoma of the pancreas. *J Surg Oncol* 1983;22:115-117.
- Klimstra DS, Wenig BM, Heffess CS. Solid-pseudopapillary tumor of the pancreas: a typically cystic carcinoma of low malignant potential. *Semin Diagn Pathol* 2000;17:66-80.
- Jeng LBB, Chen MF, Tang RP. Solid and papillary neoplasm of the pancreas: emphasis on surgical treatment. *Arch Surg* 1993;128:433-436.
- Sperti C, Berselli M, Pasquali C, Pastorelli D, Pedrazzoli S. Aggressive behaviour of solid-pseudopapillary tumor of the pancreas in adults: a case report and review of the literature. *World J Gastroenterol* 2008;14:960-965.
- Matos JM, Grützmann R, Agaram NP, et al. Solid pseudopapillary neoplasms of the pancreas: a multi-institutional study of 21 patients. *J Surg Res* 2009;157:e137-142.
- Garatea R, Targarona J, Barrera L, Warshaw A, Fernandez del Castillo C. Solid pseudopapillary neoplasm of the pancreas: report of 31 resected cases and description of a paradoxical inverse relation between age and tumor size. *Pancreas* 2006;33:463.
- Tang LH, Aydin H, Brennan MF, Klimstra DS. Clinically aggressive solid pseudopapillary tumors of the pancreas: a report of two cases with components of undifferentiated carcinoma and a comparative clinicopathologic analysis of 34 conventional cases. *Am J Surg Pathol* 2005;29:512-519.