

# A comparison of laparoscopic-assisted (LAARP) and posterior sagittal (PSARP) anorectoplasty in the outcome of intermediate and high anorectal malformations

C. DE VOS, M.B. CH.B., D.M.O.

M. ARNOLD, M.B. CH.B., D.CH.

D. SIDLER, M.D. (BERNE), M. PHIL. (APPLIED ETHICS), F.C.S. (SA)

S. W. MOORE, M.B. CH.B., F.R.C.S. (ED.), M.D.

*Division of Paediatric Surgery, Stellenbosch University, Tygerberg, W Cape*

## Summary

**Introduction.** Laparoscopic-assisted anorectoplasty (LAARP) has gained popularity since its introduction in 2000. Further evidence is needed to compare its outcome with the gold standard of posterior sagittal anorectoplasty (PSARP).

**Method.** A retrospective review of patients presenting with anorectal malformation (ARM) in the period 2000 - 2009. Demographics, associated abnormalities, and operative and post-operative complications were assessed. The functional outcome in children older than 3 years was assessed, applying the Krickbeck scoring system and, where possible, by interviewing parents. Patients with cloacal abnormalities were excluded. Patients with a LAARP were compared with those managed by PSARP.

**Results.** Seventy-three patients with ARM were identified during the study period. Male to female ratio was 1.6:1. All 32 low ARMs (perineal and vestibular fistulae) were excluded. Thirty-nine had levator or supra-levator lesions. Twenty males presented with recto-bulbar, 3 with recto-prostatic, and 1 with a recto-vesical fistula; 2 had no fistula; and in 2 the data were insufficient to determine the level. Among the females, 6 had recto-vaginal fistulae, 4 had cloacas and 1 had an ARM without fistula. There were 3 syndromic ARMs (2 trisomy 21 and 1 Baller-Gerold syndrome). One neonate with a long-gap oesophageal atresia had a successful primary LAARP. Seventy-five per cent of all patients had VACTERL associations. Two early deaths after colostomy formation were related to a cardiac anomaly and an oesophageal atresia.

In both groups, mean age at anoplasty was 8 months. Twenty of the intermediate/high lesions were treated with LAARP, and 19 by PSARP.

There were slightly more complications in the LAARP group; intra-operative injury to the vas deferens and urethra occurred once each. Post-operatively, 2 port-site hernias and 1 case of pelvic sepsis occurred. A poorly sited colostomy caused difficulty in 2 patients. Two patients were converted to laparotomy: severe adhesions in one and a poorly sited stoma in another. Five patients required redo-anoplasty for mucosal prolapse, anal stenosis, incorrect placement of the anus, retraction of the rectum and an ischaemic rectal stricture. Complications in the PSARP group included 2 wound dehiscences, 1 anal stenosis, 3 mucosal prolapses, 1 recurrent fistula and 2 incorrect anal placements requiring redo surgery.

The Krickbeck questionnaire was used in 70% of PSARPs (mean age 5.9 years) and LAARPs (mean age 5.5 years) for a functional assessment. Both groups showed voluntary bowel movements in 14%. Soiling and overflow incontinence was a significant problem. Grade III constipation was less common in the LAARP (14%) than PSARP (21%) group. Four patients in the LAARP group were reliant on regular rectal washouts compared with 6 in the PSARP group.

**Conclusion.** Both LAARP and PSARP can successfully treat ARM but have specific associated problems.

Anorectal malformations (ARMs) affect about 1 in 5 000 live-born infants.<sup>1</sup> For those with high or intermediate defects (supra-levator or levator-level defects), colostomy in the newborn period is life-saving.<sup>2</sup> However, long-term quality of life after construction of a neo-anus and colostomy closure is still unsatisfactory.<sup>3,4</sup> In many cases, this can be attributed to complexity of the lesion, a high rate of associated malformations

(40 - 60%) and poor socio-economic environment.<sup>5</sup> Type of lesion, surgical management and quality of long-term follow-up play a major role.<sup>3</sup>

Advances in the management of ARM include the Wingspread initiative and the resulting standardisation of classification and evaluation.<sup>6</sup> The introduction of the posterior sagittal anorectoplasty (PSARP) by Pena in 1981<sup>7</sup> significantly improved

the understanding and visualisation of the muscle complex, allowing for precise anatomical approximation of the rectum and anus within the reconstructed anorectal canal.<sup>1</sup> The more recent 'Krickbeck' conference further clarified definitions and a standardised ARM classification as well as standardising the method of post-operative assessment.<sup>2</sup> Subsequently, Georgeson introduced the laparoscopic-assisted anorectoplasty (LAARP) in 2000, which involves less dissection and improved visualisation of the rectal fistula.<sup>8,9</sup>

The LAARP has gained popularity mainly in the management of prostatic or bladder-neck fistulae, that would otherwise require laparotomy.<sup>10,11</sup> Its role in the management of lower lesions remains controversial. There is a paucity of long-term follow-up data, and more evidence is needed to compare outcomes with the standard PSARP.<sup>12</sup>

## Aim

To assess the complications and long-term outcome of patients managed with intermediate or high anorectal malformations at Tygerberg Children's Hospital, comparing LAARP with PSARP.

## Methodology

A retrospective review (2000 - 2009) of patients with high/intermediate ARM was conducted. Demographics, associated anomalies, and operative and post-operative complications were documented. For patients older than 3 years, the long-term continence outcome (Krickbeck scoring system) was assessed by means of hospital records and parent interviews.<sup>2</sup>

The laparoscopic technique used is a modification of Georgeson's technique as described in 2000.<sup>7</sup> Small babies were placed transversely across the operating table with the buttocks at the edge of the table, their legs resting on an arm rest until the anoplasty was performed. We used a trans-cutaneous bladder-hoisting stitch to aid visualisation and did not formally close the recto-urethral fistula after it was cut. A urinary catheter was left

*in situ* for approximately 3 - 5 days. The rectum was not fixed to the sacrum.

## Results

Data for 73 patients treated for an ARM at Tygerberg Hospital were available for the study period. After exclusions, there were 20 and 19 patients in the LAARP and PSARP groups, respectively. Demographics, including sex, type of ARM, and age at pull-through, are shown in Table I and Fig. 1. Age at surgery was relatively late in both groups. One neonate with a long-gap oesophageal atresia had a successful primary LAARP. Seventy-five per cent of patients had a VACTERL association (Table II and Fig. 2). Two patients in the LAARP group were diagnosed with Down's syndrome, and 1 in the PSARP group with Baller-Gerold syndrome.

There were no anaesthetic complications. A single surgeon performed all LAARP procedures, but different surgeons carried out the PSARPs. Surgical complications are listed in Table III. Intra-operative LAARP-related complications were encountered in 5 patients and included 2 injuries to the urogenital organs and 2 port-site hernias. Postoperatively, complications included 1 pelvic abscess, 1 superficial wound infection, 3 anal strictures,

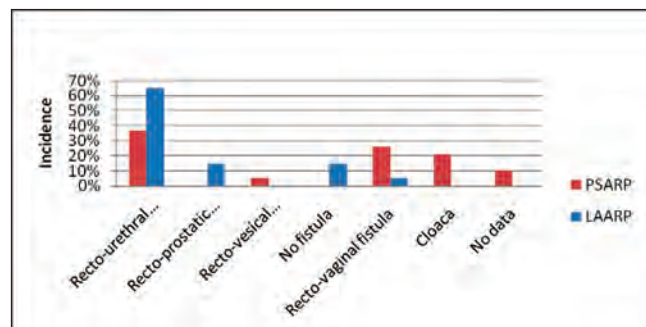


Fig. 1. Type of anorectal malformation.

TABLE I. DEMOGRAPHICS OF PSARP AND LAARP GROUPS

Demographics of PSARP and LAARP groups		PSARP		LAARP	
		N	%	N	%
<b>No. of patients (N)</b>		19	100	20	100
<b>Gender</b>	Male	10	53	18	90
	Female	9	47	2	10
<b>Type of ARM</b>	Recto-bulbar urethral fistula	7	37	13	65
	Recto-prostatic fistula	0	0	3	15
	Recto-vesical (bladder neck) fistula	1	5	0	0
	No fistula	0	0	3	15
	Recto-vaginal fistula	5	26	1	5
	Cloaca	4	21	0	0
	No data for level of fistula	2	11	0	0
<b>Age at surgery (months)</b>	Mean	8		8.2	
	Median	8		6	
	Range	3 - 18 months		2 days - 18 months	

TABLE II. ASSOCIATED ABNORMALITIES

Associated abnormalities	PSARP		LAARP	
	N	%	N	%
<b>VACTERL association</b>	<b>15</b>	<b>75</b>	<b>15</b>	<b>75</b>
Vertebral	6	30	5	25
Cardiac	8	40	8	40
Tracheal/oesophageal atresia	2	10	2	10
Renal	6	30	10	50
Limb	1	5	0	0
<b>Syndromes</b>				
Trisomy 21	0	0	2	10
Baller-Gerold	1	5	0	0
<b>Other abnormalities</b>				
Duodenal stenosis/web	1	5	1	5
Malrotation	1	5	1	5
Rib anomalies	2	10	1	5
Hypospadias		0	3	15
Undescended testes		0	2	10
Hip dislocation	1	5	0	0

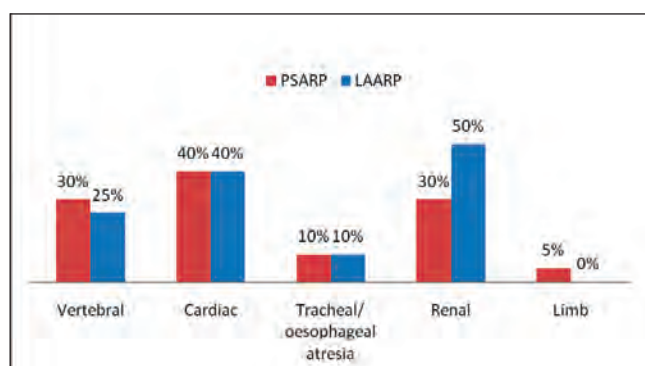


Fig. 2. VACTERL associations.

5 cases of prolapse, 1 rectal retraction, and 1 case where the neo-anus was not centred within the sphincter complex. Two complications unrelated to LAARP were related to stoma placement. One, created too low, required refashioning before surgery to allow for adequate length for the pull-through; the second, placed too medially, prevented adequate visualisation, necessitating conversion. A second conversion was required for severe adhesions. One extensive rectal stricture required a redo LAARP.

Regarding the PSARP group, post-operatively 2 patients developed superficial wound infections and 1 developed a faecal fistula, which closed spontaneously. Four patients required redo PSARP – 1 for prolapse, and 3 for sub-optimal placement within the muscle complex.

In terms of long-term continence, 70% of both groups were eligible for evaluation, and mean age was 5.9 years (PSARP) and 5.5 years (LAARP). Results are shown in Table IV and Fig. 3. Only 14% of each group reported voluntary bowel movements. Four of the LAARP group depended on rectal washouts to achieve social continence, compared with 6 of the PSARP group. Soiling and incontinence were significant in both groups. Severe constipation was seen in 21% of the PSARP v. 14% of the LAARP group.

## Discussion

The reconstruction of ARMs poses significant challenges. Although theoretical and practical advantages to LAARP exist, evaluation of long-term outcomes is insufficient, with only 4 comparative studies to date.<sup>12</sup> The Krickenbeck classification has allowed standardisation of descriptive, semi-quantitative functional assessments, allowing for more objective comparisons between reported series.<sup>2</sup> Functional outcome of high lesions after PSARP is not uniformly good, with social continence achieved in only 7 - 33%.<sup>13,14</sup> Severe constipation was reported in 40 - 60%.<sup>13-15</sup> Our results compare favourably with these reports.

Anal stenosis was a particular problem in the LAARP group, as well as rectal mucosal prolapse. However, both groups showed a high number of patients needing management for both prolapse and partially incorrect placement of the anus. The high intra-operative and early post-operative rate of complications in the LAARP group was of concern. The vas and urethral injury was due to poor visualisation from equipment failure. Although a 'learning curve', with laparoscopic surgical techniques, extending to all participating staff and even equipment maintenance, can be expected, this should not be at the expense of patient outcome.

Completely confident continence was poor in both groups on long-term evaluation. Many needed a bowel management programme (high-volume retrograde enema). It was noted that a very similar proportion of both groups had grade 3 soiling (23% PSARP and 21% LAARP respectively), which probably reflects the proportion of patients with other co-morbidities (e.g. VACTERL, etc.). While the number of children on rectal washouts was higher in the PSARP group, this may be attributed to the slightly older median age group (social reasons) rather than worse continence scoring. VACTERL associations, and associated spinal abnormalities or syndromic presentations, which could otherwise account for poorer continence, were very similar among the two groups.

**TABLE III. DIRECT PROCEDURAL AND INDIRECT COMPLICATIONS**

Direct procedural and indirect complications	PSARP		LAARP	
	N	%	N	%
<b>Colostomy related</b>	<b>1</b>	<b>5</b>	<b>2</b>	<b>10</b>
<b>Operative</b>				
Urethral injury		0	1	5
Vas injury		0	1	5
Conversion to laparotomy			2	10
<b>Early post-op</b>				
Wound sepsis		0	2	10
Wound dehiscence	2	10		0
Retraction (rectal or vaginal)	1	5	1	5
Pelvic sepsis		0	1	5
Port-site hernia		0	2	10
Laparotomy needed	1	5	4	20
<b>Late post-op</b>				
Malplaced anus at follow-up EUA	1	5	1	5
Faecal fistula	1	5		0
Rectal stricture	0	0	1	5
Anal stenosis/stricture	1	5	3	15
Mucosal prolapse	3	15	2	10
Full thickness prolapse	0	0	1	5
Redo-ano rectoplasty needed	3	15	1	0
Redo-anoplasty needed	1	5	5	25

**TABLE IV. FUNCTIONAL OUTCOME**

Functional outcome	PSARP		LAARP	
	N	%	N	%
<b>Continence outcome</b>				
>3 yrs old to assess continence	14	70	14	70
Mean age currently	5.9		5.5	
>3 yrs and lost to follow-up		0		0
Soiling day and night	3	21	2	14
Soiling during day only		0	1	7
No constipation		0		0
Nocturnal enuresis	1	7		0
Diurnal and nocturnal enuresis	0	0		0
Rectal washouts	6	43	4	29
Average No. washouts/week	7		7	
<b>Krickenbeck scoring</b>				
Voluntary bowel movements	2	14	2	14
Grade 1 soiling	3	21		0
Grade 2 soiling	1	7	1	7
Grade 3 soiling	3	21	2	14
Grade 1 constipation	0	0		0
Grade 2 constipation	2	14	2	14
Grade 3 constipation	3	21	2	14

A major drawback of this study is that it is retrospective. Differences in constipation incidence may be skewed because of the incidence of anal stenosis occurring in LAARP patients who were still too young to be assessed. Although initially included in the PSARP group, the relatively high numbers of cloaca patients were treated as a separate group in terms of functional evaluation, as they represented patients with complex lesions,

and a poorer long-term outcome is to be expected, in terms of continence, compared with other ARMs.

The increased association of anal stenosis in the LAARP procedure might be due to the fact that the perineum is not as extensively opened as in PSARP, leading to a smaller fashioned anoplasty. A similar principle might apply for rectal narrowing, since the rectal channel is dilated up to accept a 10 mm port

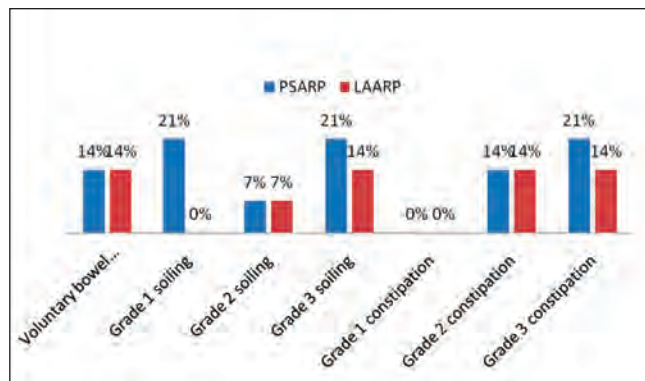


Fig. 3. Krickenbeck scoring.

irrespective of the age of the child. In our series, some of the children were quite old, and a 10 mm anorectal canal might not have been adequate. Care needs to be taken to anchor the anal mucosa adequately to prevent prolapse and to ensure a wide anoplasty.

The importance of good stoma placement in the neonatal period cannot be over-emphasised to avoid subsequent problems with pull-through. Wrong stoma placement causing ischaemia from devascularisation and stretch as well as diathermy itself or a combination of all factors seem to be possible reasons for the rectal and anal stenosis encountered. We are of the opinion that the younger the baby when the LAARP is performed, the better the outcome might be, since the use of diathermy is being replaced by a blunt dissection technique.

Other studies have shown a shorter post-operative stay in LAARP patients.<sup>16</sup> It was not within the scope of our study to compare operative costs or length of hospital stay. However, the total cost of laparoscopic compared with open procedures, including cost of purchasing and maintaining the equipment and the nursing burden of care, is very variable between different types of procedure,<sup>17,18</sup> and no data exist for the LAARPs in this respect.

Both LAARP and PSARP have been shown to be successful in treating a range of ARMs. However, patient selection for LAARP is most appropriate to those otherwise requiring laparotomy for supra-levator lesions (ARM with bladder-neck or prostatic-urethral rectal fistulae). Intra-operative LAARP complications seem to be high; most can be attributed to a 'learning curve', difficulties with resource restrictions influencing the allocation of laparoscopic trained nursing staff to the ward and theatre, and the difficulties of exchanging old with more appropriate instrumentation.

## Conclusion

Both the LAARP and PSARP procedures can successfully treat ARM with comparable outcomes. It appears that LAARP is

optimal for high ARMs that would otherwise require a laparotomy to facilitate adequate mobilisation. Further prospective trials are needed to compare outcomes between LAARP and PSARP. The assessment of long-term outcome highlights the importance of a bowel management programme to achieve social continence in ARM. To improve the quality of life of these children, it is paramount that there is a dedicated ARM clinic where a multi-disciplinary team can provide treatment of the highest possible standards. Future partnerships between the private and public sectors may facilitate this goal.

## REFERENCES

- Levitt MA, Pena A. Anorectal malformations. *Orphanet J Rare Dis* 2007;2:33.
- Holschneider A, Hutson J, Pena A, et al. Preliminary report on the International Conference for the Development of Standards for the Treatment of Anorectal Malformations. *J Pediatr Surg* 2005;40(10):1521-1526.
- Rintala RJ, Pakarinen MP. Imperforate anus: long- and short-term outcome. *Semin Pediatr Surg* 2008;17(2):79-89.
- Hashish MS, Dawoud HH, Hirschl RB, et al. Long-term functional outcome and quality of life in patients with high imperforate anus. *J Pediatr Surg* 2010;45(1):224-230.
- Ashcraft K. Nonurologic anomalies associated with anorectal malformations. In: *Anorectal Malformations in Children*. Holschneider AM, Hutson JM, eds. Berlin: Springer-Verlag, 2006:263-269.
- Stephens FD. Wingspread anomalies, rarities, and super rarities of the anorectum and cloaca. *Birth Defects Orig Artic Ser* 1988;24(4):581-585.
- deVries PA, Pena A. Posterior sagittal anorectoplasty. *J Pediatr Surg* 1982;17(5):638-643.
- Georgeson K. Laparoscopic-assisted anorectal pull-through. *Semin Pediatr Surg* 2007;16(4):266-269.
- Georgeson KE, Inge TH, Albanese CT. Laparoscopically assisted anorectal pull-through for high imperforate anus – a new technique. *J Pediatr Surg* 2000;35(6):927-930; discussion 30-1.
- Hay SA. Transperineal rectovesical fistula ligation in laparoscopic-assisted abdominoperineal pull-through for high anorectal malformations. *J Laparoendosc Adv Surg Tech A* 2009;19 Suppl 1:S77-79.
- Lopez M, Kalfa N, Allal H, et al. Anorectal malformation (ARM) with bladder fistula: Advantages of a laparoscopic approach. *Eur J Pediatr Surg* 2009; Jun 10 [epub ahead of print].
- Al-Hozaim O, Al-Maary J, AlQahtani A, Zamakhshary M. Laparoscopic-assisted anorectal pull-through for anorectal malformations: a systematic review and the need for standardization of outcome reporting. *J Pediatr Surg* 2010;45(7):1500-1504.
- Pena A. Continence after posterior sagittal anorectoplasty. *J Pediatr Surg* 1992;27(3):415-417.
- Rintala RJ, Lindahl H. Is normal bowel function possible after repair of intermediate and high anorectal malformations? *J Pediatr Surg* 1995;30(3):491-494.
- Hassett S, Snell S, Hughes-Thomas A, Holmes K. 10-year outcome of children born with anorectal malformation, treated by posterior sagittal anorectoplasty, assessed according to the Krickenbeck classification. *J Pediatr Surg* 2009;44(2):399-403.
- Yang J, Zhang W, Feng J, et al. Comparison of clinical outcomes and anorectal manometry in patients with congenital anorectal malformations treated with posterior sagittal anorectoplasty and laparoscopically assisted anorectal pull through. *J Pediatr Surg* 2009;44(12):2380-2383.
- Kuwabara K, Matsuda S, Fushimi K, Ishikawa KB, Horiguchi H, Fujimori K. Community-based appraisal of laparoscopic abdominal surgery in Japan. *J Surg Res* 2010; epub Oct 21.
- Norwood MG, Stephens JH, Hewett PJ. The nursing and financial implications of laparoscopic colorectal surgery: data from a randomised controlled trial. *Colorectal Dis* 2010; Oct 19 [epub ahead of print].
- Mattix KD, Novotny NM, Shelley AA, Rescorla FJ. Malone antegrade continence enema (MACE) for fecal incontinence in imperforate anus improves quality of life. *Pediatr Surg Int* 2007;23(12):1175-1177.
- Al-Malki TA. Medical and surgical management of fecal incontinence after repair of high imperforate anus anomalies. *Saudi Med J* 2010;31(3):284-288.