

## Popliteal vein aneurysm

S. B. IBIROGBA, M.B. B.S., H.DIP. (SURG.) S.A., F.C.S. (S.A.), M.MED. (SURG.)

N. G. NAIDOO, M.B. CH.B., F.C.S. (S.A.)

I. HASSIM, B.TECH. VASCULAR

M. NELSON, B.TECH. VASCULAR

Vascular Unit, Department of Surgery, Groote Schuur Hospital and University of Cape Town

S. J. BENINGFIELD, M.B. CH.B., F.FRAD. (D.) (S.A.)

Division of Radiology, Groote Schuur Hospital and University of Cape Town

Infra-inguinal venous aneurysms are uncommon and isolated popliteal vein aneurysms are particularly rare, with less than 100 cases reported in the literature.<sup>1</sup> While the overall incidence is unknown, the male/female ratio is equal and the majority of cases occur in patients aged over 50 years. Most patients are asymptomatic, but the condition can present as an unusual source of fatal pulmonary embolism.<sup>2,3</sup> Other symptomatic presentations include swelling in the popliteal fossa, local pain and the post-phlebitic syndrome.

We present a case of an asymptomatic popliteal vein aneurysm detected on routine investigation of varicose veins.

### Case report

A 58-year-old woman presented with bilateral primary varicose veins in the long saphenous distribution. These caused discomfort on the left side but not pain or pruritus. She had initially noticed the varicose veins at the age of 18. There was no preceding history of deep-vein thrombosis or trauma, but her sister had varicose veins.

Physical examination revealed no pelvic mass, ankle oedema or other physical signs of deep-vein thrombosis. Bilateral varicose veins with a trunkal, venular and reticular long saphenous vein (LSV) distribution and pattern were noted, and were more marked on the left leg.

The Trendelenburg test confirmed bilaterally incompetent sapheno-femoral junctions (SFJs) and LSVs. Perthe's test revealed patent deep venous systems.

Venous duplex scanning demonstrated bilateral SFJ and LSV incompetence and a left above-knee popliteal vein aneurysm measuring approximately 22 mm in diameter with no intraluminal thrombus. A computed tomography (CT) scan of the venous system performed with intravenous iodinated contrast medium confirmed the presence and extent of the aneurysm (Fig. 1). No other aneurysms were detected.

The patient underwent high left saphenous vein ligation and stripping of the left lower limb LSV. Repair of the popliteal vein aneurysm was scheduled for a later stage.

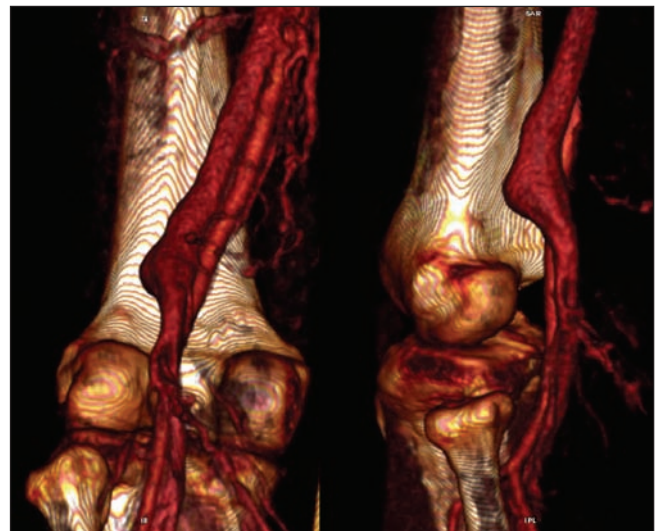


Fig. 1. CT venogram demonstrating the left popliteal vein aneurysm.

### Discussion

Aneurysms of the venous systems are rare, with a few isolated cases of aneurysms involving the jugular, portal and femoral veins and the vena cava having been reported.<sup>4</sup> Most were asymptomatic.

Forty years ago, May and Nissel first reported a popliteal vein aneurysm.<sup>5</sup> The popliteal vein is considered aneurysmal when it exceeds 20 mm in diameter. These are true aneurysms involving all three layers of the vein, and are usually saccular and involve the above-knee popliteal vein. Histological examination reveals loss of smooth-muscle cells and replacement with fibrous tissue in the vein wall.

The causes of popliteal vein aneurysms include congenital weakness, degenerative change, inflammation and trauma. Aneurysms of the popliteal vein arising as a result of entrapment of the vein by the medial head of the gastrocnemius muscle have also been reported.<sup>6</sup>

Males and females appear to be equally affected, with most cases occurring in patients over the age of 50 years.

Popliteal vein aneurysms are mostly asymptomatic, but may present as a source of recurrent pulmonary embolism. Winchester *et al.* cite a 70 - 80% rate of pulmonary embolism leading to the diagnosis of popliteal vein aneurysms.<sup>7</sup> Other less common presentations include localised pain, signs of tibial nerve compression, and a mass in the popliteal fossa.

Clinical examination alone is not adequate for the diagnosis of popliteal vein aneurysm. Useful modalities in the diagnosis of popliteal vein aneurysms include duplex Doppler ultrasound, magnetic resonance imaging and direct venography.

In our patient ultrasound scanning was performed to assess the superficial and deep venous systems, and the CT venogram was used to delineate the venous anatomy.

Treatment of popliteal vein aneurysm depends upon the size and associated symptoms. Small aneurysms can be managed conservatively with duplex Doppler surveillance and anticoagulation, as they carry a low risk of pulmonary embolism.<sup>8</sup> On the other hand, large aneurysms (>25 mm) may be associated with an up to 80% chance of pulmonary embolism. Surgical treatment is the preferred option. Endovascular treatment of popliteal vein aneurysms has not yet been documented.

As our patient only has a small aneurysm of 22 mm, surgical intervention is not considered an option at this

stage. She is therefore currently undergoing aneurysm surveillance by Duplex ultrasound. After 1 year there has been no increase in size of the aneurysm and no intraluminal thrombus has been noted.

In summary, our case demonstrates the importance of venous ultrasound in the assessment of the superficial and deep venous systems in patients with varicose veins before surgical intervention.

#### REFERENCES

1. Davis JW, Livesay JJ, Herrera LJ. Popliteal vein aneurysm presenting as a popliteal mass. *Texas Heart Inst J* 2006; 33(2): 246-248.
2. Dalton RSJ, Chester JF, Williamson JML. Popliteal venous aneurysm causing pulmonary embolism and paradoxical embolisation in a patient with antiphospholipid syndrome. *Eur J Vasc Endovasc Surg* 2008; 36: 227-229.
3. Tellez R, Iborra E, Cairols MA, Simeon JM, Rancano J. Popliteal vein aneurysm as a source of recurrent pulmonary embolism. *Eur J Vasc Endovasc Surg* 1999; 18: 171-173.
4. Calligaro K, Ahmad S, Dandora R. Venous aneurysm: surgical indications and review of the literature. *Surgery* 1995; 117: 1-6.
5. May R, Nissel R. Aneurysmal der vena poplitea. *Rofo Fortschr Geb Rontgenstr Neuen Bildgeb Verfahr* 1968; 108: 402-403.
6. Rich NM, Hughes CW. Popliteal artery and vein entrapment. *Am J Surg* 1967; 113: 696-698.
7. Winchester D, Pearce WH, McCarthy WJ, McGee GS, Yao JST. Popliteal venous aneurysms. *Surgery* 1993; 114: 600-607.
8. Sessa C, Nicolini P, Perrin M, Farah I, Magne JL, Guidicelli H. Management of symptomatic and asymptomatic popliteal venous aneurysms: A retrospective analysis of 25 patients and review of the literature. *J Vasc Surg* 2000; 32: 902-912.