

# Chronic osteomyelitis in Ilorin, Nigeria

SAMUEL B. AGAJA, F.R.C.S., F.W.A.C.S

Department of Surgery, University of Ilorin Teaching Hospital, Ilorin, Kwara State, Nigeria

RAPHAEL O. AYORINDE, M.B.B.S., F.W.A.C.S. (ORTH.)

Department of Orthopaedic and Trauma Surgery, Kwara State Specialist Hospital, Sobi, Ilorin, Nigeria

## Summary

*Aim.* To review cases of chronic osteomyelitis managed at a private health institution (Ela Memorial Medical Centre, Ilorin, Nigeria) between March 1995 and February 2005.

*Patients and methods.* Case notes and X-rays of the patients who presented at EMMC with chronic osteomyelitis were reviewed retrospectively. Age, sex, sites of bone involvement and outcome of treatment were recorded. Local surgical debridement (including saucerisation, sequestrectomy and curettage) was the cornerstone of treatment. All patients received antibiotics for at least 6 weeks.

*Results.* Of the 107 cases, 71 (66.4%) were males, with a male-to-female ratio of 2:1. The mean age was 21.9 years (range 1.5 - 80 years). Chronic osteomyelitis is most common in the first and second decades of life (55.2%) and mostly affects people <50 years of age (93.5%). Haematogenous osteomyelitis was the most common cause of chronic osteomyelitis (81.3%). The most common bone site was the tibia (32.7%). Nearly all (103) were adjudged cured; only 3 patients suffered a recurrence.

*Conclusion.* Chronic osteomyelitis is common in Nigeria. Most cases occur in the first and second decades of life, with haematogenous osteomyelitis being the most common cause. A high index of suspicion of osteomyelitis in children with septicaemia, and the proper treatment of patients with open fractures, will help to reduce the occurrence of the disease.

Osteomyelitis is an infection of the bone and marrow. About 70 years ago, 20% of patients with osteomyelitis died, and those who survived had significant morbidity.<sup>1</sup> However, with antibiotics and more sophisticated treatment techniques, the risk of death has become negligible and the complication rate has dropped to about 5%.<sup>1</sup> Chronic osteomyelitis is a major complication of acute osteomyelitis. It is more common in developing countries, owing to a combination of the virulence of pathogenic bacteria in developing countries, late presentation for treatment, poor nutritional and immune state of the patients, and relatively poor access to antibiotic drugs.<sup>2</sup>

Chronic osteomyelitis may cause lifelong morbidity for the patient. In the past, it was regarded as incurable, but modern surgery and medical treatments have achieved a prolonged disease-free interval and, in some cases, cure. In established chronic osteomyelitis, surgery is usually necessary to arrest the infection. The aim of surgery is to excise all infected dead

bone and soft tissue. The resultant defect may be filled with bone, antibiotic beads, graft and/or muscle flap cover. Ilizarov external fixation and amputation have been performed in some cases.<sup>3,4</sup>

## Patients and methods

All patients admitted to Ela Memorial Medical Centre (EMMC), Ilorin, Nigeria, with chronic osteomyelitis from 1995 to 2005 were included in this study. EMMC is a private hospital approved to provide medical services including surgical operations. We carried out a retrospective review of the files of the patients. The data collected included aetiology, age, sex of the patient, bone sites involved, and the results of wound microbiological studies. All patients with a clinical suspicion of chronic osteomyelitis had the diagnosis confirmed with plain radiographs. Patients with established bone-in-bone appearance had a sequestrectomy. Serial measurements of the erythrocyte sedimentation rate (ESR) were done to monitor the progress of the disease. All patients received antibiotics for a minimum of 6 weeks.

## Results

Over a period of 10 years, 107 patients presented with chronic osteomyelitis; all required operation. There were 71 males (66.4%) with a male-to-female ratio of 2:1. The mean age was 21.9 years (range 1.5 - 80 years). Slightly more than half the patients (55.2%) were <20 years old. One hundred (93.5%) were <50 years of age (Fig. 1).

The aetiological factors are shown in Table I. Haematogeneous osteomyelitis was the most common cause (81.3%). The bone sites involved are shown in Table II. The disease affected a wide range of sites. The tibia was most frequently involved (32.7%), followed by the femur (25.5%). Most patients (96.3%) presented with mono-ostotic osteomyelitis; only 3.7% presented with multi-ostotic osteomyelitis (Table III). The most common organism cultured was *Staphylococcus aureus* (37.6%); no organism could be cultured in 21 patients (Table IV). There was a wide range of sensitivity and resistance. There were 3 cases of recurrence; the rest of the patients were considered cured after treatment.

## Discussion

Chronic osteomyelitis is a condition that may result in lifelong morbidity.<sup>5</sup> It is still common in Nigeria despite the availability of potent antibiotics and surgery.<sup>3,6</sup> We confirm

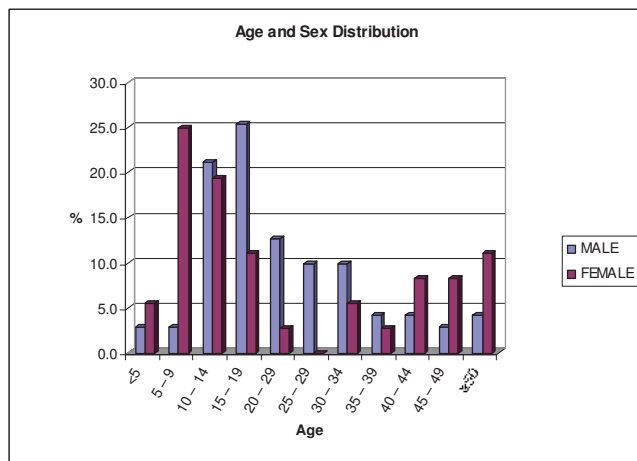


Fig. 1. Age and sex distribution.

	Number of cases	Percentage
Haematogeneous osteomyelitis	87	81.3
Road traffic accident	6	5.6
Gunshot injury	3	2.8
Falls	4	3.7
ORIF	3	2.8
Fracture	2	1.9
Traditional bonesetter treatment of fracture	2	1.9
<b>Total</b>	<b>107</b>	<b>100.0</b>

Bones affected	Number	Percentage
Tibia	39	35.2
Femur	28	25.2
Humerus	15	13.5
Ulna	8	7.2
Fibula	5	4.5
Foot	4	3.6
Head and neck	4	3.6
Pelvic	4	3.6
Radius	3	2.7
Hand	1	0.9
<b>Total</b>	<b>111</b>	<b>100</b>

Sex	Age (years)	Bone site
F	9	(R) radius and (R) ulna
M	29	(R) tibia and (R) femur
M	45	(L) radius and (L) ulna
F	35	(R) humerus and (L) humerus

that the most common source of chronic osteomyelitis in Nigeria is haematogeneous infection, which accounted for more than 80% of cases in this study, owing to either mismanagement or neglected acute haematogeneous osteo-

TABLE IV. COMMON CULTURED ORGANISMS FROM CHRONIC OSTEOMYELITIS

Organism	Number	Percentage
<i>Staphylococcus aureus</i>	40	37.6
No organism	21	19.6
Coliforms	12	11.2
<i>Klebsiella</i>	10	9.3
<i>Escherichia coli</i>	10	9.3
<i>Proteus</i>	7	6.5
<i>Pseudomonas</i>	7	6.5

myelitis. In the study by Onuminya and Onabowale,<sup>3</sup> haematogeneous osteomyelitis accounted for more than 85% of cases of chronic osteomyelitis. In Europe, post-traumatic osteomyelitis accounts for more than 90% of cases.<sup>4,7-9</sup>

*S. aureus* was the most frequently cultured organism in this series, which is in line with standard patterns.<sup>1,5</sup> There was a wide range of sensitivity and resistance. The high proportion of 'no growth' culture in this study might have resulted from the tradition of self-medication and prescription of drugs, including antibiotics, by unqualified individuals. The choice of antibiotics depends on sensitivity result, age of the patients, availability and cost of the drugs. The commonly used drugs include, but are not limited to, ciprofloxacin, cefuroxime, azithromycin, co-amoxiclavulanic acid, and gentamicin.

In this series, the lower limbs were affected in 71.5% of cases, the upper limbs in 22.1%, and the head and neck in 3.5%; the tibia was the bone most frequently affected (33%), followed by the femur (26%). In earlier studies from Nigeria, the femur was the most common site,<sup>3,6,10,11</sup> involved in 50% of cases. Some researchers from Europe have also reported the involvement of the tibia to be more common than the femur.<sup>9,12,13</sup> However, the majority of their cases were post-traumatic chronic osteomyelitis. We found that acute haematogeneous osteomyelitis was the major cause of chronic osteomyelitis. Other causes of chronic osteomyelitis from our series included open fractures after road traffic accidents, gunshot injuries, falls, open reductions and internal fixations, and wounds poorly treated by traditional bonesetters. The establishment of chronic osteomyelitis as a result of inoculation by bacteria from the environment depends on the size of the inoculum, the virulence of the bacteria and the loss of resistance of the host tissues caused by their disruption. The incidence is about 5% for open fractures and 1% for closed fractures.<sup>3</sup> Road traffic injuries and falls are a common cause of fractures. Chronic osteomyelitis may also result from road traffic accidents and falls without fractures, when the parties sustain bruises, abrasions and lacerations, especially over subcutaneous bones like the tibia.

This review brings to the fore the need to improve aseptic techniques when performing open reduction and internal fixation (ORIF) to eliminate the risk of infection which may result in osteomyelitis. The most worrisome complication of treatment in chronic osteomyelitis was recurrent infection at the femoral and tibia sites, which warranted a series of repeated operations and prolonged antibiotic therapy.<sup>3</sup> The problem of recurrent infection of the femur does not appear to be due to poor vascularisation (as with the tibia) since the femur is adequately covered with muscles. Inadequate debridement is therefore more likely to be the cause of the 'recurrence'.<sup>3</sup> As advocated by some authors, local flap

cover and the use of Ilizarov techniques were advised.<sup>3,13</sup> The common treatment in this study was a combination of saucerisation, sequestrectomy and curettage. Other treatment modalities such as Ilizarov techniques, use of antibiotic beads and free vascularised muscle flaps were not employed because of lack of facilities.<sup>3,13</sup>

Chronic osteomyelitis usually follows a severe and protracted course. With the non-availability, and the prohibitive cost, of the more recent techniques of treatment, especially in developing countries like Nigeria, an ounce of prevention is better than a pound of cure. The two forms of intervention required are diagnostic and therapeutic. If the clinical history and examination clearly suggest acute osteomyelitis, no diagnostic test is necessary. Prompt, effective therapy should not be delayed.

Prevention of road traffic accidents (an impossible ideal!) would eliminate chronic osteomyelitis from this source.<sup>14</sup> Open fractures should be treated by orthopaedic surgeons; treatment by traditional bonesetters should be discouraged. Routine aseptic techniques should be followed while performing ORIF. Where this cannot be guaranteed, fractures should be treated by closed means. Judicious management of injuries is important.

## Conclusion

Chronic osteomyelitis is still common in our environment, and the haematogenous route of infection is predominant. It

occurs mostly in the first and second decades of life. A high degree of suspicion of possible osteomyelitis in children with septicaemia, and proper management of patients with open fractures, will reduce the occurrence of the disease.

## REFERENCES

1. Wanner WC, jr. Osteomyelitis. In: Jones L, Canale T, Canale ST, eds. *Campbell's Operative Orthopaedics* 9th ed. St Louis, MO: Mosby, 1998.
2. Nade S. Acute and chronic osteomyelitis. *Surgery* 1997; 15(1): 248-252.
3. Onuminya JE, Onabowale BO. Outcome of chronic osteomyelitis in Nigeria. *Journal of Applied and Basic Sciences* 2003; Vol. 1 no. 1 & 2: 27-32.
4. McNally AM, Small OJ, Tofighi GH, Mollan BAR. Two-stage management of chronic osteomyelitis of long bones: The Belfast technique. *J Bone Joint Surg* 1993; 75B (3): 375-380.
5. Wordsworth P. Diseases of bones and joints: Infections. In: Russell RCG, Williams NS, Bulstrode CJK, eds. *Bailey and Love's Short Practice of Surgery*. 24th ed. London: Arnold, 2004: 419-430.
6. Katchy UA, Agu CT, Nwankwo EO. Chronic osteomyelitis in 110 patients. *Niger Postgrad Med J* 2000; 7(2): 49-53.
7. McAllister TA. Treatment of osteomyelitis. *Br J Hosp Med* 1994; 12: 535-545.
8. Anthony JP, Mathes SJ. Update on chronic osteomyelitis. *Clinic Plastic Surg* 1991; 18(3): 515-523.
9. Cierny G, Mader JT, Penninch JJ. A clinical staging system of adult osteomyelitis. *Contemp Orthop* 1985; 10: 17.
10. Essien JAI, Ndukwue UA. Chronic osteomyelitis. A 12-month experience at the National Orthopaedic Hospital, Enugu. *Niger Postgrad Med J* 1994; 1(3): 22-25.
11. Ofiaeli RO. Radiological features of chronic osteomyelitis in long bones and the effects on diaphyseal sequestration on linear growth. *Orient J Med* 1991; 3(2): 20-22.
12. Infections. In: Solomon L, Warwick D, Nayagam S, eds. *Apley's System of Orthopaedics and Fractures*. 8th ed. London: Arnold, 2001: 27-48.
13. Green AS. Osteomyelitis: The Ilizarov Perspective. *Orthop Clin North Am* 1991; 22(3): 515-521.
14. Agaja SB. Road traffic injuries: A serious cause for concern in Nigeria. *Niger Clin Rev* 2005; 9(3): 33-42.