SAJS
General Surgery

A tension-free technique for the repair of large incisional hernias during abdominal surgery: Results and long-term outcome

A. VANNELLI, M.D.
L. BATTAGLIA, M.D.
E. POIASINA, M.D.
Foundation IRCCS – Istituto Nazionale dei Tumori, Division of General Surgery B, Milan, Italy

C. CORSI, M.D.
C. DEL CONTE, M.D.
F. FIORE, M.D.
Department of Surgery, Division of Digestive and General Surgery, San Paolo Hospital, Milan, Italy

V. VALERA, M.D.
First Department of Surgery, Division of Digestive and General Surgery, Niigata University, Japan

Incisional hernias have traditionally been treated by primary closure of the fascial defect. However, especially with large incisional hernias, this procedure exposes the suture to excessive tension and can result in two severe complications: acute respiratory insufficiency and early incisional hernia recurrence.[1] The majority of surgeons have therefore given up performing primary repair.

With the introduction of synthetic prosthetic materials in the mid-1980s, several approaches have been described as alternatives to primary closure, with the retrorectal technique (Rives-Stoppa procedure)[2] being the most common of those used for the repair of large aponeurotic defects. The Rives technique has simplified the treatment of large incisional hernias to a remarkable extent.[3]

The repair of this type of hernia during intra-abdominal surgery is a more complex and challenging problem, and severe difficulties prevent surgeons from treating a ventral hernia during abdominal surgery. For instance, the high incidence of postoperative infections reported with the use of the Rives technique led for a long time to not using a plastic prosthesis in this setting.[4,5] However, it is very difficult to repair a large (>5 cm) abdominal wall defect without any mesh because the surgeon, according to the classic rules, will attempt to repair the abdominal wall and suture the wound with simple approach stitches. In this context, the Rives technique does not avoid the aforementioned complications completely because it is not a tension-free technique.

After gaining considerable experience with the Rives technique, we compared the results obtained with those using our modified technique,[6] and the better results persuaded us to adopt it routinely. The objective of this study was to evaluate the outcome of a modified Rives technique employed in the treatment of large incisional hernias and to prove its feasibility as a step following intra-abdominal surgery.

Materials and methods

Patients

Between January 1990 and December 2000, we treated 99 consecutive patients for large incisional hernia during abdominal surgery – 35 men and 64 women with a mean age of 61.5 years (range 29 - 90 years). All the patients had previously undergone abdominal surgery with a resulting ventral hernia. Hernia size was measured when the patient was under general anaesthesia, so that it could be estimated with the abdominal wall completely relaxed. Major and minor dimensions were observed and the area (in cm^2) was measured. We calculated the body mass index (BMI) or Quetelet index, even though these are intended to classify populations in a broad sense for purely statistical purposes. As is well known, the accuracy of these indices in relation to the actual levels of body fat is easily influenced by such factors as fitness level, muscle mass, bone structure, gender and ethnicity. Because the postoperative treatment of large incisional hernia tends to be problematic, all patients were admitted to the intensive care unit (ICU) during the first day (within 24 hours) to determine the extent of pulmonary dysfunction. No treatment data were available in the ICU for some of the patients.

Surgical technique

For preparation, first the skin is pre-treated with iodine solution; next, thrombo-embolism and antibiotic prophylaxis is given in the form of low-molecular-weight heparin and a

A Tension.indd 112 10/8/08 2:26:19 PM

second-generation cephalosporin, respectively. The steps in the technique that we adopted are as follows: the perimeter of the hernia sac is carefully defined and dissected, a good fascial or muscular edge is identified all around the hernial defect, the peritoneal cavity is reached, and adhesions are separated (Fig. 1). The rectal fascia is opened on the medial border and the opposite posterior sheaths are sutured on the midline (the omentum is never used to cover the defect) (Fig. 2). A braided polyester mesh (Mersilene Ethicon Ltd, UK) is placed on the posterior recti sheaths, and sutured through the anterior fascia with interrupted or continuous polypropylene sutures. A large mesh is fixed to the periosteum of the pelvis, to Cooper's ligament or to the ribs. The anterior rectus muscle sheath is left open, a skin lipectomy is performed, and drains are placed – one on the mesh and the other under the skin layer (Fig. 3). Postoperative care included daily dressing replacements and wound cleaning with an antiseptic solution. Drains were withdrawn when outflow drainage was <30 ml/24 h.

Follow-up

Patients were followed up for 24 months. During the first year, they underwent a hospital examination every 3 months. Infectious complications were defined as either presence of pus in the wound on clinical assessment and/or microbiological examination. Recurrence was defined as any abdominal wall gap, with or without a bulge, that was perceivable under clinical examination or imaging after the index operation. Postoperative mortality was defined as death within 30 days after surgery.

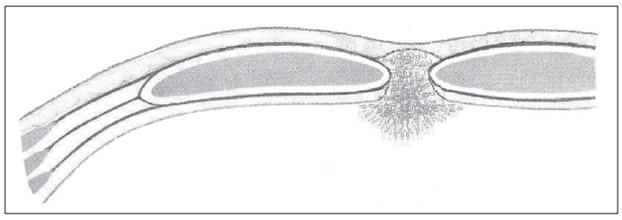

Fig. 1. Abdominal hernial sac.

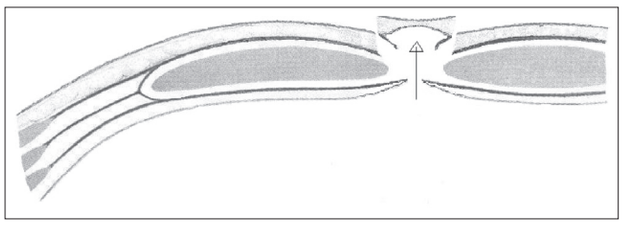

Fig. 2. Opening of the anterior and posterior layers of rectus muscle fascia. The arrow shows the direction of removal of the hernial sac.

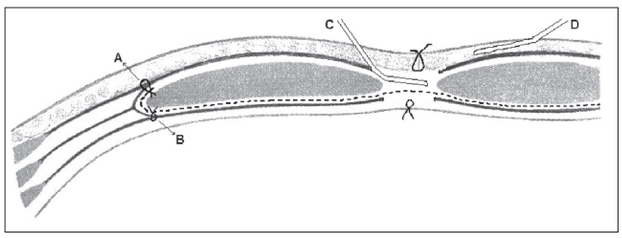

Fig. 3. Reconstruction of the abdominal wall. The broken line represents the mesh. The stitches have been fastened through the anterior layer of rectus muscle fascia (A); the mesh has been sutured on the posterior layer of rectus muscle fascia (B). Two or more closed-suction drains lie on the mesh (C) and under the skin layer (D).

Statistical analysis

Statistical comparisons were made using Student's *t*-test for continuous variables and the RxC test with Fisher's correction for the comparison of proportions. Statistical significance was defined as a p-value <0.05.

Results

Patients' characteristics and main results are summarised in Table I. To facilitate comparisons, patients were divided into three groups according to the site and type of abdominal surgery. The groups were similar in number of patients, age, sex distribution, cross diameter and hernia size. Fifty-one patients (51.5%) underwent concomitant surgery on the upper abdomen (group I), the procedures being 30 cholecystectomies, 5 gastric resections, 3 gastric fundoplications, 3 antrectomies, 4 vagotomies and 6 hepatectomies. The second group included 28 patients (28.3%) who underwent surgery on the mid-abdomen; the procedures were 6 nephrectomies, 4 adrenal gland excisions, 6 small-bowel resections, 10 colostomy closures and 2 partial resections for volvulus in the large bowel. The last group (group III) included 20 patients (20.2%) who underwent lower abdominal surgery (4 colpopexies, 8 hysteradnexectomies and 8 anterior resections of the rectum).

In the first group, there were 2 recurrences (3.9%) of incisional hernia: one after 6 weeks and the other after 12 weeks. In this group, one postoperative death occurred (7 days after surgery) because of myocardial infarction in a 94-year-old woman admitted for strangulated incisional hernia. In the second group, there was only one recurrence (3.5%) of incisional hernia after 14 weeks. No recurrences were recorded in the third group. Postoperative hospital stays were similar for the three groups, ranging from 6.1 days in the group that underwent upper abdominal surgery to 6.6 days in the lower abdominal surgery group (p=0.921). There were no differences in surgical time, BMI or hernia surface areas between groups.

Discussion

The optimal treatment of abdominal incisional hernias within the context of intra-abdominal surgery still needs to be defined. In this setting, the deferred treatment of abdominal pathology should be avoided because the need for a second laparotomy exposes the patient to risks that cancel the benefits of abdominal wall surgery, and increases the rate of morbidity and mortality. On the other hand, the simultaneous treatment of large incisional hernias during abdominal surgery with a simple suture poses the risk of severe acute respiratory failure and early incisional hernia recurrence that can be as high as 50% with fascial defects >5 cm,[7] which is commonly the case.

The keystone of the technique adopted is the suture: the stitch to fasten the mesh passes through the anterior layer of rectal fascia where it is sutured, and not through the skin. In this way, we deviated from the Rives technique; however, not suturing the anterior rectal fascia ensures the absence of tension, resulting in a lower risk of severe acute respiratory failure and early incisional hernia recurrence. The Rives tech-

A Tension.indd 113 10/8/08 2:26:21 PM

TABLE I. PATIENTS' MAIN CLINICAL CHARACTERISTICS AND RESULTS OF THE SURGICAL TREATMENT OF LARGE INCISIONAL HERNIAS REPAIRED DURING ABDOMINAL OPERATIONS

	Upper abdomen	Mid-abdomen	Lower abdomen	Total	*p*-value
Number of cases	**51**	**28**	**20**	**99**	
Age in years: average (range)	**61.5 (29 - 90)**	**59.9 (45 - 74)**	**63.6 (50 - 74)**	**61.5 (29 - 90)**	**0.441**
Sex: M/F	**18/33**	**9/19**	**8/12**	**35/64**	**0.854**
Hernia surface (cm^2): average	**463**	**467**	**459**	**462**	**0.880**
Transverse diameter: average (range)	**10.8 (10.8 - 12)**	**10.4 (10.7 - 12.3)**	**10.5 (10.9 - 12.9)**	**10.5 (10.7 - 12.9)**	**0.787**
BMI: average (range)	**25.9 (24.8 - 26)**	**25.3 (24.7 - 26.3)**	**25.6 (24.9 - 26.9)**	**25.4 (24.7 - 26.9)**	**0.769**
Minor complications:					**0.909**
• Partial necrosis of skin flap	**3 (5.8%)**	**1 (3.5%)**	**1 (5%)**	**5 (5%)**	
• Stitch abscess	**2 (3.9%)**	**1 (3.5%)**	**1 (5%)**	**4 (4%)**	
• Seroma	**1 (1.9%)**	**0 (0%)**	**1 (5%)**	**2 (2%)**	
Major complications:					**0.687**
• Large necrosis of skin flap	**2 (3.9%)**	**1 (3.5%)**	**1 (5%)**	**4 (4%)**	
• Haemoperitoneum	**1 (1.9%)**	**1 (3.5%)**	**0 (0%)**	**1 (1%)**	
Mortality	**1 (1.9%)**	**0 (0%)**	**0 (0%)**	**1 (1%)**	**0.621**
Recurrence	**2 (3.9%)**	**1 (3.5%)**	**0 (0%)**	**3 (3%)**	**0.673**
Postoperative hospital stay (days)	**6.1±2.3**	**6.5±2.4**	**6.6±2.4**	**6.3±2.3**	**0.640**

nique often requires relaxing incisions in the flat muscles, but in our tension-free technique for the repair of large incisional hernias it is not required.

We found no significant differences in infectious complications between the three groups of abdominal surgeries, though our method follows the principle of not using plastic prostheses for type II (clean-contaminated) surgical wounds. While undoubtedly important during implantation of vascular prosthetic material, there is evidence to the contrary in the case of abdominal wall surgery.[8] In fact, in this case, the different tissue nature, depth and enhanced manageability are all favourable characteristics which make this procedure feasible and straightforward.

Avoidance of contamination of the abdominal incision is necessary, by carefully protecting the two borders of the surgical wound, and preparation of the posterior rectal fascia must be the last surgical step. Sometimes surgical drainage must extend far from the mesh through the abdominal wall. Moreover, the fascia of the posterior and anterior rectus muscles must be drained with two or more large drains. In the postoperative period, careful observation is necessary to prevent incipient suppuration. Should this occur, skin sutures must be removed, leaving the mesh uncovered to be washed daily with antiseptic solution.[9] In our study group, the mesh was partially removed in one patient because of anastomosis leakage in a lower rectal resection for diverticular disease, with substitution and repositioning of the mesh, leaving the skin flaps to heal subsequently. This is supported by clinical evidence confirming that florid granulation tissue follows the quick stopping of suppuration.[8] In this way, the sheath is embedded in the granulating tissue and eventually blends with the connective tissue,[10] when it is possible to close the wound at a second attempt.

Our patients experienced 11 minor complications (Table I) without significant differences between the three groups (p=0.909), none of which had an impaired end result. The partial skin flap necrosis resolved (5 patients), the suppuration ceased with appropriate antibiotic and wound care (4 patients), and the seroma spontaneously cleared up (2 patients). Moreover, major complications did not require any surgical exploration (Table I), without significant differences between the three groups (p=0.687). The degree of skin flap necrosis (4 patients) was generally due to marginal ischaemia; to avoid this, a large area of subcutaneous layer should be isolated to apply the sutures that fasten the mesh through the fascia. The haemoperitoneum (1 patient) received conservative treatment with successful outcome.

We believe that the complication rate is acceptable when it is interpreted in the context of abdominal surgery. The case series published in the literature report major and minor complication rates ranging from 10% to 20%. In one group of 57 patients, Bauer *et al.*[11] recorded a complication rate of 3.5%. Using secondary analysis of those results and of our own case series, we found no significant statistical differences (p=0.330) in complication rates, if we use the former group as a historical reference. Moreover, we found no significant statistical differences when we compared our results regarding recurrence with those reported in the literature. Vidovic *et al.*[12] recently showed complication rates of 14.6% after prosthetic repairs in a series of 109 patients (14.6% v. our 3%,

A Tension.indd 114 10/8/08 2:26:21 PM

p=0.002). The difference in recurrence rate increases when our technique is compared with recurrence rates after primary closure in the same series (39.4% v. 3%, p<0.0001). These encouraging results and wide experience have convinced us that abdominal wall defects in patients with abdominal pathology must be treated in the same surgical session, using our modified Rives technique.

REFERENCES

1. Munegato G, Brandolese R. Respiratory physiodisease in surgical repair for large incisional hernias of the abdominal wall. *J Am Coll Surg* 2001; 192: 298-304.
2. Rives J, Lerdennois B, Pire JC, Hibon J. Les grandes éventrations. Importance du 'volet abdominal' et des troubles respiratoires qui lui sont secondaires. *Chirurgie* 1973; 99: 547-563.
3. Klinge U, Krones CJ. Can we be sure that the meshes do improve the recurrence rates? *Hernia* 2004; 9: 1-2.
4. Ammaturo C, Bassi G. Surgical treatment of large incisional hernias with an intraperitoneal Parietex composite mesh: our preliminary experience on 26 cases. *Hernia* 2004; 8: 242-246.
5. LeBlanc KA, Whitaker JM, Bellanger DE, Rhynes VK. Laparoscopic incisional and ventral hernioplasty: lessons learned from 200 patients. *Hernia* 2003; 7: 118-124.
6. Corsi C, Contin G, Perrone A, Villani RD, Fincato M. Une variante de la technique de Rives dans le traitement des éventrations. *GREPA* 1986; 8: 43-44.
7. Millikan KW. Incisional hernia repair. *Surg Clin North Am* 2003; 83: 1223-1234.
8. Deysine M. Pathophysiology, prevention, and management of prosthetic infections in hernia surgery. *Surg Clin North Am* 1998; 78: 1105-1115.
9. Bellon JM, Contreras LA, Sabater C, Bujan J. Pathologic and clinical aspects of repair of large incisional hernias after implant of a polytetrafluoroethylene prosthesis. *World J Surg* 1997; 21: 402-406.
10. Loh A, Rajkumar JS, South LM. Anatomical repair of large incisional hernias. *Ann R Coll Surg Engl* 1992; 74: 100-105.
11. Bauer JJ, Harris MT, Gorfine SR, Kreel I. Rives-Stoppa procedure for repair of large incisional hernias: experience with 57 patients. *Hernia* 2002; 6: 120-123.
12. Vidovic D, Jurisic D, Franjic BD, Glavan E, Ledinsky M, Bekavac-Beslin M. Factors affecting recurrence after incisional hernia repair. *Hernia* 2006; 10: 322-325.

A Tension.indd 115 10/8/08 2:26:22 PM