

# Surgical management of achalasia in Zaria, Northern Nigeria

A. AHMED, F.W.A.C.S.

L. M. D. YUSUFU, F.M.C.S. (NIG.), F.W.A.C.S.

Y. A. UKWENYA, F.M.C.S. (NIG.), F.W.A.C.S.

L. KHALID, F.M.C.S. (NIG.), F.W.A.C.S.

E. S. GARBA, F.W.A.C.S.

Division of General Surgery, Ahmadu Bello University Hospital, Zaria, Nigeria

## Summary

**Background.** Achalasia of the cardia is generally considered a rare disease. Because the cause is uncertain, treatment is palliative and directed at relieving distal oesophageal obstruction. In developed countries, several treatment options are available, but in developing countries, achalasia is usually treated by open surgical myotomy. We reviewed the outcome of management of achalasia in our patients and the influencing factors.

**Patients and methods.** We retrospectively reviewed all adult patients treated for achalasia between 1991 and 2006. Diagnosis was based on clinical symptoms and barium swallow examination. The severity and frequency of dysphagia were determined before and after treatment. Barium examination was repeated 2 weeks after surgery or when the patient had recurrence of dysphagia, regurgitation or heartburn. Treatment was by modified Heller's operation, transabdominally without complementary antireflux procedure. Logistic regression modelling was performed to identify factors predictive of poor outcome.

**Results.** There were 47 patients, 31 (66.0%) males and 16 females, mean age ( $\pm$  standard deviation (SD)) 34.6 $\pm$ 9.8 years. All patients presented with dysphagia, which was severe in 31 cases (66.0%) and moderate in 14 (29.8%). Preoperative maximum oesophageal diameter ranged from 34 to 89 mm, mean 67.4 $\pm$ 12.7mm. In 30 (63.8%) of the patients, the maximum diameter was >70 mm. Postoperative maximum diameter ranged from 28 to 72 mm, mean 37.5 $\pm$ 8.2 mm ( $p=0.001$ ). The mean preoperative diameter of the narrowest distal oesophagus was 4.6 $\pm$ 2.5 mm, compared with the postoperative figure of 11.6 $\pm$ 1.8 mm ( $p=0.015$ ). Following surgery, 41 (87.2%) patients had complete relief of dysphagia, regurgitation and heartburn. Four patients continued to have heartburn after surgery. Patients with severe dysphagia or preoperative oesophageal dilatation >70 mm had the greatest likelihood of incomplete relief of symptoms after treatment.

**Conclusion.** Achalasia can be accurately diagnosed on the basis of clinical symptoms and barium swallow examination. A modified Heller's operation provides lasting relief of symptoms. Patients with severe preoperative dysphagia or oesophageal dilatation are more likely to have poor outcome of treatment.

Achalasia of the cardia is the most common primary motility disorder of the oesophagus. It is characterised by degeneration of the inhibitory ganglion cells of the Auerbach submucous plexus, which results in the absence of primary peristalsis in the oesophagus and an increasing inability of the lower oesophageal sphincter (LOS) to relax in response to swallowing.<sup>1,2</sup> There is also a sustained elevation of the LOS pressure in approximately 50% of patients tested manometrically.<sup>2-4</sup> The cause of achalasia is not known, and may include autoimmunity and viral infection.<sup>3</sup> Familial occurrence also suggests genetic predisposition.<sup>5</sup> In developed countries, the incidence is 0.5 - 1 per 100 000 people.<sup>6,7</sup> Among other oesophageal diseases, it accounts for 3.1 - 20% of cases.<sup>7</sup> Because the cause is uncertain, current treatments are only palliative and directed toward relieving dysphagia and preventing stasis and related complications. A reduction in LOS pressure can be achieved by disrupting the LOS muscle fibres by generating a radial force from within the oesophageal lumen (by pneumatic dilation), by cutting the muscle fibres (as in myotomy) or by poisoning them with botulinum toxin (BTox).<sup>8,9</sup> Treatment with BTox involves repeated injections to maintain relief of dysphagia, and is reserved for patients in whom other forms of treatments are contraindicated.<sup>9,10</sup> Pneumatic dilatation is simple and can be performed under endoscopic or fluoroscopic guidance.<sup>9</sup> However, the procedure is associated with complications including perforation in 4 - 6% of patients, gastro-oesophageal reflux (GOR) in 2.5 - 26.5%, and haemorrhage.<sup>3</sup> While endoscopic treatment may provide partial or short-term relief, most patients with achalasia eventually require surgical management because only operative treatment has been proven to provide long-term relief of dysphagia. Comparison of surgical myotomy and BTox injection revealed that the probability of being symptom-free at 2 years was 87.5% after surgery and 34.0% after BTox injection.<sup>11</sup> Surgical myotomy also has better long-term control of symptoms and fewer complications when compared with pneumatic dilatation (PD). A recent population-based study reported that both Heller myotomy and PD provided good relief of symptoms.<sup>12</sup> However, the cumulative risk of subsequent intervention for achalasia at 10 years was 63.5% for patients initially treated with PD, compared with 37.5% for patients initially treated with surgical myotomy.<sup>12</sup> Other reports indicate that oesophagocardiomyotomy provides symptom relief in about 90%

of patients, with more than 80% remaining dysphagia-free at 5 years.<sup>13,14</sup> Currently, the universally accepted surgical treatment of achalasia is the Heller myotomy, as modified by Zaaijer.<sup>15,16</sup> It can be performed through an abdominal or thoracic approach either by open or minimally invasive surgery. The role of antireflux procedure following oesophagomyotomy remains controversial. Recently, many articles attested to the superiority of adding either a Toupet or a Dor procedure to the myotomy.<sup>2,14,17</sup> However, addition of an anti-reflux procedure may be associated with delayed oesophageal emptying, and good postoperative relief of dysphagia with low incidence of GOR symptoms can be achieved without it.<sup>18-20</sup>

Achalasia is not a common disease in sub-Saharan Africa, with only about 3 patients per year seen in our hospitals.<sup>21-23</sup> Many of these patients present with longstanding dysphagia for both liquids and solids, and symptoms of severe malnutrition. In elderly patients, the differentiation between primary and pseudo-achalasia becomes critical. In pseudo-achalasia, oesophageal motor dysfunction is not caused by a primary denervation disorder but rather by neoplasm or postoperative obstruction of the oesophagogastric junction. In general, patients with pseudo-achalasia are older and have a shorter history of dysphagia and weight loss. There are very few reports evaluating the outcome of management of achalasia from the West African sub-region.<sup>21,22</sup> We present here our recent experience in the management of primary achalasia in a setting with limited diagnostic and therapeutic facilities. We also evaluate the outcome of treatment and preoperative factors that affect it.

## Patients and methods

This retrospective study was carried out in the Department of Surgery of Ahmadu Bello University Hospital in Zaria, Northern Nigeria. All adult patients who were seen and treated for achalasia of the cardia between 1991 and 2006 were included. Diagnosis of achalasia was based on clinical symptom assessment and barium swallow examination. Dysphagia was defined as mild when occurring with solid food, moderate with semi-liquid food, and severe with liquid food. Preoperative evaluation included detailed history and physical examination, barium oesophagogram and transabdominal ultrasonography. Serum urea and electrolytes, full blood count and chest radiograph were also performed. During the postoperative period, patients were asked about their symptoms with emphasis on dysphagia, regurgitation and heartburn. A barium oesophagogram was requested 2 weeks after surgery or whenever the patient complained of recurrent dysphagia or regurgitation. Facilities for oesophageal manometry and pH testing were not available. Patients were divided into 3 stages based on oesophageal diameter determined by oesophagogram, as previously described.<sup>13</sup> Oesophageal diameter was measured at the site of maximum oesophageal dilatation. Stage 1 was defined as <40 mm, stage 2 as 40 - 70 mm, and stage 3 disease as >70 mm. The diameter of the narrowed oesophageal segment was measured at the gastro-oesophageal junction.

The patients were resuscitated with appropriate fluid and electrolytes. Nutritional rehabilitation and correction of anaemia were also carried out. Chest infection was treated with antibiotics. Treatment was by modified Heller's operation, transabdominally without a complementary anti-reflux procedure. According to protocol, care was always

taken to avoid excessive posterior dissection and not to extend the myotomy more than 1 cm on the gastric end. Treatment was considered a failure when there was no improvement in dysphagia or there was an increase in maximum oesophageal diameter postoperatively. Information was obtained from patients' case notes, ward admission records and operation registers. This information was analysed for age, sex, symptoms, treatment and outcomes.

Data were entered into SPSS statistical software (version 13.0, SPSS, Chicago, IL). Data were reported as proportions, means  $\pm$  standard deviations (SD) or medians. Categorical variables and proportions were compared by Fisher's exact test. Wilcoxon's test was used to compare the preoperative and postoperative results of clinical (dysphagia, regurgitation and heartburn) and radiological evaluation. Logistic regression modelling was performed to identify independent preoperative factors significant for prediction of poor outcome. Factors included in the model were age, sex, severity of preoperative dysphagia, oesophageal dilatation and distal oesophageal narrowing. The level of significance was established at  $p < 0.05$ .

## Results

There were 47 patients, 31 (66.0%) males and 16 (34%) females. Their ages ranged from 16 - 58 years with a mean of  $34.6 \pm 9.8$  years. Patients <40 years constituted 72.3%. All patients had dysphagia at presentation (Table I). In 44 (93.6%) patients, dysphagia was experienced at every attempt at feeding. The severity of dysphagia before and after treatment is shown in Fig. 1. The duration of symptoms ranged from 9 to 132 months with a mean of  $37.6 \pm 1.5$  months. Twenty-one (44.7%) patients had had symptoms for more than 72 months.

Chest radiograph showed widened mediastinum and air-fluid levels in 38 (80.8%) patients. Barium swallow examination showed evidence of stasis and a dilated oesophageal body with a narrowed distal end in all patients. In 25 (53.2%) patients, aperistalsis of the oesophageal body was demonstrated on fluoroscopy. Two elderly patients underwent rigid oesophagoscopy and biopsy. Transabdominal ultrasonography did not reveal tumours in the oesophagogastric region in any patient. The maximum oesophageal diameter preoperatively was 34.0 - 89.0 mm with a mean of  $67.4 \pm 12.7$  mm. Stage 3 disease was found in 30 (63.8%) patients, while stages 2 and 1 disease were found in 11 (23.4%) and 6 (12.8%) patients, respectively. Only 18 patients had a postoperative barium swallow examination (Fig. 2). Other patients refused to repeat the barium study because they were relieved of symptoms and saw no need to incur additional expenses in this investigation. Postoperatively, the maximum oesophageal diameter recorded in 18 patients was 28.0 - 72.0 mm with a mean of  $37.5 \pm 8.2$  mm - significantly lower than preoperative values ( $p = 0.001$ ). The preoperative diameter of the narrowed oesophageal segment was 1.0 - 11.0 mm with a mean of  $4.6 \pm 2.5$  mm, compared with a mean of  $11.6 \pm 1.8$  mm postoperatively ( $p = 0.015$ ).

The oesophageal incision, recorded in 42 (89.4%) patients, ranged between 50.0 mm and 100 mm, with a mean of 80.0 mm. There were 4 (8.5%) perforations of the oesophageal mucosa, which were repaired immediately. Postoperative morbidity occurred in 5 (10.6%) patients, including 4 (8.5%) wound infections and 1 (2.1%) case of pneumonia. One patient died postoperatively - a 56-year-old man who had

TABLE I. SYMPTOMS AND SIGNS IN 47 PATIENTS

Symptoms	Preoperative		Postoperative	
	No.	%	No.	%
<b>Dysphagia</b>	<b>47</b>	<b>100</b>	<b>0</b>	<b>0.0</b>
<b>Regurgitation</b>	<b>33</b>	<b>70.2</b>	<b>0</b>	<b>0.0</b>
<b>Heartburn</b>	<b>12</b>	<b>25.5</b>	<b>4</b>	<b>8.5</b>
<b>Weight loss</b>	<b>10</b>	<b>21.3</b>	<b>2</b>	<b>4.2</b>
<b>Parotid swelling</b>	<b>5</b>	<b>10.6</b>	<b>2</b>	<b>4.2</b>
<b>Cough</b>	<b>4</b>	<b>8.5</b>	<b>0</b>	<b>0.0</b>

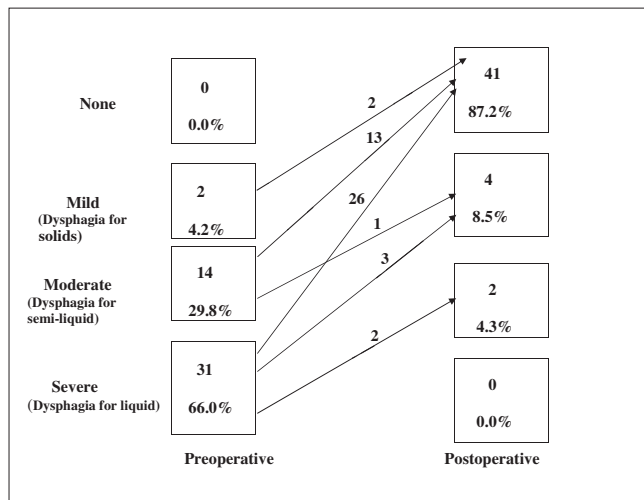


Fig. 1. Preoperative and postoperative evaluation of dysphagia in 47 patients.

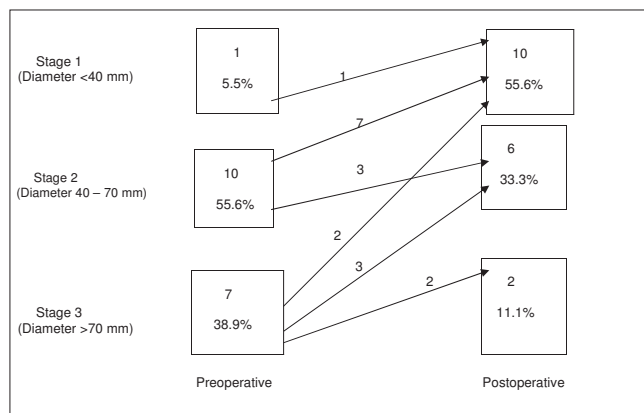


Fig. 2. Preoperative and postoperative oesophageal radiological evaluation in 18 patients.

had progressive dysphagia for 10 years. He was malnourished and had 2 previous admissions for bronchopneumonia, the last being 2 months before he presented at our hospital. His preoperative maximum oesophageal diameter was 82 mm. He had good relief of dysphagia postoperatively. He aspirated and died 1 week after surgery. In general, the duration of hospital stay was 7 - 18 days with a mean of 10 days.

Follow-up ranged between 2 weeks and 42 months with a median of 6 months. On discharge from hospital, 41 patients (87.2%;  $p < 0.001$ ) had complete relief of dysphagia, regurgitation and heartburn. Three (6.4%) additional patients had significant improvement of dysphagia. In 4 patients, heartburn persisted after operation, and they are being treated with antacids. Twenty-seven (57.5%) patients were seen 3 - 9 months after operation. All of them maintained

complete relief of dysphagia, regurgitation and heartburn as had been achieved at the time of discharge from hospital. Eight patients with preoperative weight loss had gained weight when seen 3 - 6 months after surgery.

Of the 6 patients with incomplete relief of dysphagia, 5 (83.0%) had severe preoperative dysphagia, while 26 (84.0%) of 31 patients with severe preoperative dysphagia had complete relief of symptoms postoperatively (likelihood ratio 4.5,  $p = 0.07$ ). The 6 patients with incomplete relief of dysphagia also had stage 3 (>70 mm) preoperative oesophageal dilatation, compared with 24 (80.0%) of 30 patients with stage 3 disease who had complete relief of symptoms (likelihood ratio 3.8,  $p = 0.25$ ). Using regression modelling, none of the selected variables attain statistical significance as a predictor of dysphagia after surgery. However, the likelihood of incomplete relief of symptoms was higher in patients with severe dysphagia, male patients and those with stage 3 preoperative oesophageal dilatation.

## Discussion

In developed countries, achalasia of the cardia is diagnosed manometrically by complete absence of primary peristalsis of the oesophageal body, failure of the LOS to relax, and elevated LOS pressure and pressurisation of the oesophagus, both in approximately 50% of cases.<sup>2,3,24</sup> In addition, barium swallow and 24-hour pH monitoring are always added to the diagnostic and therapeutic evaluations.<sup>24</sup> In our patients, diagnosis of achalasia was possible to a high degree of accuracy, given the symptom complex of longstanding dysphagia, regurgitation and weight loss together with barium swallow showing delayed emptying, dilatation of the oesophageal corpus and bird's beak-shape narrowed distal oesophagus.

Occasionally, difficulties are encountered in distinguishing primary from secondary achalasia, especially in elderly patients. In this as in another report, transabdominal ultrasonography was used to differentiate between normal oesophagogastric junction and functional or organic obstruction of the distal oesophagus,<sup>25</sup> as it provides information on oesophageal wall thickness and shows the contours of the distal oesophagus and its surroundings, which are important in determining organic obstruction of the oesophagogastric junction. The long duration of symptoms in our patients is probably attributable to the slow progression of the disease, some ability to push down the food by drinking a large amount of water, and absence of severe pain. In our patients as in others, parotid swelling indicated malnutrition.<sup>22,23</sup>

The most important outcome for the patient with achalasia is relief of dysphagia. Surgical myotomy is superior to pneumatic dilatation in providing long-term relief of dysphagia.<sup>8,26-28</sup> However, many physicians still favour pneumatic dilatation because laparotomy and thoracotomy are associated with more postoperative pain and morbidity and longer hospital stays. With the introduction of laparoscopic surgery, surgical myotomy has regained primacy in the treatment of achalasia.<sup>2,8,27</sup> In developing countries, facilities for laparoscopic surgery are limited, and access to reference centres and cost of treatment are still an issue. All our patients had open modified Heller's operation, as was the case in other reports from our sub-region.<sup>21-23</sup> We found the transabdominal approach quicker, simpler and less tasking to other supporting staff, especially during the early



postoperative period.<sup>21</sup> This route also allows the assessment and treatment of any concurrent intra-abdominal disease.<sup>29</sup> It is established that relief of dysphagia and regurgitation is dependent on the degree of relief of outflow obstruction. In our patients, relief of the distal oesophageal obstruction was evidenced by a significant decrease in the maximum oesophageal diameter ( $p=0.001$ ) and increased diameter of the most narrowed oesophageal segment ( $p=0.015$ ). These changes resulted in significant relief of dysphagia and regurgitation. In this as in other reports, a few patients remained with some degree of oesophageal dilatation, despite complete relief of symptoms.<sup>3,24</sup>

The need for and choice of antireflux procedure remains controversial. Previous studies have shown that good relief of dysphagia with low incidence of reflux symptoms can be achieved without additional antireflux procedures by avoiding excessive posterior dissection and limiting the myotomy to 0.5 - 1 cm onto the stomach.<sup>18,20,21</sup> This was the finding in our patients. However, recent studies have indicated that a Heller myotomy and Dor procedure should be the treatment of choice for achalasia<sup>14,17,27</sup> because it is associated with good relief of dysphagia and a low rate of GOR as determined by 24-hour pH monitoring. Suturing the gastric wall to the edges of the myotomy, according to the Dor technique, also maintains the edges of the myotomy open, thus preventing the consequences of scar tissue repair, and covers any undetected perforation of the oesophageal mucosa thereby preventing any significant postoperative morbidity.<sup>14,17</sup> Preoperative heartburn may be due to food stagnation and bacterial growth in the distal oesophagus, or fermentation of retained food,<sup>30</sup> which improves with improved emptying of the oesophagus. None of our patients developed new-onset heartburn in the postoperative period. However, this does not exclude GOR, which may be asymptomatic in about a third of patients.<sup>30</sup>

Among the various preoperative factors, LOS pressure, severe dysphagia and oesophageal dilatation have been shown to have some correlation with treatment outcome.<sup>2,21</sup> In the present study, none of the evaluated factors have statistically significant correlations with treatment outcomes. This agrees with other reports following oesophagomyotomy.<sup>2,27,30</sup> Reports following laparoscopic cardiomyotomy have shown that only preoperative LOS pressure has significant correlation with outcome of treatment.<sup>18,31</sup> However, in our patients, the likelihood of poor outcome was higher in severe dysphagia, male patients and those with stage 3 oesophageal dilatation.

The retrospective nature of our data may be considered a limitation of this study. In addition, lack of long-term follow-up may preclude detection of long-term outcome measures including recurrence of dysphagia, regurgitation or heartburn. However, symptom relief obtained at 6 months was sustained during long-term follow-up in the majority of patients.<sup>3,8,23</sup> Lack of pH and manometric evaluations was also a limitation.

In conclusion, achalasia is rare in our environment, where diagnostic and therapeutic facilities are limited. However, it can be accurately diagnosed with a symptom complex of longstanding progressive dysphagia, regurgitation and weight loss, and a timed barium swallow examination. A modified Heller's operation will provide lasting relief of symptoms and improved oesophageal morphology in most patients. However, patients with severe preoperative dysphagia or

stage 3 oesophageal dilatation may have a greater chance of incomplete relief of symptoms following myotomy.

## REFERENCES

- Orville F, Grima H, Brodi S, Alexander R, Margulis S. Achalasia of the oesophagus. *Am J Surg* 1970; 100: 198-202.
- Yashodhan SK, Shalini K, Amy EBL, et al. Laparoscopic Heller myotomy with Toupet fundoplication. *Arch Surg* 2005; 140: 827-834.
- Gockel I, Bohl JR, Doostkam S, Eckardt VF, Junginger T. Spectrum of histopathological findings in patients with achalasia reflects different aetiologies. *J Gastroenterol Hepatol* 2006; 21: 727-733.
- Kim HJ, Rhee P, Lee SS, et al. Is peristalsis with complete lower oesophageal sphincter relaxation an early stage of classic achalasia? *Gastroenterology* 2007; 22: 536-541.
- Sachdev A, Sandhu BS, D'cruz S, Lehl SS, Agarwal V. Achalasia cardia in mother and son. *Indian J Gastroenterol* 2004; 23: 109.
- Mayberry JF. Epidemiology and demographics of achalasia. *Gastrointest Endosc Clin North Am* 2001; 11: 235-248.
- Ho KY, Tay HH, Kang JY. A prospective study of the clinical features, manometric findings, incidence and prevalence of achalasia in Singapore. *J Gastrointest Hepatol* 1999; 14: 791-795.
- Cheng YS, Li MH, Chen WX, Chen NW, Zhuang QX, Shang KZ. Selection and evaluation of three interventional procedures for achalasia based on long-term follow-up. *World J Gastroenterol* 2003; 9: 2370-2373.
- Kostic S, Kjellin A, Ruth M, et al. Pneumatic dilatation or laparoscopic cardiomyotomy in the management of newly diagnosed idiopathic achalasia: results of a randomized control trial. *World J Surg* 2007; 31: 470-478.
- Ghosh B, Das SK. Botulinum toxin: a dreaded toxin for use in human beings. *J Indian Med Assoc* 2002; 100: 607-608.
- Vela MF, Ritcher JE, Wachsberger D, Cannon J, Rice TW. Complexities of managing achalasia at a tertiary referral centre: use of pneumatic dilatation, Heller myotomy and botulinum toxin injection. *Am J Gastroenterol* 2004; 99: 1029-1036.
- Lopushinsky SR, Urbach DR. Pneumatic dilatation and surgical myotomy for achalasia. *JAMA* 2006; 296: 2227-2233.
- Onopriev VI, Durlsheter VM, Ryabchun VV. Comparative pre- and postoperative results analysis of functional state of the oesophagus assessment in patients with various stages of achalasia. *Eur J Cardiothorac Surg* 2005; 28: 1-6.
- Youssef Y, Richards WO, Sharp K, et al. Relief of dysphagia after laparoscopic Heller myotomy improves long-term quality of life. *J Gastrointest Surg* 2007; 11: 309-313.
- Heller E. Extramukose cardioplastik beim chronischen cardiospasmus mit dilatation des oesophagus. *Mitt Grenzgeb Med Chir* 1913; 27: 147-149.
- Zaaijer JH. Cardiospasm in the aged. *Ann Surg* 1923; 77: 615-617.
- Porziella V, Cesario A, Granone P. Dor fundoplication after myotomy for achalasia: useful, unnecessary, or harmful? *J Thorac Cardiovasc Surg* 2006; 132: 216-217.
- Arvelaskis A, Karavokyros I, Rastounis E. Laparoscopic oesophagomyotomy for achalasia without complementary antireflux procedure. *J Laparosc Endosc Adv Surg Tech* 2006; 16: 345-349.
- Raiss M, Hroza A, Menfaa M, et al. Heller myotomy without fundoplication: a series of 123 patients. *Ann Chir* 2002; 127: 771-775.
- Ellis FH, Crozier RE, Watkins E. Operation for oesophageal achalasia. Results of oesophagomyotomy without an antireflux operation. *J Thorac Cardiovasc Surg* 1984; 88: 334-351.
- Nmadu PT. Achalasia of the oesophagus. *Nig J Surg Sci* 1993; 3: 8-11.
- Adebo OA, Grillo IA, Osinowo O, Adebajo SA, Lewis EA. Oesophagotomy for achalasia of the oesophagus. Experience at the University College Hospital Ibadan. *East Afr Med J* 1980; 57: 390-398.
- Mbembati NAA, Lema LEK, Kahamba JF, Mcharo ONM. Operative management of achalasia of the oesophagus. *East Afr Med J* 1994; 71: 421-423.
- Andersson M, Kostic S, Ruth M, et al. Characteristics of timed barium oesophagogram in newly diagnosed idiopathic achalasia: clinical and manometric correlates. *Acta Radiol* 2007; 48: 2-9.
- Eckardt VF, Schmitt T, Kanzler G. Transabdominal ultrasonography in achalasia. *Scand J Gastroenterol* 2004; 39: 634-637.
- Zaninotto G, Annese V, Costantini M, et al. Randomised control trial of botulinum toxin versus laparoscopic Heller myotomy for oesophageal achalasia. *Gastroenterology* 2004; 127: 1850-1852.
- Torquati A, Richards WO, Holzman MD, Sharp KW. Laparoscopic myotomy for achalasia. Predictors of successful outcome after 200 cases. *Ann Surg* 2006; 243: 587-593.
- Gerson LB. Pneumatic dilatation or myotomy for achalasia? *Gastroenterology* 2007; 132: 811-813.
- Garba ES. Achalasia cardia and gastric outlet stenosis in a postmenopausal woman: case report. *East Afr Med J* 2003; 80: 165-166.
- Crookes PF, Corkill S, De Meester TR. Gastroesophageal reflux in achalasia: when is 'reflux' really reflux? *Dig Dis Sci* 1997; 42: 1354-1361.
- Tsiaooussi J, Athanasakis E, Pecchivanides G, et al. Long-term results after laparoscopic surgery for oesophageal achalasia. *Am J Surg* 2007; 193: 26-31.