

Pulmonary hydatidosis: Still unrecognised in endemic regions – a 10-year review

M Ndlovu, MB ChB; S A Thula, FcPaed; R E M Mphahlele; MB ChB; R Masekela, PhD

Department of Maternal and Child Health, Inkosi Albert Luthuli Central Hospital, and College of Health Sciences, Nelson R Mandela School of Medicine, University of KwaZulu-Natal, Durban, South Africa

Corresponding author: M Ndlovu (meendlovu@gmail.com)

Background. Echinococcus disease is still endemic in many low-middle-income countries, with 1 million people infected at any one time. Surgery, the mainstay of its treatment, is costly.

Objectives. To describe the presentation, clinical features and outcomes of children referred with pulmonary hydatid disease at Inkosi Albert Luthuli Central Hospital in Durban, South Africa.

Methods. A 10-year review of children with pulmonary hydatid disease at Inkosi Albert Luthuli Hospital was carried out. The data collected were demographic, clinical, laboratory and radiological. Cases were mapped geographically to analyse for clustering of cases. Spearman's correlation was used to assess for correlations between laboratory markers.

Results. A total of 24 subjects, 75% of whom were male, were included. The mean (standard deviation) age at diagnosis was 8.9 (3.4) years. The mean delay in diagnosis was 5.8 (5.7) months. Of the subjects, 15 (71.4%) were from the Eastern Cape and 9 from KwaZulu-Natal provinces. Seventy-nine percent of the patients had been exposed to dogs, while 8% reported exposure to either sheep or cattle. There was right-sided preponderance, with 11 right- and 7 left-sided cysts; 6 patients had bilateral cysts, and 4 associated extrapulmonary cysts. Indirect haemagglutination assay was positive in 70%, and blood eosinophilia was present in 45% of the subjects, with no correlation between the two markers ($p=0.22$). Surgery was the only modality of treatment in 18 (75%) subjects, while 5 had had prior medical therapy for disseminated disease. The mean intensive care stay postoperatively was 2 (2) days with no mortality.

Conclusion. Despite exposure to known risk factors and living in endemic regions, there is often a significant delay in diagnosis of pulmonary hydatid disease at Inkosi Albert Luthuli Hospital.

S Afr J Child Health 2018;12(2):47-50. DOI:10.7196/SAJCH.2018.v12i2.1433

Human hydatid disease, or cystic echinococcosis (CE), is a worldwide health problem, especially in regions where dogs, sheep and cattle are common livestock, such as South America, Australia, India, the Middle East, sub-Saharan Africa and the Mediterranean countries, including Turkey.^[1-4] The World Health Organization states that over 1 million individuals are infected with echinococcus worldwide annually.^[5] The epidemiology of CE is poorly understood in South Africa (SA). A retrospective data analysis of the National Health Laboratory Service (NHLS) information system on echinococcosis serology, microscopy and histopathology results in eight provinces (excluding KwaZulu-Natal) showed an overall positivity rate in submitted diagnostic samples of 17.0% (1056/6211). The Eastern Cape (30.4%), North West (19.0%) and Northern Cape (18.0%) provinces showed the highest rates.^[6] The risk factors proposed in the literature are rural background, farming community, low socioeconomic status, cattle rearing, ineffective veterinary care, lack of potable water supply and male sex.^[5,7]

Traditionally four species of *Echinococcus* have been recognised. *E. granulosus* and *E. multilocularis* are the most important forms in humans, and they cause cystic and alveolar echinococcosis, respectively. Two additional species have been identified: *E. shiquicus* and *E. felidis*, but their zoonotic transmission potential is unknown.^[8] Humans acquire infection by accidentally ingesting tapeworm eggs eliminated from dogs infected with *E. granulosus*, which has a lifecycle that includes dogs and sheep.^[2,9,10] The tapeworm of *E. granulosus* lives in the intestine of dogs, which are the definitive hosts. Eggs are passed with faeces by dogs, and are ingested by intermediate hosts (usually sheep, goats, swine, cattle, horses and camels); the eggs hatch in the small bowel and release oncospheres that penetrate the intestinal wall and migrate through the circulatory system into various organs, especially the liver and

lungs. In these organs, the oncospheres develop into cysts that enlarge gradually, producing protoscolices and daughter cysts that fill the cyst interior. The definitive host becomes infected when it ingests the cyst-containing organs of the infected intermediate host, following which protoscolices evaginate and attach to the intestinal mucosa of the definitive host before they develop into adult stages in 32 - 80 days.

Hydatid disease most frequently involves the parenchyma of the liver (55% - 75%); however, some parasites escape through the microvascular barrier and reach the lungs (15% - 40%).^[11] In children it classically involves the liver, lungs and brain, but can involve almost any organ, and numerous organs simultaneously.^[12] The lungs are the most common organ infected by the larval form of *Echinococcus* in children.^[3,9] In a study in Uruguay comparing the prevalence of pulmonary cystic disease in adults and children, 70% of children and 25% of adults had pulmonary cysts.^[8] The majority of adults (72%) had liver cysts.^[8] In children, the lung allows faster growth of cysts, owing to its compressible nature, vascularisation and negative pressure.^[3,9] Several studies have indicated that major symptoms of pulmonary hydatidosis are related to the mass effect from the cyst volume, and they include cough, fever, chest pain, dyspnoea, mucopurulent sputum and haemoptysis.^[13] The principal complication is cyst rupture and resultant spillage of protoscolices into the bronchial tree, producing cough and haemoptysis. Rupture into pleural space produces pleural effusion and empyema.^[3] Management depends on cyst location, cyst size and number of cysts, and can include antihelminths or surgical removal, or a combination of the two modalities.

There is limited data on pulmonary hydatid disease in a paediatric population in SA and Africa in general, with local studies limited to laboratory studies. Furthermore, a large amount of the literature

focuses on uncomplicated cases that were managed conservatively with benzimidazoles. The aim of this study, therefore, is to describe the epidemiology, clinical presentation and outcomes of paediatric pulmonary hydatid disease of children referred to a quaternary hospital in KwaZulu Natal.

Methods

A 10-year retrospective chart review of patients <18 years of age who were referred to Inkosi Albert Luthuli Central Hospital in Durban, SA, with pulmonary echinococcus cysts was conducted. This is a quaternary hospital accepting referrals from the KwaZulu Natal (KZN) and Eastern Cape (EC) provinces for paediatric pulmonology and cardiothoracic management. According to the Children's Institute,^[13] the public healthcare systems of the two provinces each serve large populations of children living in rural areas (2.47 million and 1.66 million in KZN and EC, respectively). These account for 60% and 63% of children living in these two provinces, respectively. The study period was between June 2006 and June 2016.

Electronic medical-record data were collected for all participants. The demographic data collected were the age, gender and geographic location of subjects. The clinical data encompassed age at presentation, presenting symptoms (presence and duration of cough, haemoptysis and chest pain), age at diagnosis, time from symptoms to diagnosis and number and location of cysts. Data on exposure to animals and management modalities were also collected.

Laboratory investigations comprised of full blood count, specifically noting for the presence or absence of eosinophilia. Additionally, a blood indirect haemagglutination assay (IHA) for *Echinococcus* was used and serum *Echinococcus* IgG assay test was utilised.

Data were analysed using Stata version 13.0 software (StataCorp, USA). Descriptive analysis was employed to analyse demographic data (age, gender and geographical location), clinical characteristics (delay in diagnosis, exposure to animals and management) and laboratory investigations (blood IHA and blood eosinophilia). Spearman's correlation was used to analyse the relationship between blood eosinophil count and blood indirect haemagglutination assays.

Full ethical approval was granted by the Biomedical Research Ethics Committee of the University of KwaZulu-Natal (ref. no. IRB BE 353/16).

Results

A total of 24 participants met the inclusion criteria, of whom 18 (75%) were males. All the subjects were black African children. The mean (standard deviation) age at diagnosis of hydatid disease was 8.9 (3.4) years, with a range of 3.0 - 16.0 years (Table 1). There was a delay of 5.8 (5.7) months between first presentation of lung disease and actual diagnosis of pulmonary hydatid disease. Of the patients, 79% reported exposure to dogs, while 8% had been exposed to sheep and cattle. Exposure for the remaining 13% was unknown. Five children (22%) received antituberculosis therapy owing to the clinical and radiological changes observed at the primary healthcare centres prior to referral to a higher level of care.

Eleven patients had right-sided cysts, while 7 had cysts on the left (Table 2). Six patients had bilateral disease, and 4 had additional cysts in the liver, spleen or orbit. Overall, 70% had positive IHA for *Echinococcus*, and blood eosinophilia was present in 45% of the subjects. This gives a positive predictive value of 0.7. There was no significant correlation between IHA and eosinophilia ($p=0.22$).

With regards to treatment, all subjects received albendazole 20 mg/kg, as a daily dose or as a twice-daily divided dose, both pre- and postoperatively (Table 1). Surgical enucleation was performed in 75% of the cases. A conservative approach using albendazole only was adopted for patients who had multiple pulmonary cysts and/or cysts in multiple sites. Of the four patients with disseminated disease, two were lost to follow-up, one had persistence of cysts in the

spleen and one improved following enucleation and percutaneous drainage of liver cysts. Postoperatively, 67% of the patients were admitted to the intensive care unit (ICU), with an ICU stay of 2 (2) days. Four patients required invasive positive pressure ventilation for an average of 2 days while in ICU. The mean hospital stay was 20 (13.8) days, with the majority of subjects having a prolonged hospital stay. There were no deaths reported.

With respect to geographical location, 63% of the patients were from the EC, with the majority from Mthatha (50%). The nearby areas, Libode and Tsolo contributed 8% and 5%, respectively (Fig. 1 shows numerical distribution; Fig. 2 shows geographical location in EC). The remaining 37% were from various parts of rural KZN: Empangeni, Vryheid and Ladysmith.

Discussion

Hydatid disease remains a significant cause of morbidity in SA, but very little is known about the true epidemiology of pulmonary hydatid disease in children in SA. This study revealed a male predominance and geographical clustering of cases, particularly in the north-eastern region of the Eastern Cape. There was a delay in diagnosis of pulmonary hydatid cysts in most cases, with a mean delay of 5.8 months. Despite the delay, there was a successful outcome in all patients, although 71% required surgical intervention. Laboratory markers, particularly the *Echinococcus* IgG assay, were poor screening tools for the diagnosis of pulmonary hydatid disease.

Table 1. Demographic and clinical data of children with hydatid cysts (N=24)

Variable	Mean (SD)
Age (years)	8.9 (3.4)
Gender (M/F)	18/6
Delay in diagnosis (months)	5.8 (5.7)
Cysts, <i>n</i>	1.5 (0.7)
Days in ICU, <i>n</i>	2.0 (2.0)

ICU = intensive care unit.

Table 2. Anatomical location of hydatid cysts, and frequency (N=24)

Location of cyst	Frequency, <i>n</i>
Right upper lobe	5
Right middle lobe	2
Right lower lobe	4
Left upper lobe	2
Left lower lobe	5
Bilateral	6
Extrapulmonary	4

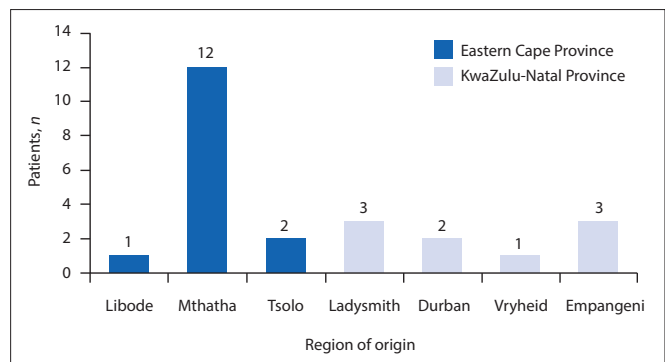


Fig. 1. Geographical origin of children with pulmonary hydatid cysts (N=24).

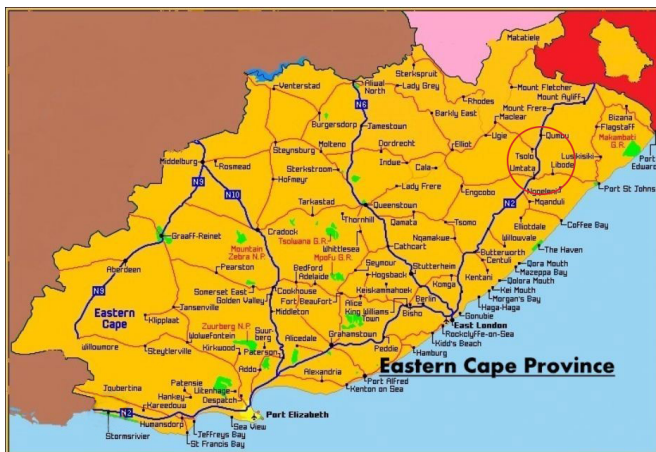

Fig. 2. Geographical distribution showing clustering of cases in the Eastern Cape Province (red circle).

In a Turkish report of 100 pulmonary hydatidosis cases, the largest group comprised of school-aged children aged 3 - 9 years.^[2] In our study, the age distribution was comparable. In another Turkish study, the children were found to be older, with a mean age of 10.2 (3.9) years.^[14] The number of males with hydatid cysts exceeded that of females at a ratio of 6:1. This male predominance has been noted in previous studies.^[11,15-17] In one study, the male prevalence was 76%.^[15] This may be related to traditional practices wherein the rearing of livestock is left to males, especially young boys. The risk factors for hydatid disease are well known, and include exposure to animals such as dogs, sheep, cats and cattle. In the current study the subjects reported exposure mainly to dogs, sheep and cattle.

With regard to geographical distribution, more than 90% of our patients were from the rural parts of the EC and KZN provinces, and this is in keeping with studies from Eastern European countries, where most of the patients were from rural settings.^[18] Interestingly, most of our patients were from three parts of the Eastern Cape, namely Mthatha, Tsolo and Libode, which are in close proximity to each other. This demonstrates the clustering found in the current study.

However, a number of other studies have documented hydatid cysts in urban populations. One such study by Anadol *et al.*,^[2] showed an equal distribution between urban and rural children.^[2] Visits and migration from urban to rural areas may explain the cases of hydatid disease in urban areas. Two of the patients in the current study were children who reside in Durban, an urban setting.

Our study revealed that the diagnosis of hydatid disease at primary healthcare level was often delayed by about 6 months. This may be attributed to the fact that healthcare workers at that level are not familiar with pulmonary hydatid disease. Twenty-two percent of the patients had a trial of TB treatment for their symptoms, prior to referral to a tertiary hospital. In countries where cystic hydatid disease is endemic, neither the frequency or duration of delays in diagnosis is documented. The definitive diagnosis of pulmonary hydatid disease is made through radiological and serological investigations. In the current study the IHA for *Echinococcus* had a low positive predictive value. Previous studies have shown that serology has a low specificity. Eosinophilia may or may not be present; in this study 45% had positive eosinophilia. Newer tests such as counter-immunoelectrophoresis and an enzyme-linked immunosorbant assay that have high sensitivities should be utilised, both for follow-up and as screening tests.^[2] However, the NHLS in KwaZulu Natal does not offer the newer tests, owing to cost constraints.

The anatomical location of cysts favoured the right lung, which was more frequently affected than the left lung, and this finding is supported by those of other studies.^[11,14,18] A study in Turkey revealed equal distribution of cysts between the right and left lung.^[16] In a 10-year

Turkish review of 33 patients with pulmonary hydatidosis, 10 patients also had cysts in other organs, namely the liver, brain and spleen.^[15] In our study, 4 patients had additional cysts in the liver, spleen or orbit.

The management of >70% of our patients involved surgical enucleation of cysts. Posterolateral thoracotomy for the lung cysts was used as the approach, and this replicated the results in many studies.^[3,12,17,19] In one study patients with bilateral lung involvement had a second thoracotomy 6 - 8 weeks after the initial one.^[19] All the patients in this present study received albendazole 20 mg/kg/day, both pre- and postoperatively. Previous studies have demonstrated that low doses and short courses of albendazole are not effective in treating hydatid disease. In a small study by Aggarwal *et al.*,^[20] albendazole at a dose of 10 mg/kg/day for 8 weeks was ineffective in the treatment of hydatid disease of the lung. The adverse effects of albendazole are few and tend to be mild, and although gastrointestinal upset, dizziness, rash and/or alopecia can occur, these side-effects do not warrant discontinuation of the drug.^[21] According to Brahim *et al.*,^[21] cysts that do not show any signs of radiographic involution must be treated for at least 18 months for pulmonary cysts, and 3 years for hepatic cysts, for good results. Two-thirds of subjects in the current study required postoperative ICU admission, with an average ICU stay of 2.6 days. This resource may not be available in many low-middle-income countries, but no subjects required invasive ventilation, suggesting that access to high care facilities may be sufficient in most cases where technologically complex ventilation is not possible. There was no mortality in this study, and this is comparable with the results of other studies.^[17,19]

A strength of this study is that we analysed data on pulmonary hydatid disease in children from two rural provinces in South Africa, which has not been studied before. The limitations of the study are its retrospective nature and the small number of patients. Larger studies are required to validate the findings.

Conclusion

In conclusion, despite exposure to risk factors and living in endemic regions, there is a significant delay in diagnosis of pulmonary hydatid disease.

The indication of geographic clustering in parts of the Eastern Cape Province signals a need to improve feedback to healthcare providers to maintain a high index of suspicion in school-age boys presenting with chronic respiratory complaints in the region. Prevention and control strategies need to be implemented to eradicate hydatid disease in this region. Health education of communities and primary healthcare workers is essential, to enable timely diagnosis and referral to healthcare centres capable of treating pulmonary hydatid disease. An over-reliance on a serology test as a rule-out test needs to be de-emphasised.

Acknowledgements. The authors wish to thank the department of cardiothoracic surgery and the paediatric intensive care unit at Inkosi Albert Luthuli Central Hospital for their assistance with management of the cases.

Author contributions. MN: Data acquisition, analysis and interpretation, drafting of manuscript. ST: Acquisition of data, revision. REMM: Study conception and design, critical revision. RM: Study topic, conception and design, analysis and interpretation of data, critical revision and overall supervision.

Funding. None.

Conflicts of interest. None.

- Aslanabadi S, Zarrintan S, Abdoli-Oskouei S, et al. Hydatid cyst in children: A 10-year experience from Iran. *Afr J Paediatr Surg* 2013;10(2):140-144. <https://doi.org/10.4103/0189-6725.115040>
- Anadol D, Göçmen A, Kiper N, Özçelik U. Hydatid disease in childhood: A retrospective analysis of 376 cases. *Pediatr Pulmonol* 1998;26(3):190-196. [https://doi.org/10.1002/\(SICI\)1099-0496\(199809\)26:3<190::AID-PPUL6>3.0.CO;2-P](https://doi.org/10.1002/(SICI)1099-0496(199809)26:3<190::AID-PPUL6>3.0.CO;2-P)

3. Santivanez S, Garcia HH. Pulmonary cystic echinococcosis. *Curr Opin Pulm Med* 2010;16(3):257-261. <https://doi.org/10.4103/0189-6725.11504010.1097/MCP.0b013e3283386282>
4. Jordanova DP, Harizanov RN, Kaftandjiev IT, Rainova IG, Kantardjiev TV. Cystic echinococcosis in Bulgaria 1996 - 2013, with emphasis on childhood infections. *Eur J Clin Microbiol Inf Dis* 2015;34(7):1423-1428. <https://doi.org/10.1007/s10096-015-2368-z>
5. World Health Organization. Echinococcus Fact Sheet. Geneva: WHO, 2018. <http://www.who.int/mediacentre/factsheets/fs377/en/> (accessed 18 February 2017).
6. Mogoye B, Menezes CN, Grobusch MP, Walers K, Frean J. Human cystic echinococcosis in South Africa 2014. *Onderstepoort J Vet Res* 2012;79(2):1. <https://doi.org/10.4102/ojvr.v79i2.469>
7. Gupta R, Sharma SB, Prabhakar G, Mathur P. Hydatid disease in children: Our experience. *Formosan J Surg* 2014;47(6):211-220. <https://doi.org/10.1016/j.fjs.2014.12.001>
8. Moro P, Schantz PM. Echinococcosis: A review. *Int J Infect Dis* 2009;13(2):125-133. <https://doi.org/10.1016/j.ijid.2008.03.037>
9. Sakamoto T, Gutierrez C. Pulmonary complications of cystic echinococcosis in children in Uruguay. *Pathol Int* 2005;55(8):497-503. <https://doi.org/10.1111/j.1440-1827.2005.01859.x>
10. Kurkcuoglu IC, Eroglu A, Karaoglanoglu N, Turkyilmaz A, Tekinbas C, Basoglu A. Surgical approach of pulmonary hydatidosis in childhood. *Int J Clin Pract* 2005;59(2):168-172. <https://doi.org/10.1111/j.1742-1241.2004.00275.x>
11. Cevik M, Boleken ME, Kurkcuoglu IC, Eser I, Dorterler ME. Pulmonary hydatid disease is difficult recognized in children. *Pediatr Surg Int* 2014;30(7):737-741. <https://doi.org/10.1007/s00383-014-3514-x>
12. Andronikou S, Welman CJ, Kader E. Classic and unusual appearances of hydatid disease in children. *Pediatr Radiol* 2002;32(11):817-828. <https://doi.org/10.1007/s00247-002-0785-5>
13. Hall K, Meintjes H, Sambu W. Demography of South Africa's children. *South African Child Gauge*. Cape Town: Children's Institute, 2014.
14. Koca T, Dereci S, Gençer A, et al. Cystic Echinococcosis in childhood: Five years of experience from a single center. *Turk Soc Parasitol* 2016;40(1):26-31. <https://doi.org/10.5152/tpd.2016.4381>
15. Rebhandl W, Turnbull J, Felberbauer FX, et al. Pulmonary echinococcosis (hydatidosis) in children: Results of surgical treatment. *Pediatr Pulmonol* 1999;27(5):336-340. <https://doi.org/10.3347%2Fkjp.2009.47.4.427>
16. Todorov T, Boeva V. Echinococcosis in children and adolescents in Bulgaria: A comparative study. *Ann Trop Med Parasitol* 2000;94(2):135-144. [https://doi.org/10.1016/S1010-7940\(01\)01140-X](https://doi.org/10.1016/S1010-7940(01)01140-X)
17. Dincer SI, Demir A, Sayar A, Gunluoglu MZ, Kara HV, Gurses A. Surgical treatment of pulmonary hydatid disease: A comparison of children and adults. *J Pediatr A Surg* 2006;41(7):1230-1236. <https://doi.org/10.1016/j.jpedsurg.2006.03.053>
18. Djuricic SM, Grebeldinger S, Kafka DI, Djan I, Vukadin M, Vasiljevic ZV. Cystic echinococcosis in children – the seventeen-year experience of two large medical centers in Serbia. *Parasitol Int* 2010;59(2):257-261. <https://doi.org/10.1016/j.parint.2010.02.011>
19. Turkyilmaz Z, Sonmez K, Karabulut R, et al. Conservative surgery for treatment of hydatid cysts in children. *World J Surg* 2004;28(6):597-601. <https://doi.org/10.1007/s00268-004-7029-9>
20. Aggarwal P, Wali JP. Albendazole in the treatment of pulmonary echinococcosis. *Thorax* 1991;46(8):599-600. <https://doi.org/10.1136/thx.46.8.599>
21. Ben Brahim M, Nouri A, Ksia A, et al. Management of multiple echinococcosis in childhood with albendazole and surgery. *J Pediatr Surg* 2008;43(11):2024-2030. <https://doi.org/10.1016/j.jpedsurg.2008.04.024>

Accepted 12 September 2017.