

Effects of *Bacillus subtilis* on performance, immune system and gut in Salmonella-challenged broilers

A. Sikandar^{1#}, H. Zaneb², A. Nasir³, M. Adil¹, H. M. Ali⁴, N. Muhammad¹, T. Rehman⁴,
A. Rehman⁵ & H. F. Rehman²

¹Department of Basic Sciences, College of Veterinary and Animal Sciences (CVAS), Jhang, sub-campus, University of Veterinary and Animal Sciences (UVAS), Lahore, 35200, Pakistan

²Department of Anatomy and Histology, UVAS, 54000, Lahore, Pakistan

³Department of Clinical Sciences, CVAS, Jhang, sub-campus, UVAS, Lahore, 35200, Pakistan

⁴University College of Veterinary and Animal Sciences, The Islamia University of Bahawalpur - 63100, Pakistan

⁵Department of Pathobiology, CVAS, Jhang, sub-campus, UVAS, Lahore, 35200, Pakistan

(Submitted 25 January 2020; Accepted 18 September 2020; Published 9 October 2020)

Copyright resides with the authors in terms of the Creative Commons Attribution 4.0 South African Licence.

See: <http://creativecommons.org/licenses/by/4.0/za>

Condition of use: The user may copy, distribute, transmit and adapt the work, but must recognise the authors and the South African Journal of Animal Science.

Abstract

The goal of this study was to compare the effects of *Bacillus subtilis* and the antibiotic enrofloxacin on growth performance, immune response, intestinal histomorphometry and cecal *Salmonella* numbers in broilers challenged with *S. gallinarum*. *Salmonella*-free chicks (n = 240) were allocated to four groups, comprising six replicates (n = 10) each. Group NN was not infected and received no treatment. Group SN was infected with *Salmonella* and received no treatment. Group SE was infected with *Salmonella* and treated with the antibiotic enrofloxacin. Group SP was infected with *Salmonella* and treated orally with the probiotic *B. subtilis*. Initially the groups that were infected with *Salmonella* had reduced growth performance compared with NN. By the fourth week, SE and SP had recovered and weighed as much as or more than NN. The SP group had greater cellular immunity and relative weights of the bursa and thymus than the other groups. SN had the lowest villus height in all the segments of the small intestine and a larger *Salmonella* population in the ceca. Probiotic supplementation reduced the pathological outcomes more than enrofloxacin. Prophylactic use of *B. subtilis*-type probiotics had similar effects to the use of antibiotics, alleviated the stress related to infection of *S. gallinarum*, and improved the growth performance, immune function, and gut mucosal development in broilers.

Keywords: growth promoters, immunity, probiotics, poultry villi length

[#]Corresponding author: e-mail: arbab.sikandar@uvas.edu.pk

Introduction

Salmonellosis is one of the leading causes of lost productivity in poultry (Saleem *et al.*, 2016) and a major source of bacterial food poisoning in humans. Antibiotics, including enrofloxacin, have shown promising efficacy *in vitro* against the bacterium, and enhance the growth performance of poultry (Xie *et al.*, 2017). Nevertheless, the European Union (EU) withdrew the use of antibiotics in food animals to circumvent the emergence of resistant pathogenic organisms and their transmission to humans through the consumption of contaminated food (Dersjant-Li *et al.*, 2014). This prohibition led to a decline in animal performance from bacterial stress and reduced growth. Consequently, probiotics (Yang *et al.*, 2018), organic acids (Arbab *et al.*, 2017), enzymes (Dersjant-Li *et al.*, 2016), and medicinal plants (Yasmin *et al.*, 2019) are regarded as replacements for antibiotics to enhance the production of poultry.

Probiotics are living cultures of microorganisms that are intended to have health benefits when consumed. *B. subtilis* is a probiotic that is an effective growth promoter and is capable of enhancing production and improving the innate immune response of broiler chickens (Lee *et al.*, 2015; Tarradas *et al.*, 2020). *B. subtilis* produces antimicrobial substances and is assumed to facilitate gut health (Sikandar *et al.*, 2017; Abudabos *et al.*, 2019). It favours the growth of lactic acid, producing bacteria and other beneficial microorganisms in the gut that act to competitively exclude pathogens (Yang *et al.*, 2018). However, there is a shortage of information about the protective effect of *B. subtilis* (QST-713) on the gut histology of and other

health benefits for broilers infected with Salmonella pathogens. Therefore, the goal of the current research was to evaluate the potential effects of *B. subtilis* on growth, gut morphology and the immune system response in broiler chickens challenged with *S. gallinarum*.

Materials and Methods

Procedures and protocols used in this study were approved by the Ethical Review Committee for Use of Laboratory Animals of the University of Veterinary and Animal Sciences, Lahore (Notification No. DR/257). Pathogen-free day-old male Hubbard broiler chicks (M77) from Big Bird Group (Lahore, Pakistan) of approximately equal weight ($n = 240$) were randomly divided into four groups, each comprising six replicates of ten chicks. Group NN was not infected and received no treatment. Group SN was infected with Salmonella and received no treatment. Group SE was infected with Salmonella and treated with the antibiotic enrofloxacin. Group SP was infected with Salmonella and treated orally with the probiotic *B. subtilis*. The birds that were assigned to the infected groups were given the Salmonella orally. The groups were housed separately in environmentally controlled closed poultry units that had been disinfected before the arrival of the chicks. The basal diets for the initial (1 to 21 days) and finishing (22 to 35 days) phases were as described by Sikandar *et al.* (2017). These diets were autoclaved at 120 °C for 15 minutes when each batch of feed was prepared. Minerals, vitamins, amino acids, probiotics, and organic acid were added to each batch, which was then mixed for 10 minutes. Husbandry practices and the biosecurity measures were optimized during the experiment. Feed, in mash form, and water were provided ad libitum. All the birds were monitored for general health conditions and behavioral alterations thrice a day throughout the trial.

Before the start of the experiment, three birds were randomly selected and killed to collect their cecal tonsils. The organs were removed aseptically and put in test tubes containing 10 ml tetra-thionate broth and kept overnight in the incubator at 37 °C. The samples were then plated on brilliant green agar (CM0263, Thermo Fisher Scientific Inc., Waltham, Massachusetts, USA) and again incubated overnight at 37 °C. These plates were then observed for the presence or absence of Salmonella infection in the birds.

A local isolate of *S. gallinarum* (isolated from poultry gut) and maintained at the University Diagnostic Laboratory (ISO certified) was used in the current study. The organism was retrieved on MacConkey broth from a freeze-dried culture of Salmonella seed and then transferred to Salmonella Shigella agar (SS agar) for purification. The culture was then incubated overnight at 37 °C in Tryptone Soya Broth (Thermo Fisher Scientific Inc., Waltham, Massachusetts, USA) prior to inoculation in the chicks. The infection was introduced in chicks at day 3 via oral gavage at the rate of 0.2 ml suspension of *S. gallinarum* per bird, which contained approximately 10^7 cfu/chick. The NN group was administered the same amount of sterile buffered peptone water (Sigma-Aldrich Inc., St. Louis, Missouri, USA).

The birds in SP were treated continuously with *B. subtilis* QST-713 (Agraquest® Bayer, Davis, California, USA), which was provided in the feed at the rate of 0.1 g/kg of feed (approximately 2.0×10^{10} cfu/g). Birds in SE followed Randall *et al.* (2006), except that 50 ppm enrofloxacin (10% solution (Symans Pharmaceuticals Pvt. Ltd., Lahore, Pakistan) was added to the drinking water on days 5 - 12 at a ratio of 1 ml drug/2 L water. If the medicated water was completely consumed in a day, then fresh water was made available. All chicks were vaccinated for Newcastle Disease (Nobilis® ND LaSota, Intervet International B.V. Boxmeer, Holland) with the vaccination schedule following industry-standard practice.

The average live bodyweight of each replicate was recorded at the beginning of each experimental week in the early morning before the birds were fed. Weekly weight gain was calculated, and feed intake was recorded weekly to estimate the feed conversion ratio (FCR) (as g feed: g gain) for each replication (Abo Ghanima *et al.*, 2020). The experimental unit was observed strictly for deaths of the birds. When a mortality occurred, the bird was weighed and removed promptly. Mortality rate was calculated weekly as a cumulative percentage. All data were adjusted to account for the mortality.

Cell-mediated immunity was measured according to Sikandar *et al.* (2017). On day 17, the basophilic hypersensitivity test was administered to two apparently healthy birds from each replicate by intradermal injection between the third and fourth digits of the right foot with 100 µg/100 µl/bird with phytohaemagglutinin-P (PHA-P) (Sigma-Aldrich, St. Louis, Missouri, USA). For comparison, 100 µl sterile phosphate-buffered saline was injected in the left foot and served as a control. The swelling at the site of injection was measured at 24 hours, 48 hours and 72 hours post injection with a pressure sensitive micrometer. Finally, the cell-mediated immune response (foot web index) to PHA-P was analysed by subtracting the thickness of the left foot from that of the right foot.

The organism was quantified in the cecal contents according to Park *et al.* (2014) with slight modifications. Briefly, six birds from each treatment were slaughtered, and the ceca were isolated aseptically. One gram digesta was taken from each cecum and mixed in sterile normal saline (NaCl 0.9% w/v). About 2 ml sample material of this cecal solution was added to peptone water and incubated overnight at 37 °C. Subsequently, a tenfold serial dilution (1: 9, w/v) was prepared and 50 µl of peptone water

(collected at the seventh dilution) was poured on SS agar. After 24 hours incubation, colony forming units (cfu) were counted in triplicate and the data were expressed as \log^{10} cfu/gm.

One bird was selected randomly from each replicate, weighed, and killed on days 21 and 35. Visceral organs, including the small intestine, liver, thymus, spleen and bursa of Fabricius, were removed and weighed. Samples of intestinal tissue (0.5–1.0 cm) were subsequently collected and preserved in 10% neutral buffered formalin for further histo-pathological analysis. The tissues excised from the duodenum (10 cm distal to the duodeno-gizzard junction), jejunum (5 cm proximal to Meckel's diverticulum), and ileum (5 cm anterior to the ileo-cecal junction) were processed with the paraffin sectioning technique. Histological sections of about 5 μ m thickness were prepared with a semi-automated rotary microtome (AMOS Scientific AEM-450, Austria) and stained with Haematoxylin and Eosin (Sikandar *et al.*, 2012). Three independent sections of each intestinal tissue were selected (about 50 μ m apart) and five well-oriented villi with intact lamina propria were selected for morphometric analysis. The slides were examined under a light microscope (Olympus CX31, Olympus Corp. Centre Valley, Pennsylvania, USA) at 4x magnification and analysed with a digitalized live image analysis program (Olympus DP20, Olympus Corp. Centre Valley, Pennsylvania, USA) and villus height was determined.

The normal distribution of the data was confirmed with the Kolmogorov-Smirnov test. The data were analysed using one-way ANOVA (SPSS Inc., version 20, Chicago, IL, USA). Each replicate was considered an experimental unit. Differences among means were assessed using Duncan's multiple range test. Effects were considered significant at $P \leq 0.05$. Results are presented as mean \pm SE.

Results and Discussion

Salmonellosis is a worldwide problem of the poultry sector, particularly in developing countries (Saleem *et al.*, 2016). Probiotics play an important role in combatting its invasion, and not only improve growth performance, but protect the mucosal epithelium from bacterial invasion, and hence impede its growth in tissues. The probiotic *B. subtilis*, which is added as a feed supplement, is gaining popularity in poultry production across the world by boosting the immune response (Dersjant-Li *et al.*, 2014). The positive effect of *B. subtilis* in non-infected healthy chickens was reported elsewhere (Sikandar *et al.*, 2017). However, limited studies have emphasized the prophylactic effects of *B. subtilis* QST-713 in birds that are challenged with *Salmonella gallinarum*. Therefore, the present project was designed to observe the influence of *B. subtilis* on broiler health and performance in *Salmonella*-challenged birds.

Birds of the infected groups had higher ($P < 0.05$) FCR during the first and second weeks compared with NN, whereas in the third week the FCR was higher ($P < 0.05$) for SN compared with other groups (Table 1). During the starter and grower phases, the FCR was statistically lower ($P < 0.05$) in non-infected NN than other groups, whereas during the finisher phase, higher ($P < 0.05$) growth performance was observed in SE, SP and NN compared with SN group (Table 1).

Table 1 Effects of *Bacillus subtilis* and Enrofloxacin on growth performance of broilers

Age, week	Measurement	Treatments				P-value
		NN	SN	SE	SP	
1	Gain	94.33 \pm 2.60 ^a	68.00 \pm 2.65 ^b	72.00 \pm 2.52 ^b	65.67 \pm 1.20 ^b	0.000
	FCR	1.36 \pm 0.03 ^b	1.84 \pm 0.08 ^a	1.66 \pm 0.07 ^a	1.78 \pm 0.07 ^a	0.002
2	Gain	241.00 \pm 2.00 ^a	51.00 \pm 0.58 ^c	96.33 \pm 5.78 ^b	109.33 \pm 2.40 ^b	0.000
	FCR	1.29 \pm 0.02 ^d	4.76 \pm 0.04 ^a	3.07 \pm 0.20 ^b	2.50 \pm 0.06 ^c	0.000
3	Gain	272.00 \pm 6.66 ^a	71.00 \pm 7.55 ^d	220.33 \pm 4.91 ^c	242.67 \pm 5.33 ^b	0.000
	FCR	2.07 \pm 0.07 ^b	5.05 \pm 0.34 ^a	2.25 \pm 0.03 ^b	2.07 \pm 0.04 ^b	0.000
4	Gain	314.67 \pm 7.51 ^b	156.00 \pm 17.09 ^c	494.67 \pm 20.85 ^a	520.67 \pm 16.46 ^a	0.000
	FCR	2.45 \pm 0.06 ^b	3.93 \pm 0.41 ^a	1.51 \pm 0.09 ^c	1.40 \pm 0.03 ^c	0.000
5	Gain	461.66 \pm 60.92 ^a	219.67 \pm 20.41 ^b	517.67 \pm 26.44 ^a	480.33 \pm 21.76 ^a	0.000
	FCR	2.64 \pm 0.35 ^b	4.28 \pm 0.38 ^a	2.14 \pm 0.13 ^b	2.26 \pm 0.08 ^b	0.002

^{a,b,c} Within a row, means with a common superscript were not different at $P = 0.05$

NN: not-infected, not medicated; SN: *S. gallinarum* infected, not medicated; SE: *S. gallinarum* infected, medicated with 50 ppm enrofloxacin; SP: *S. gallinarum* infected, mediated with 0.1 g/kg (2.0×10^{10} cfu/gm) *B. subtilis*.

Supplementation of *B. subtilis* ameliorated the growth performance of the infected birds and the birds of the supplemented groups were partially capable of adjusting the stress caused by the infection. Salmonella infection undesirably exaggerated the growth performance of the infected birds related to non-infected NN group. This reduction in the growth could be attributed to retarded gut function and feed mal-absorption due to luminal viscous conditions caused by inflammation and sloughing of the intestinal mucosa (Sikandar *et al.*, 2013). The supplemented groups showed lower ($P < 0.05$) FCR from the third week onwards, which indicated that the products used in those groups exerted a protective effect against Salmonella and thus reflected a better feed efficiency. Lower FCR and better growth in the supplemented groups could be correlated with villus height in the small intestine (Dersjant-Li *et al.*, 2016), because increased size of villi provides a bigger area for the absorption of available nutrients, whereas the challenged group has the lowest height of intestinal villi. A lower feed intake in SN infected birds might be the reason for decreased weight gain. Consequently, this reduced feed intake, in conjunction with poor absorption of feed through dwarfed villi, contributed to compromised immunity in infected chickens.

The thickness of the right foot was significantly higher ($P < 0.05$) in SP at all 24 hour, 48 hour and 72 hour intervals post injection compared with other groups after injecting phyto-haemagglutinin-P (Figure 1).

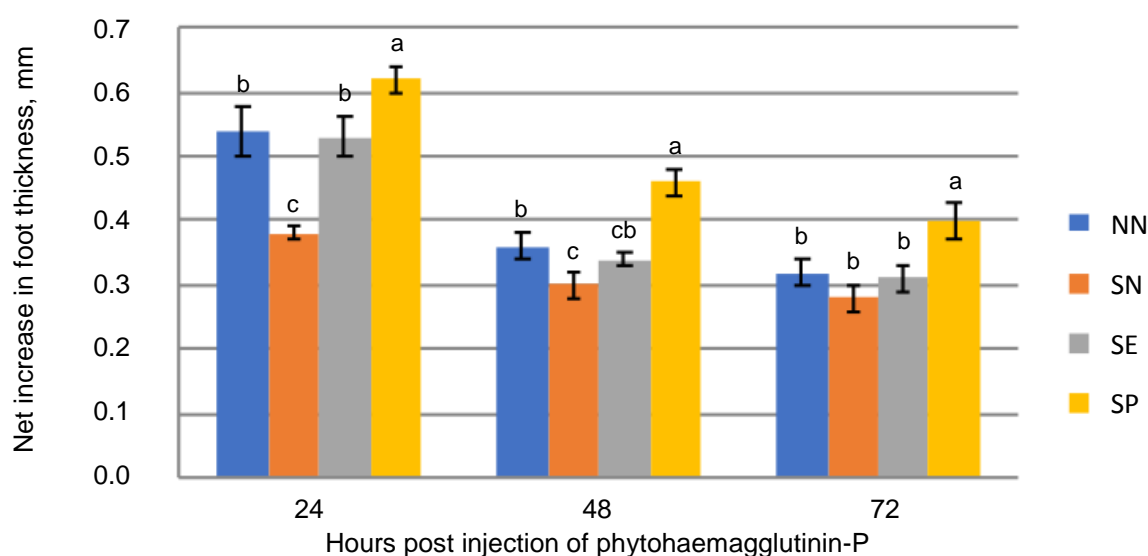


Figure 1 Lymphoproliferative immune response post injection of phytohaemagglutinin- P in Salmonella-infected and control broiler chicks

Within a time point, bars headed by a common letter were not different at $P = 0.05$

NN: non-infected, non-medicated; SN: *S. gallinarum* challenged, non-medicated; SE: *S. gallinarum* challenged + 50 ppm enrofloxacin; SP: *S. gallinarum* challenged + 0.1 g/kg (2.0×10^{10} cfu/gm) *B. subtilis*.

The thicknesses of the foot and organ-body weight ratio in infected animals indicated lower cell-mediated immunity. But the high cell-mediated immune response post PHA-P injection indicated that *B. subtilis* played a role in the stimulation of an immune response to an acute infection. It is well recognized that *B. subtilis* has a role in the modulation of normal microflora (Zhang *et al.*, 2017), and regulation of systemic immuno-modulatory functions in healthy chickens (Lee *et al.*, 2015; Tarradas *et al.*, 2020), and in those infected with coccidiosis (Dersjant-Li *et al.*, 2016).

On day 21, the relative weight of thymus was decreased ($P < 0.05$) in SN, whereas that of bursa increased ($P < 0.05$) in SP compared with the NN and SN groups (Figure 2). Compared with other groups, the relative weight of thymus was higher ($P < 0.05$) in SP on day 35 (Figure 3).

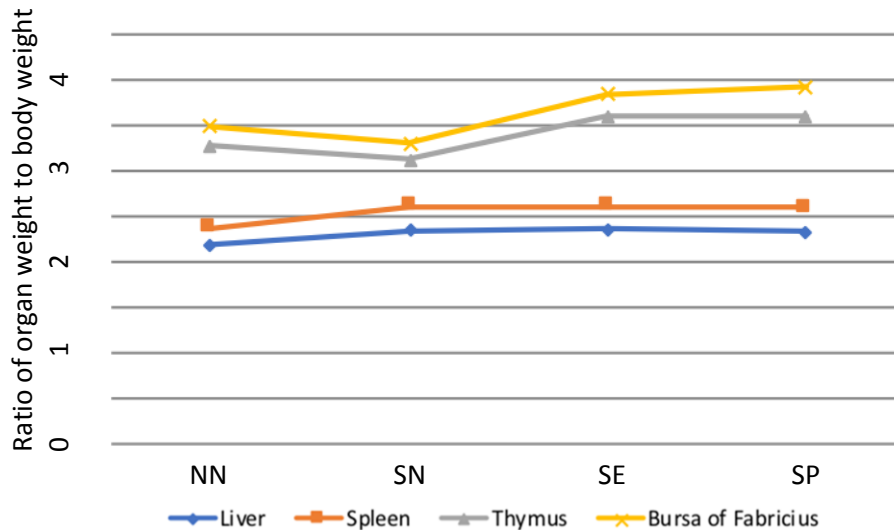


Figure 2 Ratio of organ weight to bodyweight for lymphoid organs harvested from broiler chickens on day 21

NN: non-infected, non-medicated; SN: *S. gallinarum* challenged, non-medicated; SE: *S. gallinarum* challenged + 50 ppm enrofloxacin; SP: *S. gallinarum* challenged + 0.1 g/kg (2.0×10^{10} cfu/gm) *B. subtilis*

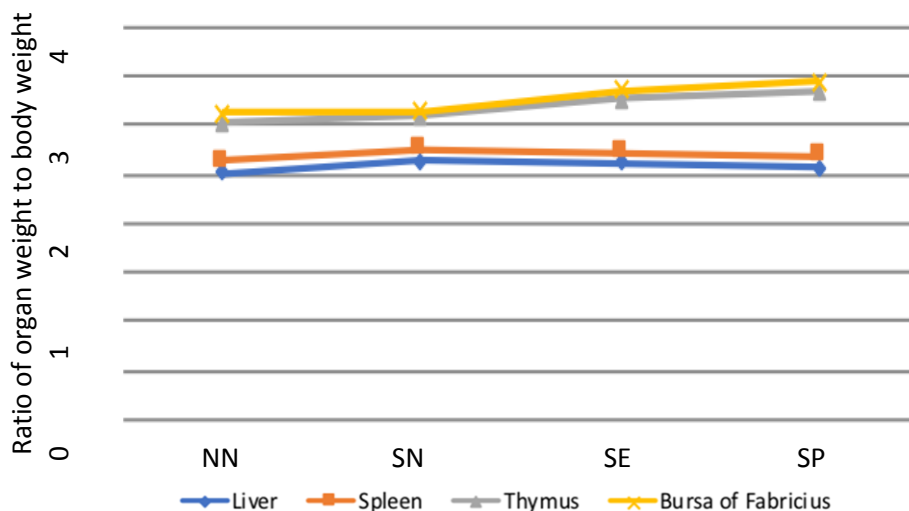


Figure 3 Ratio of organ weight to bodyweight for lymphoid organs harvested from broiler chickens on day 35

NN: non-infected, non-medicated; SN: *S. gallinarum* challenged, non-medicated; SE: *S. gallinarum* challenged + 50 ppm enrofloxacin; SP: *S. gallinarum* challenged + 0.1 g/kg (2.0×10^{10} cfu/gm) *B. subtilis*

The relative weights of thymus and bursa decreased in the SN group but increased with supplementation of *B. subtilis*. This enhanced weight might be owing to a compensatory mechanism by which an increased number of antibodies were produced to combat the disease condition (Shabani *et al.*, 2019). Differences were not detected among groups in the relative weights of liver and spleen, as observed elsewhere (Saleem *et al.*, 2016). The spleen and liver of the SN group were moderately swollen with oedema, and surface capsules were fragile, cracked on the application of gentle pressure, and had yellowish streaks on the surface.

The microarchitecture of the gut mucosa, including villus height, represents a well-known histological parameter to assess the digestive and absorptive efficiency in the intestine (Stefanello *et al.*, 2020). These structures are exposed primarily to feed and its antigens cause lesions and sloughing of the epithelial cells and thus

affect their secretory and absorptive functions (Sikandar *et al.*, 2012). In the duodenum the villus height decreased ($P < 0.05$) in SN compared with all other groups at day 21 (Figure 4).

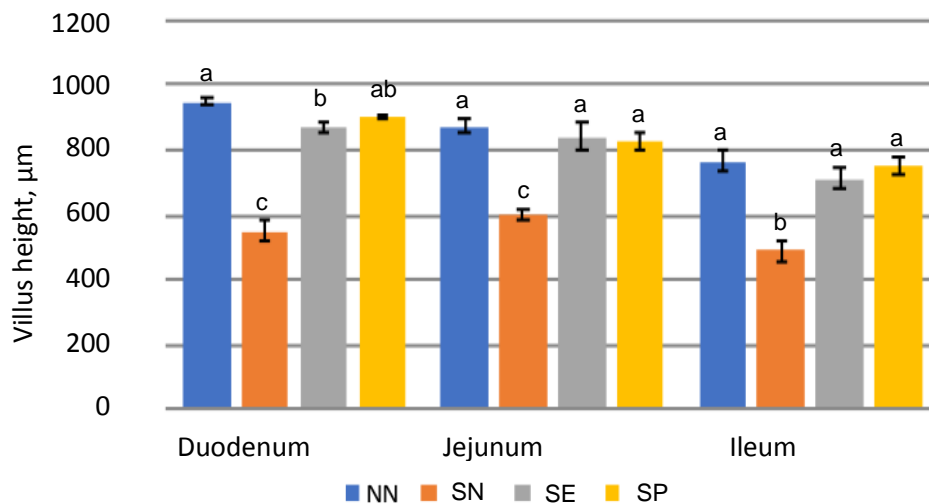


Figure 4 Villus heights for segments of small intestine in *Salmonella*-infected broiler chicks and control chicks on day 21

^{a,b,c} Within a segment, bars headed by a common letter were not different at $P = 0.05$

NN: non-infected, non-medicated; SN: *S. gallinarum* challenged, non-medicated; SE: *S. gallinarum* challenged + 50 ppm enrofloxacin; SP: *S. gallinarum* challenged + 0.1 g/kg (2.0×10^{10} cfu/gm) *B. subtilis*.

At day 35, the villus height of duodenal mucosa was greater ($P < 0.05$) in SP compared with NN and SN groups (Figure 5) whereas the villus length was lower ($P < 0.05$) in SN compared with all other groups for the jejunum and ileum.

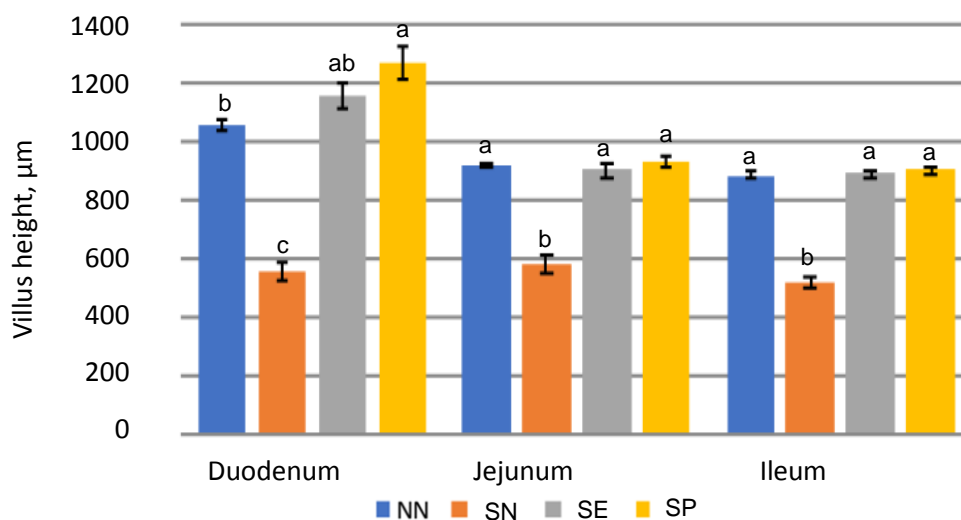


Figure 5 Villus heights for segments of small intestine in *Salmonella*-infected broiler chicks and control chicks on day 35

^{a,b,c} Within a segment, bars headed by a common letter were not different at $P = 0.05$

NN: non-infected, non-medicated; SN: *S. gallinarum* challenged, non-medicated; SE: *S. gallinarum* challenged + 50ppm enrofloxacin; SP: *S. gallinarum* challenged + 0.1 g/kg (2.0×10^{10} cfu/gm) *B. subtilis*

In the current study, the increases in villus height of the intestinal segments in the groups supplemented with *B. subtilis* indicated an underlying protective mechanism comparable with that in the SE group. Moreover, the improved morphometric indices of the gut segments in SP might be attributable to an

increase in the number of microbiomes in sympathetic association with the mucosa (Awad *et al.*, 2016) and enhanced vascular supply in reaction to *Salmonella* in the intestinal lumen. An increase in the surface area of the villi (not reported) in the jejunum and ileum in all supplemented groups compared with SN indicated the enhanced villus function that resulted in better performance by the supplemented groups. Deeper crypts (not reported) in the SN group might indicate rapid tissue turnover following mucosal renewal to maintain the absorptive surface area (Yang & Liao, 2019). The tissue that was most affected was the lining mucosa of the small intestine in the affected SN group, in which the epithelium lining the villi was sloughed, and the villi were reduced in size, and appeared to be denuded and ulcerated. This caused a reduction of villus length and the surface area available for nutrient uptake that might ultimately be linked with the lower growth rate in the SN group.

Because increased ($P < 0.05$) numbers of *Salmonella* were present in the SN group, this confirmed the success of the challenge. On days 21 and 35 the protective effect of SP was similar to that of the SE group in controlling the cecal *Salmonella* population and load (Figure 6).

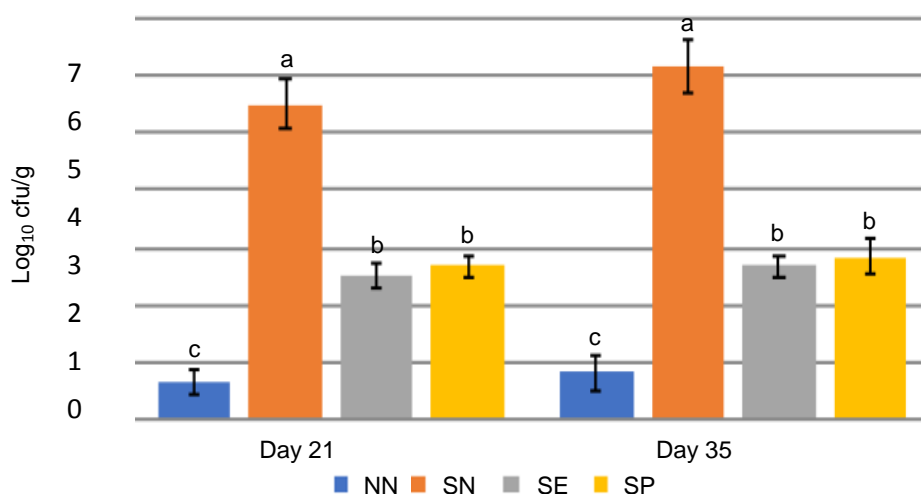


Figure 6 Quantification of intestinal *Salmonella* numbers in broiler chicks treated with antibiotic or probiotic and control chicks

^{a,b,c} Within a day, bars headed by a common letter were not different at $P = 0.05$

NN: non-infected, non-medicated; SN: *S. gallinarum* challenged, non-medicated; SE: *S. gallinarum* challenged + 50 ppm enrofloxacin; SP: *S. gallinarum* challenged + 0.1 g/kg (2.0×10^{10} cfu/gm) *B. subtilis*.

The ceca are the preferred site of *Salmonella* and analysed for the effects of treatments against the bacterium (Nair *et al.*, 2019). *Salmonella* was isolated from all the replicates in this study, and thus the supplemented ingredients were not able to prevent its colonization in the ceca. However, significant reductions in the size of the *Salmonella* populations were observed in the SE and SP groups with greater ($P < 0.05$) colonization being found in the SN group. These results are in line with the findings of Saleem *et al.* (2016) and Arbab *et al.* (2017), in which higher colonization of *Salmonella* was observed in the ceca after an orally administered challenge. Spores of *B. subtilis* are suitable candidates for the competitive exclusion of the pathogens (de Oliveira *et al.*, 2014). Moreover, it has been reported that *B. subtilis* causes the expression of Interleukin 22 and the inhibitor of nuclear factor kappa B in the mucosa for defence against harmful microorganisms (Yang *et al.*, 2018), the effect of which is to reduce the chance of subsequent mortality.

No mortality was recorded in the non-infected NN group throughout the trial, whereas in the other treatments mortality was first observed in the second week and was higher ($P < 0.05$) in SN compared with the SE and SP groups during the experiment. Severe mortality was observed in the third week of the experiment and 46.67% mortality was recorded in SN. Previously, Carina *et al.* (2000) noted 50% mortality in birds infected experimentally with *Salmonella*. Taghavi *et al.* (2008) noted that *Salmonella* infections at a young age can cause high mortality, whereas in older birds no clinical signs are seen. De Oliveira *et al.* (2014) found that mortality was not high in chicks that were challenged at 4 days of age, but performance was still compromised. Variation in mortality could be due to the ages and types of chickens, challenged organisms, and the dose and rearing status. The challenged birds had typical symptoms of salmonellosis, including prostration and ruffled feathers before death. Other clinical signs were increased thirst, reluctance

to move, vent pasting and yellowish or greenish diarrhoea. Comparatively fewer severe clinical signs were observed in the SE and SP chickens. Mortality was not found in the non-infected group, and growth was retarded with decreased weekly weight gain in the chicks that survived infection. In contrast, low ($P < 0.05$) mortality rates and improved weight gains were noted in the SE and SP groups. These positive effects might be because of the effects of the supplemented probiotic and antibiotic products on the colonization of *Salmonella* in the gut.

Conclusions

Supplementation of *B. subtilis* facilitates growth in chickens through improvement in gut mucosal micro-architecture and improves the systemic immune response in birds. Moreover, *B. subtilis* produced results that were comparable with the antibiotic group and sustained better health status in broilers when they were challenged with *Salmonella*. Thus, the addition of *B. subtilis* to poultry feed is strongly recommended to avoid the side effects of antibiotics and to combat infectious agents better. Further studies are required to find the molecular pathways of *B. subtilis* QST-713 strain on activation of host immunity against pathogenic microorganisms.

Acknowledgements

This work was supported by HEC-Pakistan and the authors acknowledge Prof. Dr. Ashiq H. Cheema for providing professional writing services.

Authors Contributions

AS, AN, MD, and HFR established the experimental shed, arranged materials, and performed the methodology. HZ and AS analysed the data. AS, HMA, NM, TR and AR contributed to tissue collection, immunology, microscopy and the manuscript writeup.

Conflict of Interest Declaration

The authors declare that there is no conflict of interest.

References

- Abo Ghanima, M.M., Abd El-Hack, M.E., Othman, S.I., Taha, A.E., Allam, A.A., Abdel-Moneim, A.M.E., 2020. Impact of different rearing systems on growth, carcass traits, oxidative stress biomarkers, and humoral immunity of broilers exposed to heat stress. *Poult. Sci.* 99(6), 3070-3078. DOI: 10.1016/j.psj.2020.03.011
- Abudabos, A.M., Ali, M.H., Nassan, M.A. & Saleh, A.A., 2019. Ameliorative effect of *Bacillus subtilis* on growth performance and intestinal architecture in broiler infected with *Salmonella*. *Animals* 9(4), 190. DOI: 10.3390/ani9040190
- Arbab, S., Hafsa, Z., Muhammad, Y., Saima, M., Asim, A., Saima, A., Muhammad, A. & Habib, R., 2017. Protective effect of sodium butyrate on growth performance, immune responses and gut mucosal morphometry in *Salmonella*-challenged broiler chickens. *Int. J. Agri. Biol.* 19, 1387–93. DOI: 10.17957/IJAB/15.0424
- Audisio, M.C., Oliver, G. & Apella, M.C., 2000. Protective effect of 10.1128/AEM.02747-16J96, a potential probiotic strain, on chicken infected with *Salmonella pullorum*. *J. Food Prot.* 63, 1333-37. DOI: 10.4315/0362-028X-63.10.1333
- Awad, W. A., Mann, E., Dzieciol, M., Hess, C., Schmitz-Esser, S., Wagner, M., & Hess, M., 2016. Age-related differences in the luminal and mucosa-associated gut microbiome of broiler chickens and shifts associated with *Campylobacter jejuni* infection. *Front. Cell. Infect. Microbiol.* 6, 154. DOI:10.3389/fcimb.2016.00154
- de Oliveira, J.E., Van der Hoeven-Hangoor, E., Van de Linde, I.B., Montijn, R.C. & Van der Vossen, J.M.B.M., 2014. In ovo inoculation of chicken embryos with probiotic bacteria and its effect on posthatch *Salmonella* susceptibility. *Poult. Sci.* 93, 818–29. DOI: 10.3382/ps.2013-03409
- Dersjant-Li, Y., Awati, A., Kromm, C. & Evans, C., 2014. A direct fed microbial containing a combination of three-strain *Bacillus* spp. can be used as an alternative to feed antibiotic growth promoters in broiler production. *J. Appl. Anim. Nutr.* 2, 1-6. DOI: 10.1017/jan.2014.4
- Dersjant-Li, Y., Gibbs, K., Awati, A. & Klasing, K.C., 2016. The effects of enzymes and direct fed microbial combination on performance and immune response of broilers under a coccidia challenge. *J. Appl. Anim. Nutr.* 4, 1-14. DOI: 10.1017/jan.2016.2
- Lee, K.W., Kim, D.K., Lillehoj, H.S., Jang, S.I. & Lee, S.H., 2015. Immune modulation by *Bacillus subtilis*-based direct-fed microbials in commercial broiler chickens. *Anim. Feed. Sci. Technol.* 200, 76-85. DOI: 10.1016/j.anifeedsci.2014.12.006
- Nair, D.V.T & Anup, K.J., 2019. *Salmonella* in poultry meat production. Food safety in poultry meat production. Food Microbiology and Food Safety series. Springer, Cham, Switzerland. Pp. 1-24. DOI: 10.1007/978-3-030-05011-5
- Park, J.H. & Kim, I.H., 2014. The effects of the supplementation of *Bacillus subtilis* RX7 and B2A strains on the performance, blood profiles, intestinal *Salmonella* concentration, noxious gas emission, organ weight and breast meat quality of broiler challenged with *Salmonella typhimurium*. *J. Anim. Physiol. Anim. Nutr.* 99, 326-34. DOI: 10.1111/jpn.12248
- Randall, L.P., Cooles, S.W., Coldham, N.C., Stapleton, K.S., Piddock, L.J. & Woodward, M.J. 2006. Modification of enrofloxacin treatment regimens for poultry experimentally infected with *Salmonella enterica serovar typhimurium*

- DT104 to minimize selection of resistance. *Antimicrobial Agents and Chemotherapy (AAC)* 4030-37. DOI: 10.1128/AAC.00525-06
- Saleem, G., Ramzaan, R., Khattak, F. & Akhtar, R., 2016. Effects of acetic acid supplementation in broiler chickens orally challenged with *Salmonella pullorum*. *Turk. J. Vet. Anim. Sci.* 40, 434-43. DOI: 10.3906/vet1505-66
- Shabani, R., Fakhraei, J., Yarahmadi, H.M. & Seidavi, A., 2019. Effect of different sources of selenium on performance and characteristics of immune system of broiler chickens. *Revista Brasileira de Zootecnia* 48. <https://www.scielo.br/pdf/rbz/v48/1806-9290-rbz-48-e20180256.pdf>
- Sikandar, A., Cheema, A.H., Younus, M., Aslam, A., Zaman, M.A. & Rehman, T., 2012. Histopathological and serological studies on paratuberculosis in cattle and buffaloes. *Pak. Vet. J.* 32, 547-51.
- Sikandar, A., Cheema, A.H., Adil, M., Younus, M., Zaneb, H., Zaman, A., Tipu, M.Y. & Masood, S., 2013. Ovine paratuberculosis – A histopathological study from Pakistan. *The J. Anim. Plant Sci.* 23(3), 749-753.
- Sikandar, A., Zaneb, H., Younus, M., Masood, S., Aslam, A., Shah, M. & Rehman, H. 2017. Growth performance, immune status and organ morphometry in broilers fed *Bacillus subtilis*-supplemented diet. *S. Afr. J. Anim. Sci.* 47(3), 378-88.
- Stefanello, C., Rosa, D.P., Dalmoro, Y.K., Segatto, A.L., Vieira, M. S., Moraes, M. L. & Santin, E. 2020. Protected blend of organic acids and essential oils improves growth performance, nutrient digestibility, and intestinal health of broiler chickens undergoing an intestinal challenge. *Frontiers in Veterinary Science* 6, 491. DOI: 10.3389/fvets.2019.00491
- Taghavi, A., Allan, B., Mutwiri, G., van Kessel, A., Willson, P., Babiuk, L., Potter, A. & Gomis, S., 2008. Protection of neonatal broiler chicks against *Salmonella* Typhimurium septicemia by DNA containing CpG motifs. *Avian Dis.* 52, 398-406. DOI: 10.1637/8196-121907-Reg
- Tarradas, J., Tous, N. & Esteve-Garcia, E., 2020. The control of intestinal inflammation: A major objective in the research of probiotic strains as alternatives to antibiotic growth promoters in poultry. *Microorganisms* 8(2), 148. DOI: 10.3390/microorganisms8020148
- Xie, S., Yang, F., Tao, Y., Chen, D., Qu, W., Huang, L., Liu, Z., Pan, Y. & Yuan, Z., 2017. Enhanced intracellular delivery and antibacterial efficacy of enrofloxacin-loaded docosanoic acid solid lipid nanoparticles against intracellular *Salmonella*. *Sci. Rep.* 7, 41104. DOI: 10.1038/srep41104
- Yang, J., Qian, K., Wang, C. & Wu, Y., 2018. Roles of probiotic lactobacilli inclusion in helping piglets establish healthy intestinal inter-environment for pathogen defense. *Probiotics Antimicrob. Proteins* 10(2), 243-50. DOI: 1007/s12602-017-9273-y
- Yang, Z., & Liao, S. F., 2019. Physiological effects of dietary amino acids on gut health and functions of swine. *Frontiers Veterinary Sci.* 6. DOI: 10.3389/fvets.2019.00169
- Yasmin, S., Nawaz, M., Anjum, A.A., Ashraf, K., Basra, M.A.R., Mehmood, A., Khan, I. & Malik, F., 2019. Phytochemical analysis and In Vitro activity of essential oils of selected plants against *Salmonella enteritidis* and *Salmonella gallinarum* of poultry origin. *Pak. Vet. J.* 40(2), 139-144. DOI: 10.29261/pakvetj/2019.110
- Zhang, W., Zhu, Y H., Zhou, D., Wu, Q., Song, D., Dicksved, J. & Wang, J F. 2017. Oral administration of a select mixture of *Bacillus* probiotics affects the gut microbiota and goblet cell function in newly weaned MUC4 resistant pigs following *Escherichia coli* challenge. *Appl. Environ. Microbiol.* 83 (3), 2747-16. DOI: 10.1128/AEM.02747-16