

A simplified and evidence-informed approach to designing removable partial dentures.

Part 5. Design examples for Kennedy classifications

SADJ March 2024, Vol. 79 No.2 p92-101

C Peter Owen¹

SUMMARY

For many decades the literature has regularly reported that there is a discrepancy between what is taught in dental school and what is practised, especially in the field of removable partial dentures. Not only that, but for more than 60 years reports from around the world have shown that, usually, the majority of clinicians abdicate their responsibility to design a removable partial denture (RPD) and instead leave this to the dental technician, who has no knowledge of the clinical condition of the patient and works only from a cast. Most patients around the world who require RPDs to improve aesthetics and chewing can only afford a removable prosthesis simply because the majority are poor. But RPDs can improve these aspects and contribute to an improved quality of life.

The purpose of this series of articles is to derive the basic, evidence-informed principles of partial denture design and to suggest a simplified explanation and application of those principles in the hope that clinicians will increasingly take responsibility for the design of partial dentures. Part 1 summarised studies revealing what can only be described as the malpractice of abdication of responsibility for design by clinicians, and then explained the evidence-informed basic principles of design; Part 2 looked at the biomechanical basis of those principles in terms of support; Part 3 did the same for the biomechanical basis of retention; Part 4 provided a simple seven-step approach to design, applied to an example of an acrylic resin-based and a metal framework-based denture for the same partially edentulous arch; and, finally, this part will provide examples of designs for RPDs that have been successfully worn by patients, for each of the Kennedy Classifications of partially dentate arches. Much of this is referenced from an electronic book on the Fundamental of removable partial dentures.¹

Author's information

CP Owen, Professor Emeritus, Faculty of Health Sciences, University of the Witwatersrand, Johannesburg, South Africa
ORCID: 0000-0002-9565-801

Running title

A simplified approach to designing RPDs

Keywords

Removable partial denture, design, support, retention, acrylic-based, framework-based

Corresponding author

Name: Prof CP Owen
Tel: +27 83 679 2205
Email: peter.owen@wits.ac.za

Conflict of interest

None

Introduction to Part 5

The purpose of these design examples is not to be prescriptive about how a design should look, such as for a particular Kennedy classification. No clinical details have been given, so that some designs are only possible because of favourable occlusions: many times modifications have to be made, for example when an overbite exists. So, these designs are more to provide a suggestion for how a prescription to a dental laboratory might look, and how much information can be conveyed by means of a simple drawing. Although these designs have been produced with a computer drawing package, simple hand drawings are easier to produce and, with practice, clinicians can become very adept at making them quickly; or at least conveying what they need to the dental technician. For the metal-based designs shown here, the darker shading represents the polished portions of the base, and the lighter shaded areas the sand-blasted portions which carry the acrylic base with the replacement teeth. Any cingulum rest seats beneath acrylic or metal are shaded darker. Designs will be given for each main Kennedy classification, with examples using both acrylic and metal bases. All are real-life examples, taken from dentures that are being successfully worn – and used – by patients.¹ They do not preclude other appropriate designs, but it should be noted that if sensible and biological principles of design are adhered to, it turns out that there will, in fact, be limited options available for each clinical situation.

KENNEDY CLASS I

Mandibular

All mandibular distal extension base dentures require indirect retention as well as active retention in the form of clasps on the abutment teeth, as explained in Part 3 of this series.² A recent paper also found a positive association between masticatory performance and the presence of indirect retention.³ There is no evidence that a mesial rest imparts any advantage, and as also explained in Part 3² there is no evidence for the use of the RPI clasp system.

For acrylic bases, a lingual plate is unavoidable. It is possible to purchase stainless steel lingual bars for these cases, but they are unstable and the acrylic over the saddles must be quite bulky; even so, crazing and fractures are common. They are therefore not recommended. The lingual plate will rest against the inclined planes of the incisors, so it is necessary to place cingulum rests to prevent any untoward forward movement of the incisors. It is recommended that good cingulum rest seats be prepared on the canines and smaller ones on the incisors (as there is less enamel on these teeth). The rests on the canines also provide indirect retention. All this will apply also to a metal lingual plate or dental bar as a major connector. The rules for the possible framework-based major connectors are given in the box.

RULES FOR FRAMEWORK-BASED MANDIBULAR MAJOR CONNECTORS

Lingual Plate

Location: The superior border is continuous with the cingulum areas of the anterior teeth, or at the lingual survey line of the posterior teeth. The inferior border is at or just superior to the level of the elevated lingual sulcus. The apron extends interproximally to the height of the contact.

Indications: As this covers all gingival margins, it should be avoided and is used only when there is insufficient space for a lingual bar, a Kennedy bar or the alignment of the teeth precludes the use of a dental bar. It may perhaps be useful if there is the possibility of future loss of anterior teeth, though in this case an acrylic base would be more sensible.

Lingual Bar

Location: Superior border at least 2mm from the gingival margin. Inferior border at the level of the elevated (functional) lingual sulcus.

Indications: Sufficient space between the elevated lingual sulcus and the lingual gingival tissues. This is the connector of choice if there is at least 8mm between the gingival margins and the lingual sulcus.

Shape and size: Half tear-drop shaped, bulkiest portion inferiorly; superior border tapered, at least 6mm in height. Very occasionally a short bar passing only two or three teeth can be thinner, but must be at least 4mm in height.

Kennedy Bar (Lingual Bar and Continuous dental bar)

Location: Lingual bar: superior border at least 2mm from the gingival margin. Inferior border at the level of the elevated (functional) lingual sulcus. Dental bar: continuous bar along the cingula of the anterior teeth and lingual surfaces of premolars.

Indications: When there is insufficient room for a normal lingual bar (ie less than 8mm), usually as a result of gingival recession. But there must be at least 6mm between the gingival margins and the lingual sulcus. The alignment of the teeth must allow for the use of a dental bar.

Shape and size: Dental bar 3mm in height, tapers to tooth superiorly and inferiorly. Because the lingual bar forms part of a double bar it can be thinner. It should still be the same shape (half tear-drop shaped, bulkiest portion inferiorly; superior border tapered) and 4mm in height.

Dental Bar

Location: A continuous bar along the cingula of the anterior teeth.

Indications: When there is insufficient room for a lingual bar or a Kennedy bar. Tooth alignment must be favourable.

Shape and size: 4-6mm in height, depending on the size of the teeth, tapers to tooth superiorly and inferiorly. Must be thick enough for adequate rigidity, depending on length.

Sublingual Bar

Location: Occupies the width and depth of the lingual sulcus. Of academic interest only, as the other alternatives always provide a valid solution. The impression is difficult to make and this connector requires high adaptability on the part of the patient.

Whatever the base material used, the evidence is that these dentures are not easy to use, but there is little evidence to explain why, and the few follow-up surveys have shown contrasting results. After 8-9 years, one study found that 24% of mandibular Class I dentures were no longer being worn;⁴ whereas another study found that there was a 7% loss over 10 years and a 31% loss over 20 years (but the observation period was from 3 to 36 years).⁵ There is, however, some correlation between some features of these dentures when having been worn successfully, and which were important in preserving health, and those are:⁶

- the presence of positive occlusal and/or cingulum rests
 - the presence of guide plane/guiding surface contact on the abutment teeth
 - extension of the distal extension base onto the retromolar pad and over the buccal shelf to the buccal vestibule
 - placing rests on 2 or more teeth adjacent to each distal extension.
- It is important to bear these features in mind, especially that of the denture base over the distal extension, as so many encountered are underextended. It is useful to think of the denture base that extends from the abutment tooth posteriorly as being the equivalent of what a complete denture would be in that same area.

DESIGN EXAMPLES

Mandibular

Figures 1-2 show typical examples of acrylic-based and framework-based mandibular distal extension partial dentures.

If there is insufficient room for a lingual bar, then an alternative design well accepted by patients (again, if there is sufficient room) is the Kennedy bar, as in Figure 3.

Maxillary

There are differing opinions, not often expressed in the literature, and certainly without evidence, as to whether indirect retention is required in maxillary distal extension bases. The issue is whether you believe the distal part of the denture will fall down either under gravity or during chewing.

The answer may lie in what happens in a complete denture. Patients who wear and use complete dentures successfully appear to use their tongue quite differently: the posterior part rises to contact the posterior half of the maxillary denture, and the mandibular denture is controlled by the tongue sitting comfortably behind and in contact with the mandibular incisors. This has been shown to increase the retention and stability of the mandibular complete denture.⁷ It is reasonable to assume that the same will apply to distal extension bases. In general, then, the (albeit anecdotal, experiential) advice is that indirect retention is unlikely to be required in a maxillary distal extension base denture.

Design examples

Figure 4 shows a typical design for a maxillary Class I acrylic-based denture. There is a cingulum rest on the 13

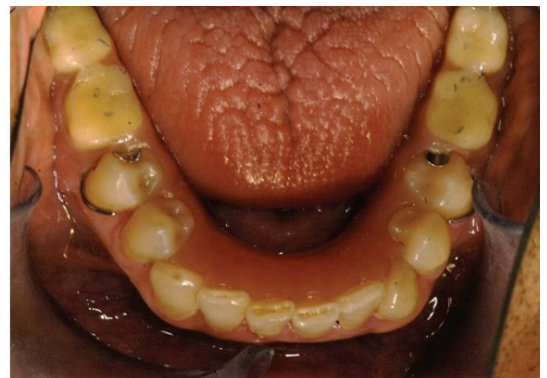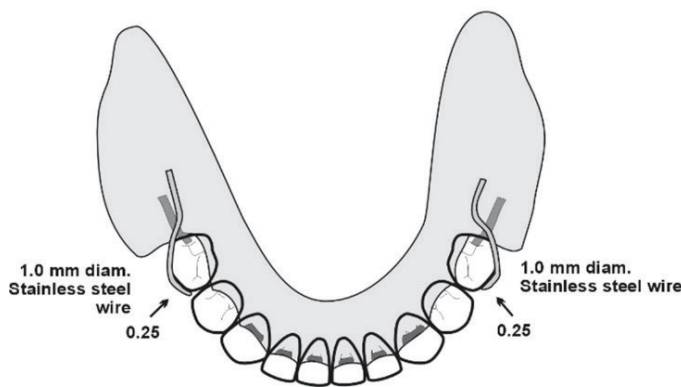


Figure 1. The drawing, and the denture in the mouth for an acrylic-based denture. Note that there are rest preparations on the canines and all incisors. The undercut of 0.25mm is appropriate for the wrought wire clasps.

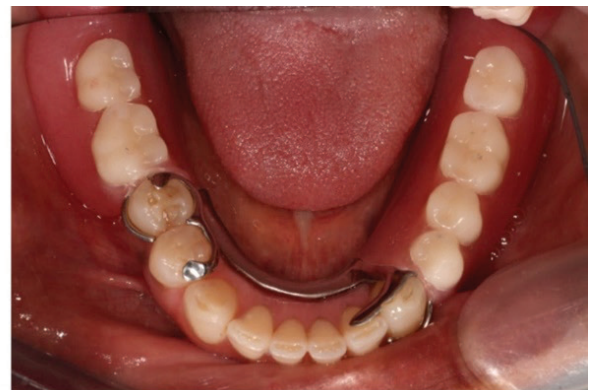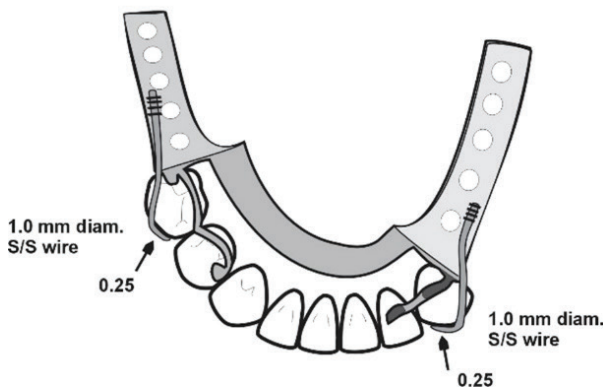


Figure 2. The drawing, and the denture in the mouth for a metal-based denture. Cingulum rests are on the 33 and 32, which provides indirect retention, as does the mesial rest on 44. Wrought wire has been used for the clasps because of their length; the wire is soldered or welded to the metal framework (depicted by the small cross-lines).

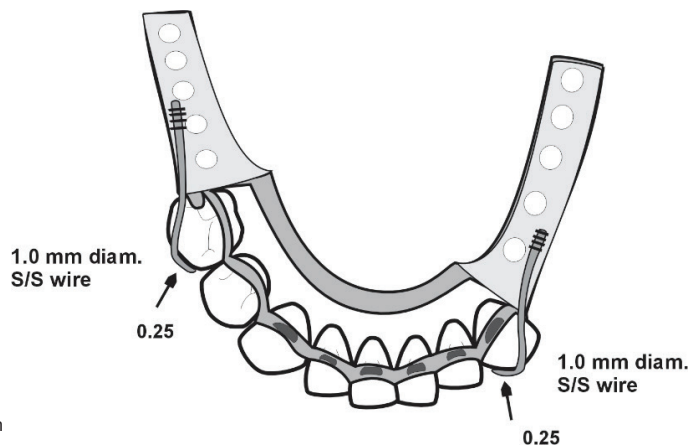


Figure 3. An alternative design for the case in Figure 2, using a Kennedy bar. Rest seats are on the canines and all incisors.

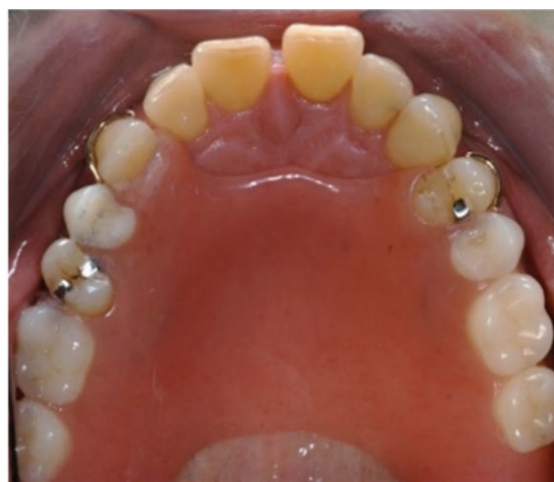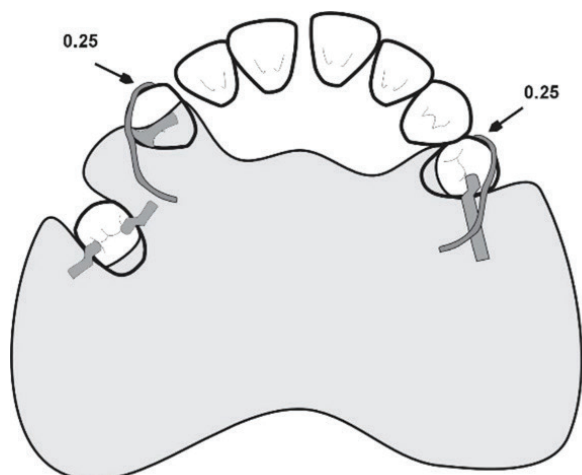


Figure 4. The drawing, and the denture in the mouth for an acrylic-based denture. Note that it is not necessary to festoon the denture around all the teeth – that would be unnecessary gingival coverage and potentially iatrogenic. Note also that the lone standing premolar has both mesial and distal rests. This ensures that this somewhat periodontally susceptible tooth is protected and is a good rule of thumb for all lone standing teeth.

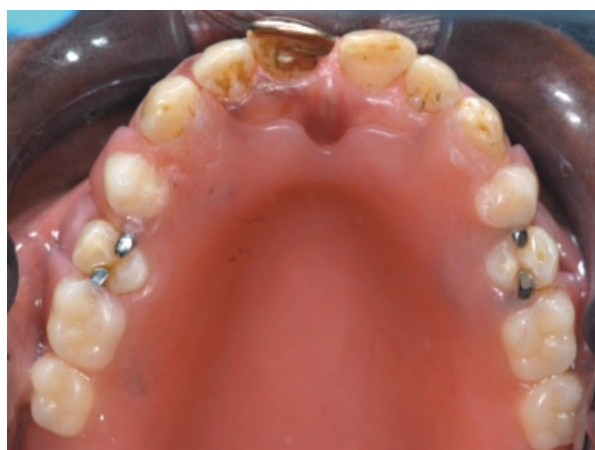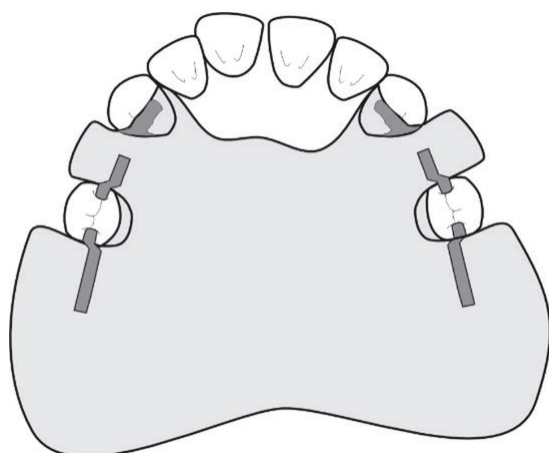


Figure 5. The drawing, and the denture in the mouth for an acrylic-based denture without clasps.

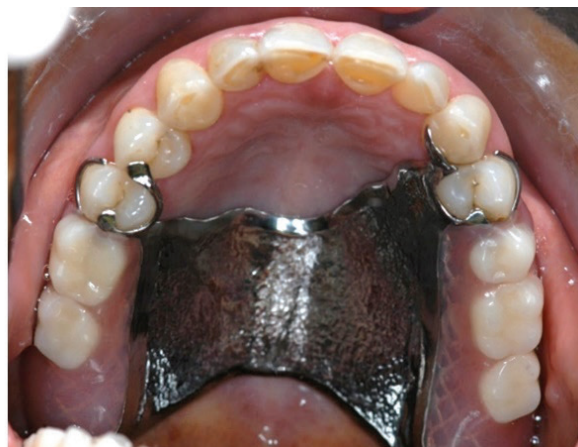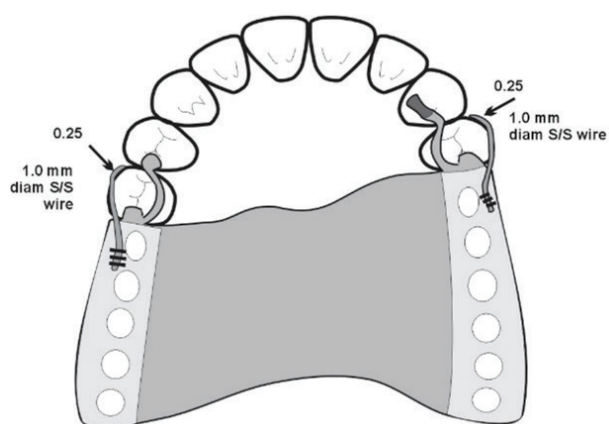


Figure 6. The drawing, and the denture in the mouth for the metal-based denture.

which will be continuous with the guide plane. The clasps will, unfortunately, be visible if the patient has a high smile line. Where sufficient guide planes can be made, and the guiding surfaces are refined in the mouth, clasps may not be necessary, as shown in Figure 5.

The metal-based denture shown in Figure 6 does have indirect retention by extending onto the 14 and the 23.

KENNEDY CLASS II Mandibular

The principles elucidated above apply to unilateral distal extension bases as well, but the design requires cross-arch stabilisation as well as retention, which makes acrylic-based dentures a lot bulkier than their framework-based counterparts. When there is a modification space, that makes the design a little easier.

Design examples
Mandibular

Figure 7 shows a typical design for a Kennedy Class II acrylic-based denture and Figure 8 shows a design when there is no modification space in the opposing arch. Figure 9 shows a typical metal-based design and Figure 10 shows a variation to reduce gingival coverage.

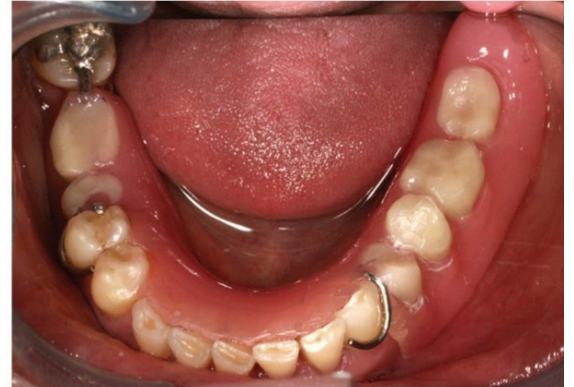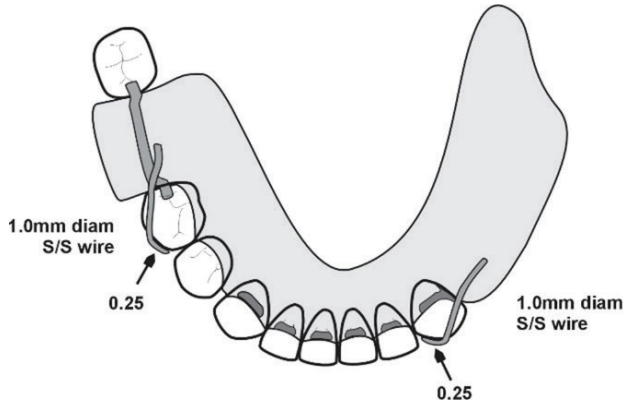


Figure 7. The drawing, and the denture in the mouth for an acrylic-based denture. As with the Class I situation, the lingual plate requires cingulum rests. If there is no modification space in the opposing arch, then a typical design would be as in Figure 8.

Figure 8. A design for a Kennedy Class II acrylic-based denture with no modification spaces. The decision has to be whether to engage the distal or mesial undercut. Because any rotation caused by lifting of the distal extension base needs to be counteracted, it seems sensible to engage the distal undercut. Note that the clasp also acts a rest, as it passes between the 45 and the 46.

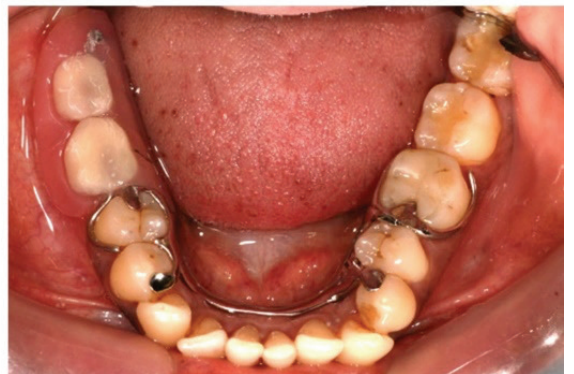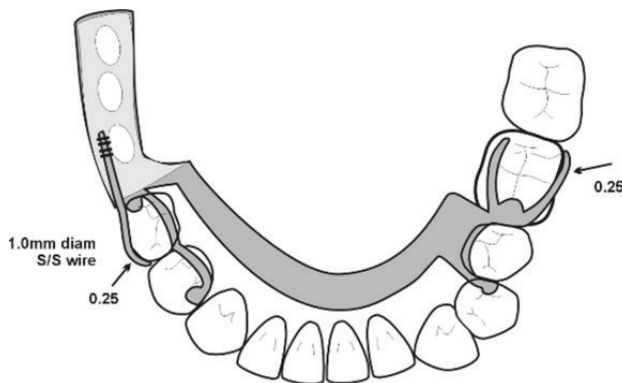
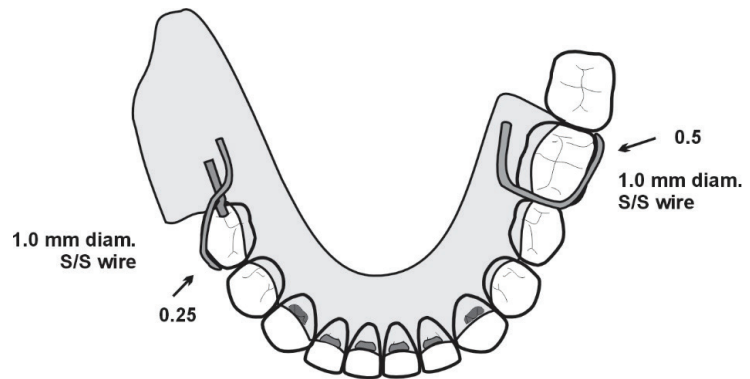
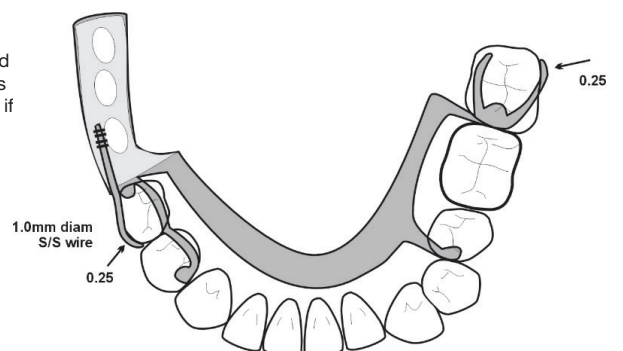


Figure 9. The drawing, and the denture in the mouth for a metal-based denture. As with the acrylic-based design with no modification space, the distal undercut is engaged. There is, though, gingival coverage of the 35 because of the need to place a rest on the 34 to ensure a distribution of rests for stability. This gingival coverage can be corrected as in Figure 10.

Figure 10. The design from Figure 9 can be modified to ensure no gingival coverage. In this case the 37 is clasped so that more than one tooth is uncovered – if just one tooth is left open there is the real danger of hyperplasia of the gingiva.



Maxillary

Once again, the same principles apply, as illustrated in Figures 11-13.

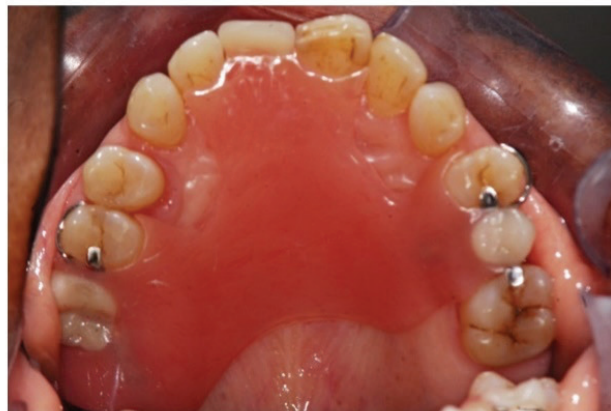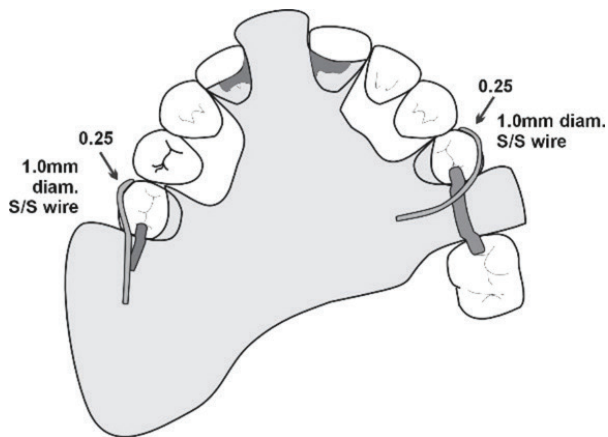


Figure 11. The drawing, and the denture in the mouth for an acrylic-based denture. The cingulum rests (which also provide indirect retention) will be continuous with the guide planes. The clasp on 15 is necessary but may show depending on the patient's smile. The clasp on the 14 will almost certainly show, and so a better aesthetic design is that shown in Figure 12.

Figure 12. An alternative design for the case shown in Figure 11. An additional benefit is that there is cross-arch reciprocation of clasps, with a mesial undercut engaged on the one side and a distal undercut engaged on the other.

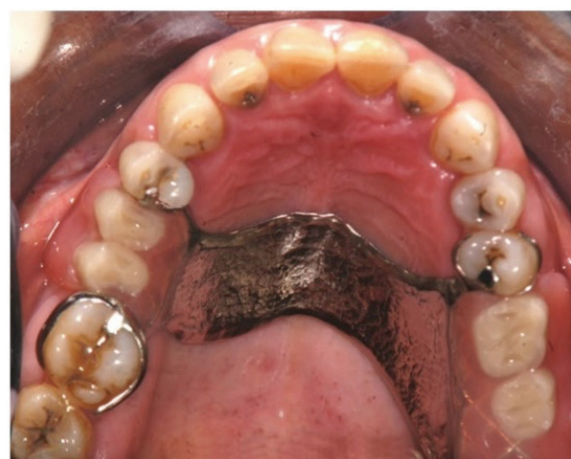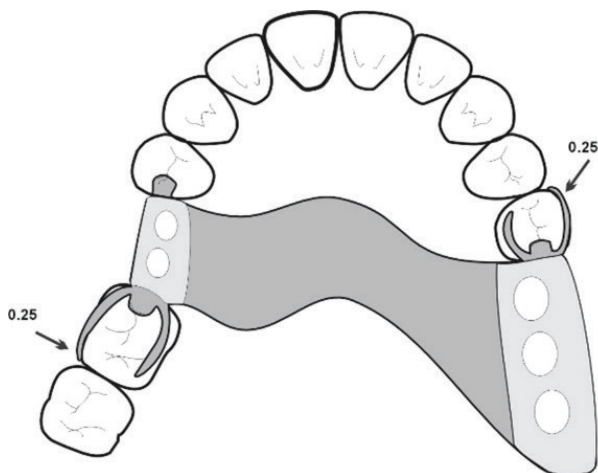
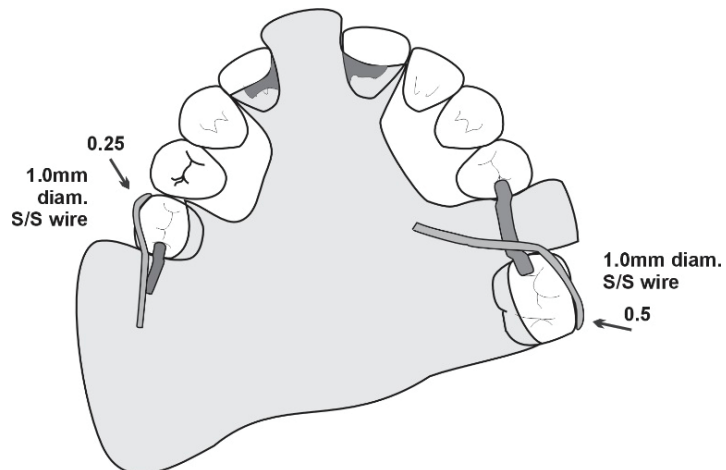


Figure 13. The drawing, and the denture in the mouth for a metal-based denture. Once again, cross-arch reciprocation of the clasps is an added benefit. No indirect retention was considered necessary.

KENNEDY CLASS III

The design for these dentures should be comparatively easy and can be kept simple, though they are often overly complicated. Depending on the number of edentulous spaces, and the size and length of the guide planes, many Class III dentures can rely on guide plane retention without the need for clasps.

Mandibular

As with all acrylic-based dentures, covering many gingival margins is unavoidable. Posterior spaces are often difficult because a lone standing distal molar is often left, and tends to tip mesially (because of the space) and often lingually (under the influence of the masseter). Therefore, there is usually no buccal undercut region and so these teeth can seldom be clasped; but they must of course receive a rest and will require slightly more modification than usual to create a guide plane.

Design examples

Figure 14 shows a typical design for an acrylic-based denture and Figure 15 illustrates that with enough guide planes, clasps may not be necessary. Figure 16 shows a typical framework-based design.

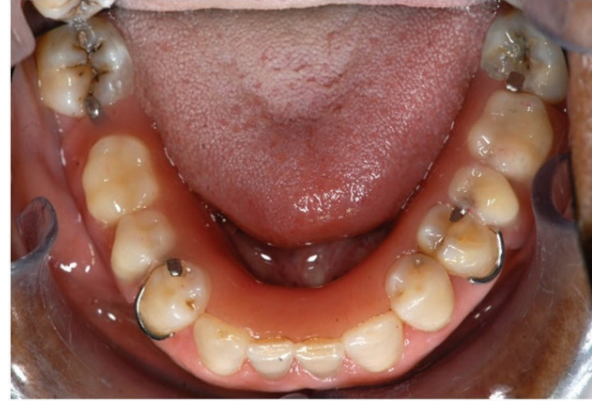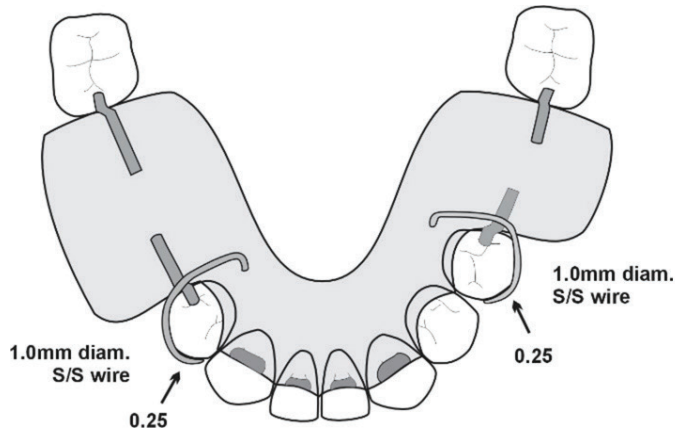


Figure 14. The drawing, and the denture in the mouth for an acrylic-based denture. The molars are not clasped because they are tilted and have no buccal undercuts.

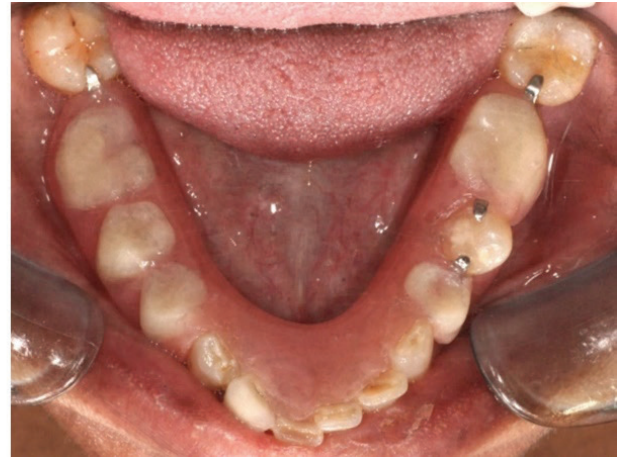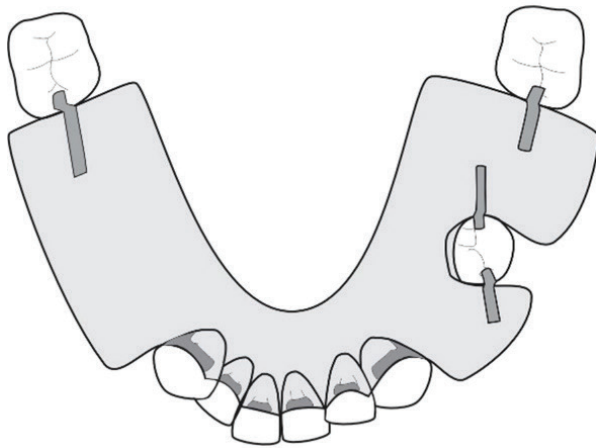


Figure 15. The drawing, and the denture in the mouth for an acrylic-based denture that was deemed to have sufficient number and size of guide planes as to obviate the need for clasps. The lone standing premolar must always receive both mesial and distal rests.

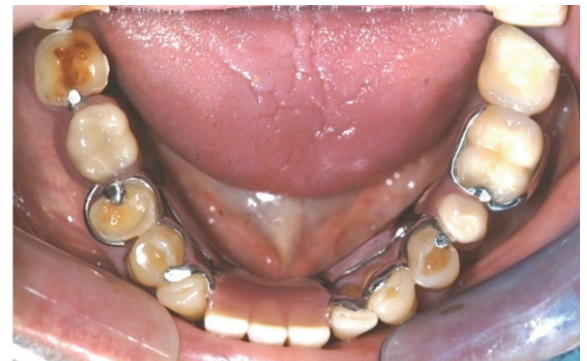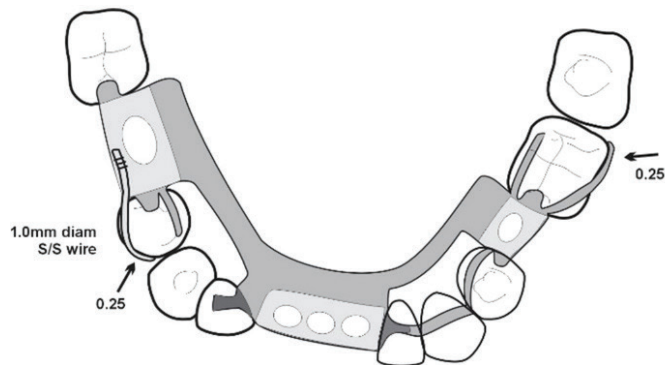


Figure 16. The drawing, and the denture in the mouth for a metal-based denture. This is a somewhat complicated design, but was necessary to avoid using lingual plates. The result is that no gingival margins are covered.

Maxillary

As with the mandibular designs, the maxillary Class III denture designs will depend entirely on the form and number of edentulous spaces. The more spaces there are, the more obvious the design will be because of the design principles such as the need for support on either side, the need for guide planes etc.

Design examples

Single edentulous space examples have been chosen here because they illustrate the need to consider where support should be placed, and the need for active retention (Figures 17-19).

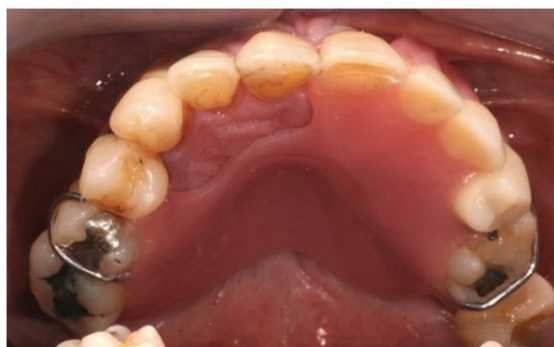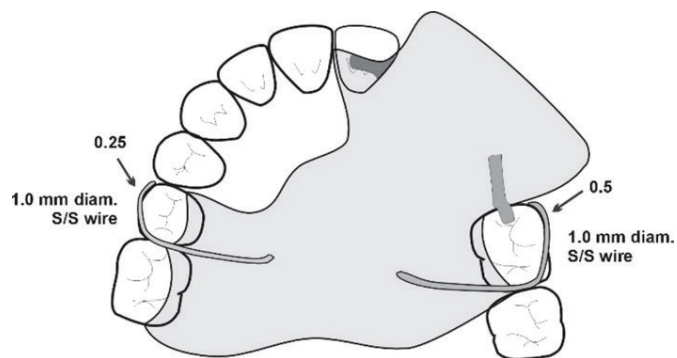


Figure 17. The drawing, and the denture in the mouth for an acrylic-based denture. The saddle is mostly anteriorly placed, and so its rotation must be considered, hence the use of mesial undercuts for the clasps, which also act as rests as they pass over the embrasures.

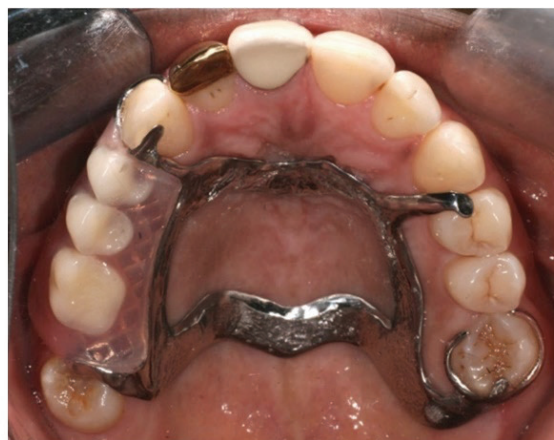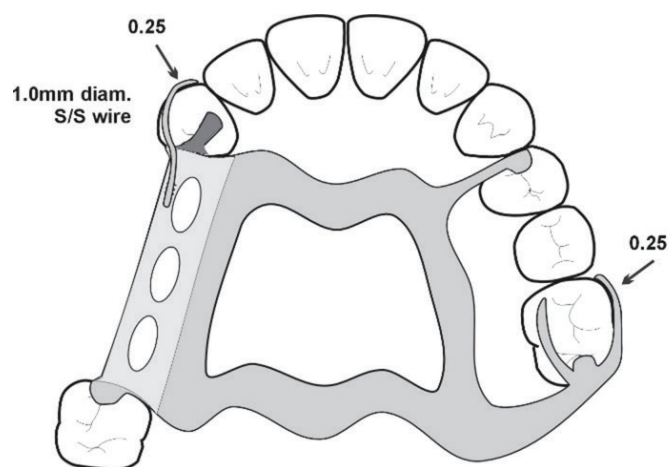


Figure 18. The drawing, and the denture in the mouth for a metal-based denture. The rest on the 24 is necessary for stability. Even though the rests on the right side and on the 26 form a tripod, it should be clear that it will not be as stable as including a rest on the 14.

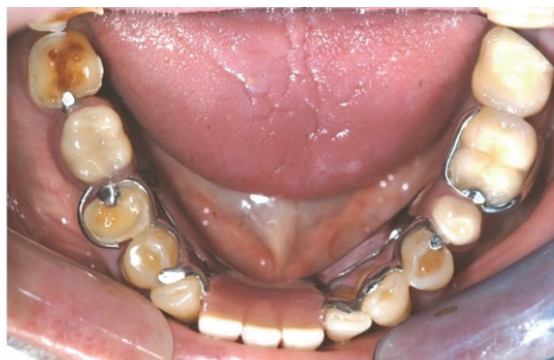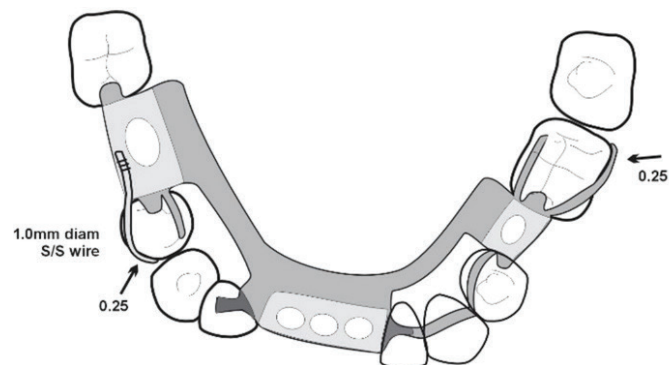


Figure 19. The drawing, and the denture in the mouth for a metal-based denture without clasps.

KENNEDY CLASS IV Mandibular

As discussed in Part 3² the design of these dentures depends entirely on whether the clinician believes that the predominant displacing action is a rotation of the anterior part downwards and forwards from incising or upwards from chewing sticky foods. Once again there is only anecdotal and experiential evidence, and that advice is that these dentures tend to tip up posteriorly, not anteriorly, and hence the use of distal undercuts for the clasps. The designs are therefore straightforward, and once again the difference between an acrylic base and a framework base is the gingival coverage.

Design examples Mandibular

Figures 20 and 21 show typical designs for acrylic-based and framework-based dentures.

Maxillary

The rotation of these dentures is always considered as downwards from the anterior generally because of the poor guide planes anteriorly. But when the guiding surfaces on the denture are developed in the mouth, the retention of the anterior segment greatly improves. The retention is also improved by using the mesial undercuts of the distal most appropriate tooth (Figures 22-23).

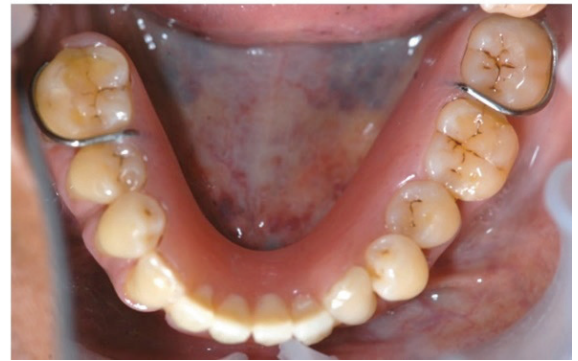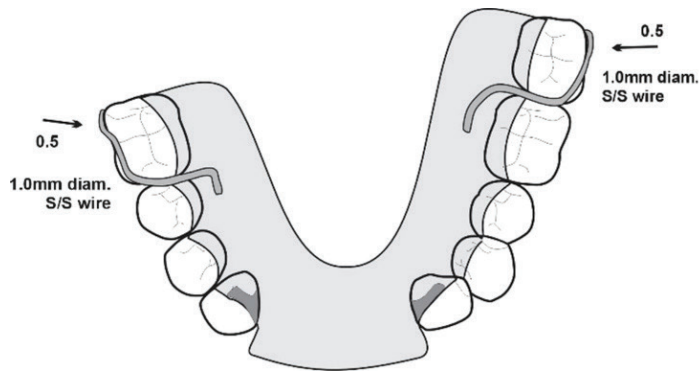


Figure 20. The drawing, and the denture in the mouth for an acrylic-based denture.

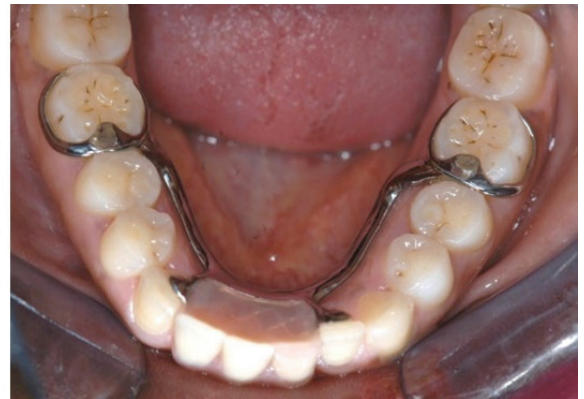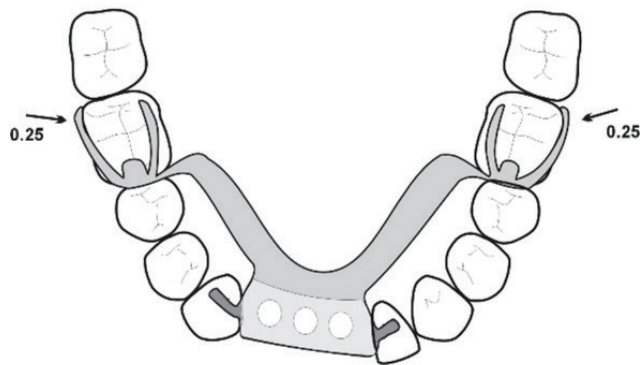


Figure 21. The drawing, and the denture in the mouth for a metal-based denture.

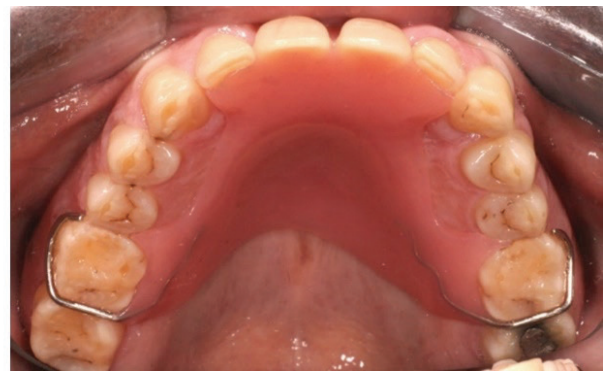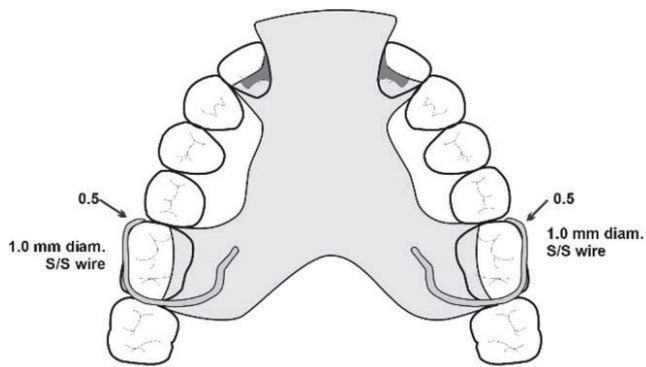


Figure 22. The drawing, and the denture in the mouth for an acrylic-based denture. Note that it is not necessary to festoon the acrylic around all the teeth, but only the teeth with cingulum rests (the lateral incisors in this case) and the teeth being clasped, to provide reciprocation. The clasps also act as rests as they sit in the embrasure.

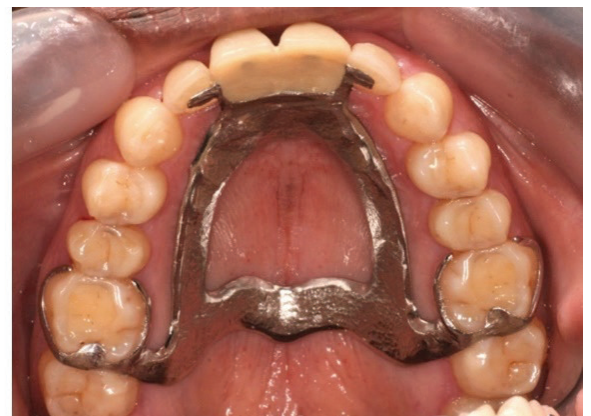
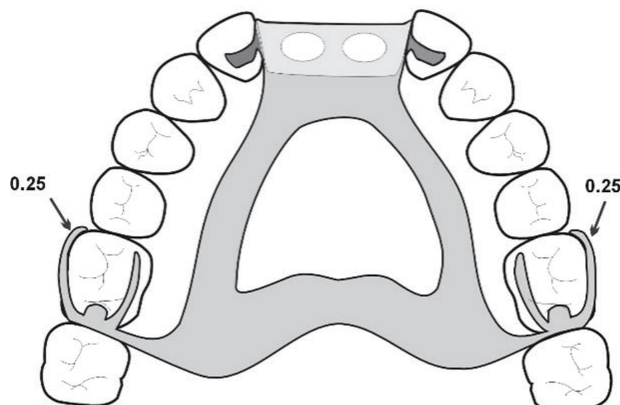


Figure 23. The drawing, and the denture in the mouth for a metal-based denture for a similar case as Figure 22, with two missing central incisors.

DISCUSSION AND CONCLUSION TO THE SERIES

There are, of course, many more aspects to the design and use and making of removable partial dentures, but these papers were intended to try to simplify many of the somewhat confusing aspects of partial denture design to be found in the literature, and deliberately concentrated on the basic forms of acrylic-based and framework-based dentures, with no other support such as from implants. These are the partial dentures that are available to most patients worldwide. There is a paucity of evidence for any specific design features, and in fact there is evidence to the contrary for some long-held beliefs such as that torquing forces and clasp assemblies result in the loss of teeth.

There are many factors that contribute to the increased rate of tooth loss among partial denture wearers, but if simple and hygienic designs are used, the denture itself is unlikely to contribute. Although it has been shown that the amount of bone support prior to receiving an RPD was not a risk factor,⁸ this has been contradicted by other studies investigating the crown-root ratio of abutment teeth;^{9,10} all such studies, though, point to what are really multiple biological factors such as occlusal support, root canal treatment and alveolar bone density. There is little doubt, though, that the greatest single contributor to tooth loss in RPD wearers is insufficient plaque control, and it should be a *sine qua non* that no prosthesis should be placed in a patient who cannot control biofilm through their own oral hygiene measures as well as with professional help.

There is also little doubt that RPDs contribute to patients' quality of life, especially when they fulfill the needs for aesthetics and improved chewing, and even in the presence of periodontal disease.¹¹ As discussed in Part I¹² there may be some association between chewing and cognition and a recent study suggested that the use of dental prostheses might be a protective factor for cognitive decline.¹³ It has even been suggested that the use of RPDs may have

long-term benefits in reducing mortality, although it was acknowledged that further research is necessary.¹⁴

The majority of partially edentate people in the world will not be able to afford a fixed or implant-supported prosthesis merely because the majority of people in the current world order are poor. The removable partial denture will continue to have a place in the therapeutic regimen and it is hoped that this series of papers will encourage better designed, non-iatrogenic prostheses for everyone who needs them.

REFERENCES

1. Owen CP. 2020. Fundamentals of removable partial dentures, 5th Edition. Electronic book available at www.appropriatech.com
2. Owen CP. A simplified approach to removable partial dentures. Part 3. The biomechanical basis of retention. SADJ. 202?
3. Yoshimoto T, Hasegawa Y, Maria MTS, Marito P, Salazar S, Hori K, et al. Effect of mandibular bilateral distal extension denture design on masticatory performance. J Prosthodont Res. 2023 4. doi: 10.2186/jpr.JPR_D_22_00135. Epub ahead of print
4. Chandler JA, Brudivik JS. Clinical evaluation of patients eight to nine years after placement of removable partial dentures. J Prosthet Dent. 1984;51(6):736-43. doi: 10.1016/0022-3913(84)90366-4
5. Yoshino K, Ito K, Kuroda M, Sugihara N. Survival Rate of Removable Partial Dentures with Mandibular Bilateral Free End Saddle: A Retrospective Study. Bull Tokyo Dent Coll. 2021;62(4):205-14. doi: 10.2209/tdcpublication.2020-0061
6. Frank RP, Brudivik JS, Leroux B, Milgrom P, Hawkins N. Relationship between the standards of removable partial denture construction, clinical acceptability, and patient satisfaction. J Prosthet Dent. 2000;83(5):521-7. doi: 10.1016/s0022-3913(00)70008-4
7. Lee JH, Chen JH, Lee HE, Chang HP, Chen HS, Yang YH, Chou TM. Improved denture retention in patients with retracted tongues. J Am Dent Assoc. 2009;140(8):987-91. doi: 10.14219/jada.archive.2009.0308
8. Nisser J, Kisch J, Chrcanovic BR. Risk Factor Assessment for Survival of Removable Partial Dentures and Their Abutment Teeth: A Retrospective Analysis. Int J Prosthodont. 2022;35(5):598-608. doi: 10.11607/ijp.7457
9. Tada S, Ikebe K, Matsuda K, Maeda Y. Multifactorial risk assessment for survival of abutments of removable partial dentures based on practice-based longitudinal study. J Dent. 2013;41(12):1175-80. doi: 10.1016/j.jdent.2013.07.018
10. Watanabe C, Wada J, Mizutani K, Nagayama T, Uchida H, Shibata Y, Wakabayashi N. Radiographic predictive factors for 10-year survival of removable partial denture abutment teeth: Alveolar bone level and density. J Prosthodont Res. 2023;67(3):437-43. doi: 10.2186/jpr.JPR_D_22_00034
11. Gotfredsen K, Rimborg S, Stavropoulos A. Efficacy and risks of removable partial prosthesis in periodontitis patients: A systematic review. J Clin Periodontol. 2022;49 Suppl 24:167-81. doi: 10.1111/jcpe.13519
12. Owen CP. A simplified approach to removable partial dentures. Part 1. Evidence-informed design principles. SADJ. 202?
13. Bof de Andrade F, de Oliveira C, de Oliveira Duarte YA, Sabbah W, Bernabé E. Tooth loss, dental prostheses use and cognitive performance in older Brazilian adults: The SABE cohort study. Geriatr Gerontol Int. 2021;21(12):1093-98. doi: 10.1111/ggi.14290
14. Bashir NZ, Bernabé E. Removable partial dentures and mortality among partially edentulous adults. J Dent. 2022;126:104304. doi: 10.1016/j.jdent.2022.

CPD questionnaire on page 120

The Continuing Professional Development (CPD) section provides for twenty general questions and five ethics questions. The section provides members with a valuable source of CPD points whilst also achieving the objective of CPD, to assure continuing education. The importance of continuing professional development should not be underestimated, it is a career-long obligation for practicing professionals.

