

An evidence-based guide to occlusion and articulation. *Part 2: A guide to the evolution of the teeth and joint*

SADJ March 2022, Vol. 77 No. 2 p94 - p99

CP Owen¹

SUMMARY AND PREAMBLE TO THE SERIES

Although this is essentially a review, it has not been written in the passive, third-person style normally associated with scientific writing, as it is intended to be thought-provoking and, hopefully, educational. It has therefore been written in more of a conversational style, and is aimed at students, dentists and dental technicians who are receptive to a slightly different view of occlusion and articulation, based on evidence.

Occlusion is a topic that has become a kind of archaic minefield of conflicting ideas, propositions, and above all, solutions, most of which are based on a complete lack of understanding of the evolution and development of teeth, and by extension, of clinically objective evidence.

That in itself is a statement of conflict (and perhaps even heretical), but it is by way of warning that this guide is not going to be much like anything you will find in standard text-books of dentistry or dental technology. It is, rather, an attempt to help you navigate through what you will read elsewhere, in the hope that eventually you will find an understanding that you can live with. It will appear as a sequential series in 7 Parts.

A guide to the evolution of the teeth and the joint

Note: some of this material is to be found in an eBook on *Lingualised Occlusion*,¹ to be found at www.appropriatech.com.

The evolution and development of the dentition and temporomandibular joint is a useful study in that it gives us clues as to how our present dentition functions (or rather how it is supposed to function naturally).

We are, of course, mammals, and mammals evolved from a group of "mammal-like reptiles" about 310 - 190 million years ago. Reptiles cannot bring their upper and lower teeth together and cannot chew. Their teeth can be of different shapes depending largely on their diet, and only a few reptiles (such as crocodiles) have teeth in sockets. Fig. 1



Fig. 1. Thrinaxodon (from <http://morgana249.blogspot.com/2014/08/5-ancient-mammal-like-reptiles.html>)

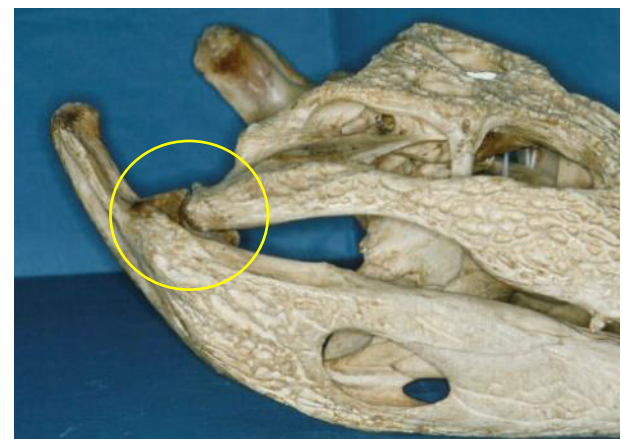


Fig. 2. The jaw joint of a crocodile

is a mammal-like reptile reconstructed from fossil remains found in the Free State (South Africa). Thrinaxodon lived about 251 million years ago.

But by the time the earliest known mammal had evolved, these now had two sets of teeth, and the maxillary and mandibular teeth could be occluded. At the same time the jaw joint had to evolve from a simple joint between a bone of the mandible, as a shallow fossa-like depression and a condyle-like projection of a bone of the skull. This is what, for example, crocodiles still have (Fig. 2). It is only recently, with the discovery in China of mammal-like reptiles of about 120 million years ago, that this process of going

Author affiliations:

1. Owen CP: BDS, MScDent, MChD, FCD(SA), Professor Emeritus, Faculty of Health Sciences, University of the Witwatersrand Johannesburg, South Africa, ORCID: 0000-0002-9565-8010

Corresponding author: CP Owen

Professor Emeritus, Faculty of Health Sciences, University of the Witwatersrand Johannesburg, South Africa
Email: peter.owen@wits.ac.za
Cell: +27 83 679 2205

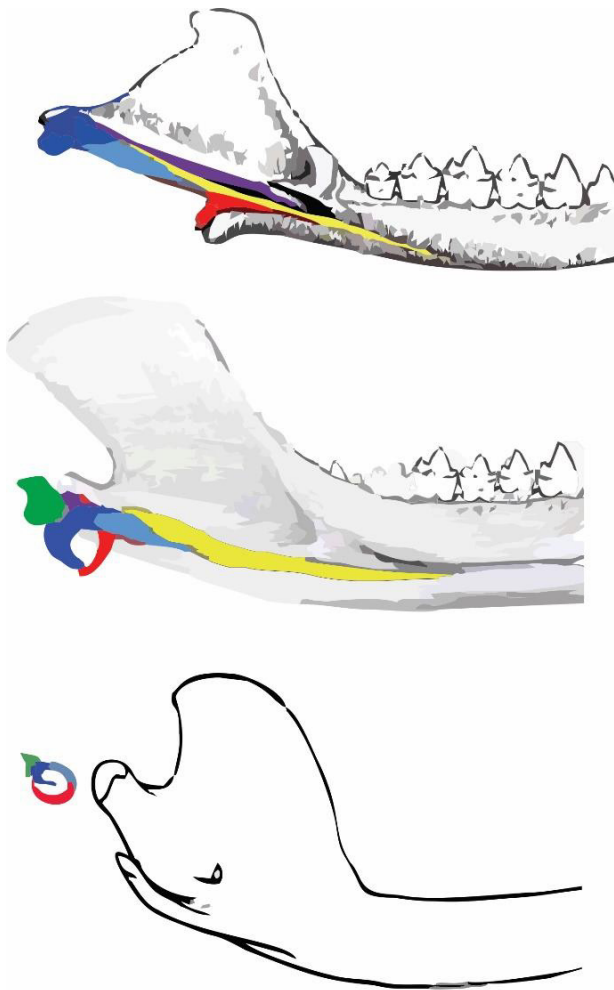


Fig. 3. Top: *Morganucodon* (about 200 million years ago). Middle: *Liaocoonodon* (about 120 million years ago). Bottom: modern mammal. Yellow = Ossified Meckel's cartilage. Dark Blue = malleus (was the articular). Light blue = Stapes. Green = incus (was the quadrate). Red = ectotympanic (re-drawn from Meng et al (2011)²)

from a reptilian joint to having a middle ear, has been better understood.² A middle ear is the defining characteristic of mammals, and an 'intermediate mammalian middle ear' seems to be the transitional phase. What has to happen, is that the reptilian ear has to transform so that the fossa-like part of the mandible (the articular) became the malleus of the middle ear and the condyle-like bone of the skull (the quadrate) became the incus. The other ear ossicles must also develop and it is thought this all happens by changes to the ossified Meckel's cartilage (Fig. 3).

What is extraordinary about this is that as this is happening (over millennia, don't forget), the jaw still needs to move and be used and allow movement, so that in the transitional phase, there exists what amounts to a double joint, so that the newly developed ear ossicles, external auditory meatus, tympanic bone and membrane continue to develop without interfering with jaw function, so that eventually the mammalian joint and middle ear became separate structures. Fascinating (well, I think so).

Now at the same time (sort of), the teeth were changing. Two important changes were the development of two sets of teeth (diphyodonty) and the development of the socket in which they were held. The fact that the jaw joint could now allow movements other than the up and down hinge (think

crocodile again), meant that the development of a joint that could allow lateral movements, allowed the newly evolved teeth to come into a definite relationship. Which is both good and bad, because now they could grind against each other and can wear.

Probably as a result of this, the development of two dentitions became useful. A primary dentition helps to solve the problem of providing a child with an effective masticatory apparatus appropriate to their needs at that time, and consistent with the space available in the jaws, which still have to grow. But the transition to a permanent dentition could be a problem; this is minimised by a really clever sequence of events: when the central incisors are lost, the primary lateral incisors and canines can be used to incise food; loss of the primary molars does not prevent crushing and grinding food because the first permanent molars are already in place before they are lost.

Now if you think of the unworn teeth with their steep cusps, it is difficult for them to fit together as they erupt, and this was solved by the development of a tooth socket that became a dynamic, changeable one, called a gomphosis, which means a ligament type attachment. This allows for movement within the bone (as those of you who have had orthodontic treatment will know), which importantly, allows the position of each tooth to be adjusted after eruption, in response to forces produced during chewing, and guided by the cusps, so that each tooth normally ends up in the most efficient position.

The development of the mammalian dentition and chewing apparatus is a great example of the wonder of evolution. But when reading this, I have presumed you are thinking of your own, human (I hope) teeth. Anatomically modern humans haven't been around for that long on the evolutionary scale of things, and whilst we were evolving so were other animals and they also had needs to eat and to at least tear off food and to chew it to a greater or lesser extent. Eating means having to pierce, crush, cut, shred, and grind food, depending on the food, and sometimes all of those things.

So once again, we come back to the issue of function, and to better understand how teeth with an inert outer layer on top of a living, organic layer are supposed to function, we need to take a short tour of the animal kingdom (at least those with teeth, mainly).

Different strokes for different folks: us and the rest of the mammalian animal kingdom

Herbivores

By which I don't mean human vegetarians, or vegans or whatever. Herbivores are animals who only eat plant food and have to extract as much as possible of what really amounts to very little nutrient material in each plant cell.

Plant cell walls are mainly cellulose, which we have great difficulty in digesting, but herbivores have a physiology and gut bacteria that can breakdown cellulose to produce energy. To release the cellulose, you have to really grind that material up; and to do that, you need teeth that are really rough. But mammalian teeth are enamel on dentine, held

in a ligament by cementum, as you know. So to evolve a rough surface, it makes sense to take advantage of the fact that each of these materials wear down at a different rate. So when they wear, some will wear more than others, and it further makes sense to make lots of cusps that can wear. Fig. 4 is an example. It is the just erupted last molar of a porcupine, and next to it is one that has erupted, the cusps of which have worn down. Fig. 5 is another example, of the 4 molars of a beaver, with the last one recently erupted and showing early wear.

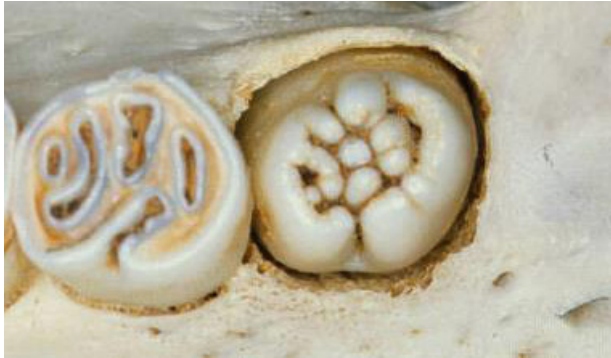

Fig. 4. A worn and unworn molar of a herbivore (in this case a porcupine)



Fig. 5. The molars of a beaver

The beaver's teeth are a good example of how the harder-wearing enamel remains as a sharp edge next to the softer and more rapidly wearing dentine and the cementum in between the multiple cusps. This is enlarged in Fig. 6. Note that the dentine, a living material and the calcified portion of the pulp, has reparative powers, and forms secondary dentine to block off the dentinal tubules. Otherwise this rapid wear would be very painful.

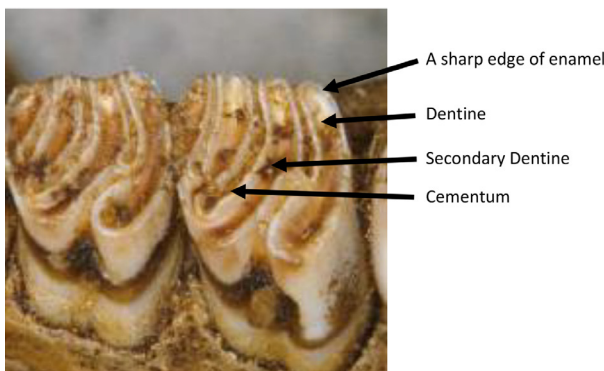


Fig. 6. The differential wear of the tooth materials creates an ideal rough surface for breaking down tough plant material.

So this differential wear creates an ideal surface for grinding plant material to extract the maximum nutrients from it. In one animal, which does not suckle its young, babies have to eat

straight away. This is the guinea pig, the original bruxers – the teeth erupt in utero, and the foetus grinds its teeth in utero so that by the time it is born, the cusps are worn into surfaces that can grind the food. Which makes one wonder why many of us with post-industrial revolution teeth, grind them ...

But (there's always a But) what happens when you have worn all your teeth down? The sad answer is you can no longer feed yourself and you die. The largest and longest-living herbivore is the elephant who has just 7 molars, but at any one time has the whole of one in the front and part of its replacement behind, until the front one is replaced, and so on until the last one is left, which erupts at about the age of 30 years, and will last another 30 years or so. Sad, but that's the life (and death) of a herbivore.

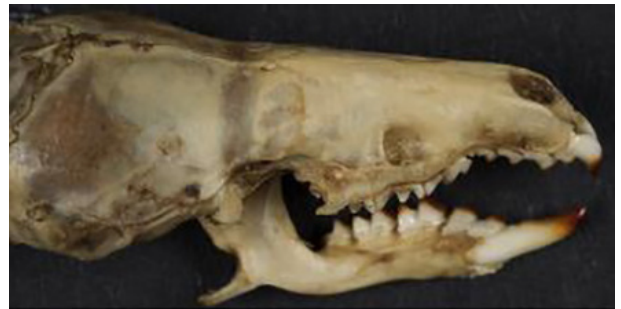

Fig. 7. Dentition of a shrew showing specialised incisors.

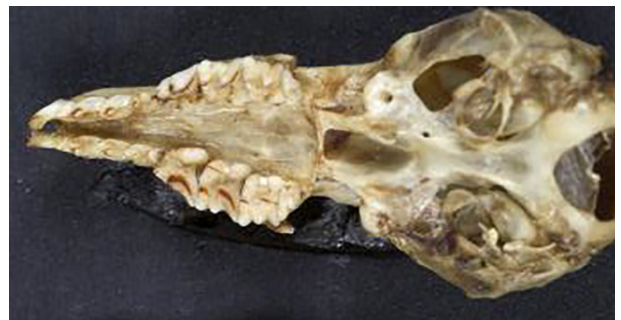

Fig. 8. The posterior teeth retain sharp cusps for piercing but also have a surface for crushing.

Insectivores

Animals that eat mainly grubs and insects really only need to pierce and crush the food, and so their dentition, like the herbivores, reflects this. A good example is the shrew, which has specialised incisors: the uppers are hooked, and the lowers contact them behind the tips, so that together they are used like forceps to pierce and grab prey (Fig. 7). The posterior teeth remain sharp but with surfaces that can crush (Fig. 8). But if these surfaces are used for grinding, the cusps would wear down, which is no use if you need cusps to remain sharp to pierce your food. So the system is set up to avoid this – insectivores have joints that do not allow for grinding, so the cusps do not wear, because there is no chewing in the sense of shredding and grinding. This action is more pronounced in the carnivores.

Carnivores

Carnivores of course, eat only meat and cannot digest plant material, which is why you should not feed your pet dog veggies. Dogs and cats are carnivores.

Carnivores are not that plentiful in the animal kingdom, mainly because they have to catch and eat many other animals over

their lifetime. So unlike herbivores this limits their life: not their teeth, but their ability to catch food. Unless of course they are domesticated, when they have trained humans to provide their food.

So now you need an entirely different dentition. You need teeth to help you bite and hold on to your prey, and you need teeth which will act like scissors to cut the chunks of meat up, and you need strong teeth and jaw muscles, to break up the bones. What you don't need to do, is chew anything, because your physiology will do the rest, just as herbivores' physiology sorts out their diet.

Fig. 9 is the joint of a herbivore on the left (a Rock Hyrax, or Dassie), and of a carnivore on the right (a Lynx). Note the complete freedom the herbivore's joint allows for free movement of the mandible, especially sideways, and contrast this with the restriction of the carnivore's joint to a purely hinge movement by virtue of the flanges on both the condyle and the fossa. No chewing is possible, which makes them messy eaters but efficient ones.

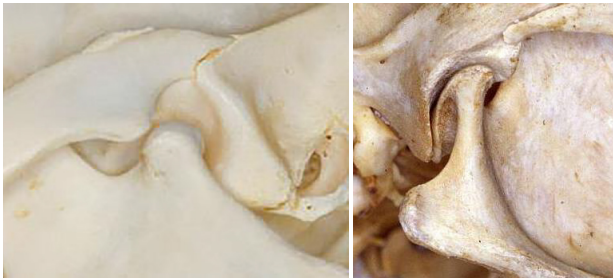

Fig. 9. An herbivore joint on the left, and a carnivore joint on the right.

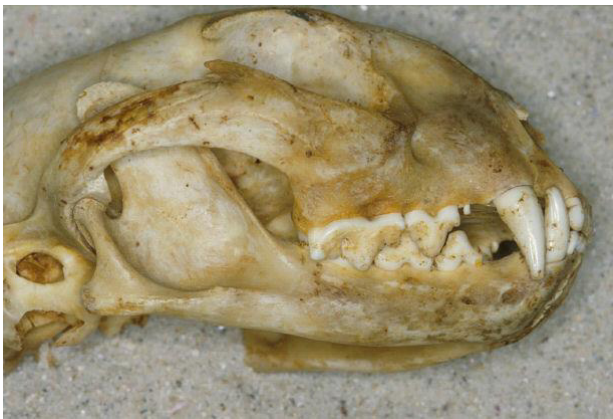

Fig. 10. The teeth of a carnivore (a Lynx).

And the teeth, not surprisingly do all the things we said they need to do (Fig. 10). There are canines for piercing and holding and choking, and carnassial (from French *carnassier* 'carnivorous', based on Latin *caro*, carn- 'flesh') teeth for shearing, and to help break bones. The mandible has a large ramus to accommodate the strong masseter muscles needed to hold on to prey and break bones. The most efficient at the latter, being the Spotted Hyena (Fig. 11).

Omnivores: the Primates and Us

So if you want to get to the top of the food chain, then you need to be able to eat everything! Omnivore is derived from the Latin *omnis*, meaning 'all or everything' and *vorare*, meaning 'to devour or eat'. So now you need a physiology that can cope with plants and meat, and you need teeth

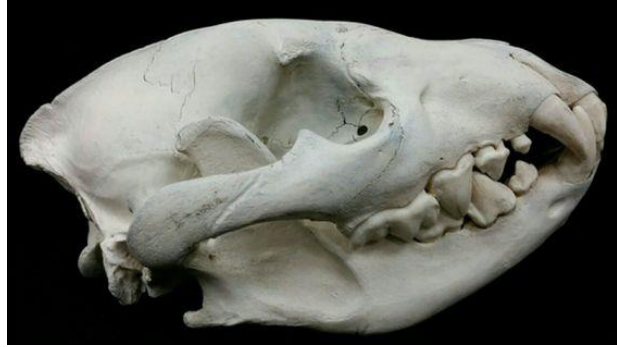

Fig. 11. Spotted Hyena

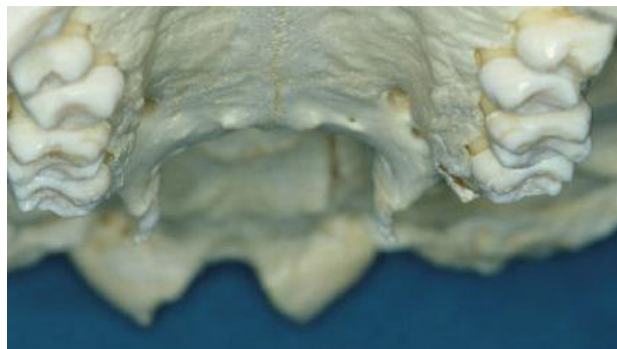

Fig. 12. The posterior teeth of a chimpanzee

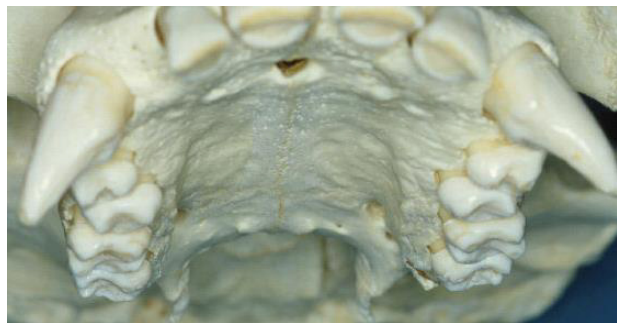

Fig. 13. The maxillary arch of a chimpanzee

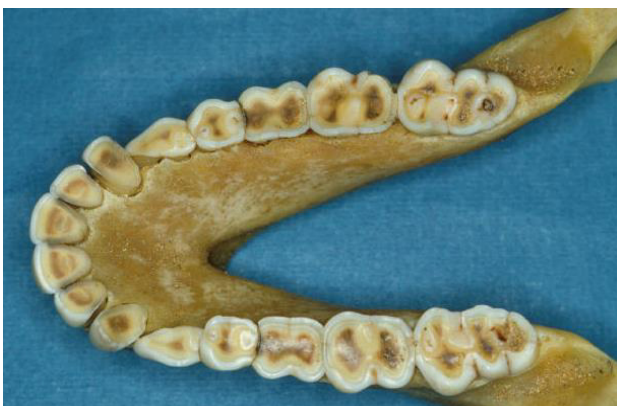

Fig. 14. The mandibular teeth of an adult Baboon

that can bite, cut, and chew. And depending on how easy or not it is to get the meat, you may still need pretty good canines, unless you can evolve intelligently enough to use tools to do the job of hunting and catching, in which case you may not need them. The latter is us, the former is the primates, our close cousins. So while our posterior teeth may look the same, our canines certainly don't! Fig. 12 shows the posterior teeth of chimpanzee. Look familiar? But if you look

at the entire dentition, the canines are, well, different (Fig. 13). These are the teeth of a young chimpanzee, whose posterior teeth are not fully erupted and still have all their cusps. They look remarkably like modern human teeth, and in fact they are no different. But now look at the teeth of an adult primate, this time a Baboon (Fig. 14).

They look a little different, but still familiar. They illustrate that in a natural environment, with a natural dentition, the food is quite tough to chew, so as an omnivore, you need a system that allows you to chew both meat and plants, fruits, nuts and so on, because the physiology of your digestive system needs to start working in the mouth. Now compare these teeth with those of a herbivore and you will see the same principle: a sharp rim of enamel remains, and the dentine shows secondary or reparative dentine as darker patches. The result is a great surface for chewing, without any annoying cusps getting in the way and interfering with jaw movement. And the joint of course, needs to allow for that movement as well. Which of course, it does.

This pattern is in all primates. It used to be in us as well, before we learnt to refine foods. We can thank (not really)

the Industrial Revolution for that, and we can thank (really) that for the need for the dental profession. Because since we started refining foods they got easier to chew, and our teeth no longer wear down, as they were meant to. Fig. 15 is from a 21-year old who lived about 10,000 years ago on the south-east coast of South Africa. The first molar, the first permanent posterior tooth to erupt, has lost its cusps. The premolars and second molar are showing signs of wear, and the third molar has only recently erupted.

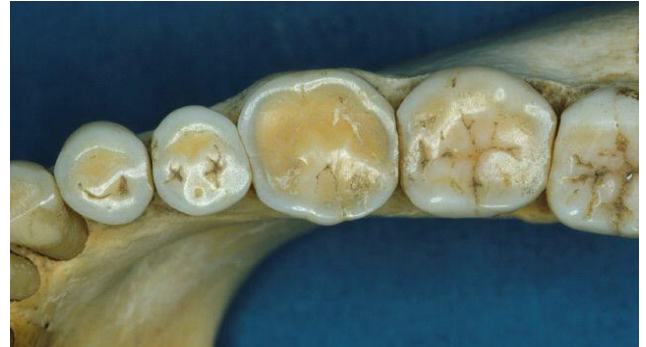

Fig. 15. The posterior teeth from a mandible of a young man who lived about 10,000 years ago.

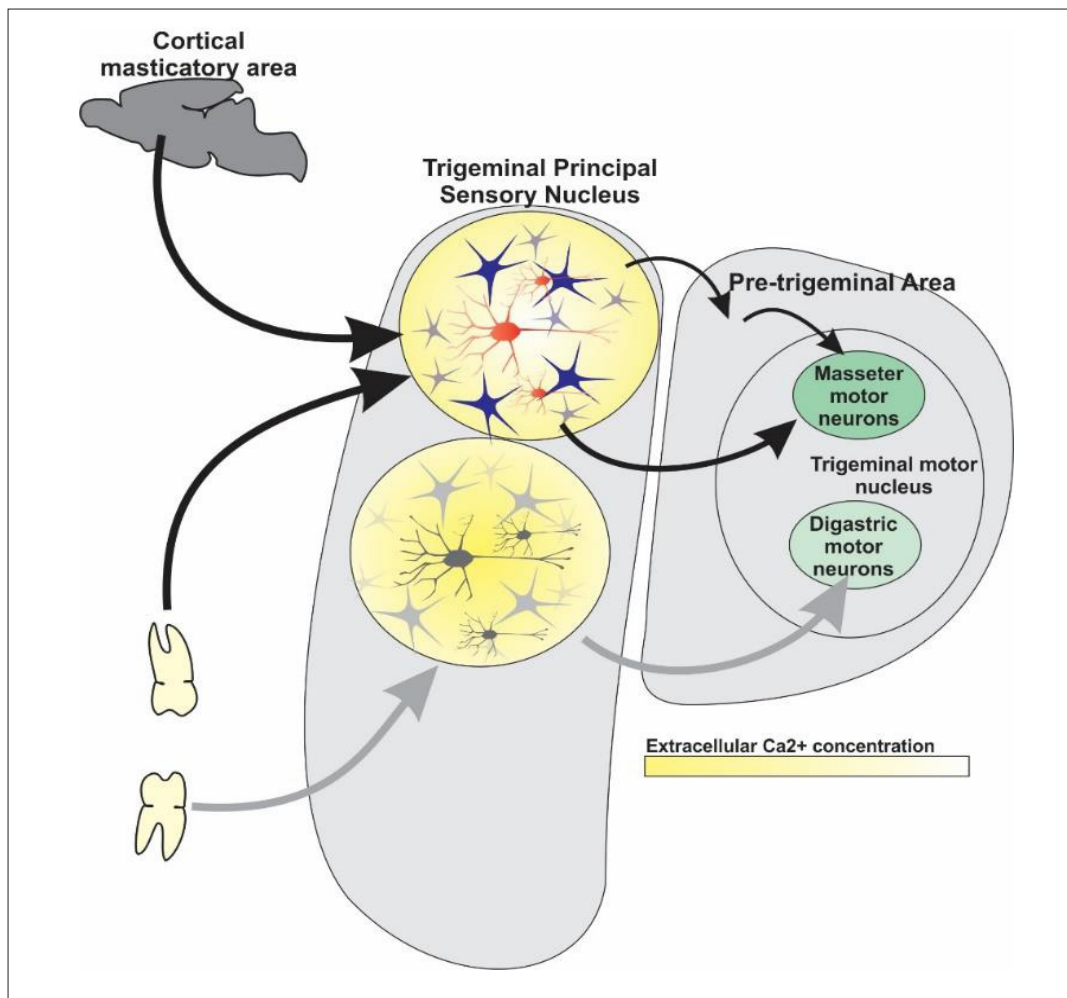


Fig. 16. Model of the masticatory Central Pattern Generator, re-drawn from Morquette et al 2012.⁴ Populations of neurons in the dorsal half of the principal nucleus of the trigeminal nerve are segregated in functional domains (yellow circles). Neurons are shown in red and black and astrocytes in blue and grey. In domains receiving weak afferent input (lower circle), the sodium current is poorly activated. In domains receiving greater inputs (upper circle), activation decreases the extracellular calcium and favours activation of the sodium current. This, combined with the common incoming input would synchronise the neurons and create a rhythm generator driving the motor neurons directly.

If you didn't know the origin of this mandible, from what we have discussed, you would (I hope) conclude that this is the dentition of an omnivore, eating a natural and quite abrasive diet. And as a coastal dweller and hunter-gatherer, this is logical, as the diet would certainly be an abrasive and of course, unrefined one.

In summary, then, Herbivores need teeth that can shred and grind, and so need lots of jaw movement to do so. Shredding needs sharp edges, grinding needs a surface, and circular jaw movements. Insectivores need teeth that need only to pierce and crush, and so need limited jaw movements. Carnivores need to cut and slice, and again only vertical movements are needed. Omnivores need to do everything, cut, pierce, crush, shred and grind and so need different types of teeth and a combination of movements.

So I hope this brief foray into the teeth and jaws of some representatives of the mammalian animal kingdom will help you to understand that we need to look at our teeth and our joints somewhat differently from the static and mechanistic view that seems to dominate most of the text-books on occlusion. I once suggested 3 that cusps are the cause of most of our problems in light of the Industrial Revolution, because refined foods increased the frequency of sugar intake, and this combined with the retention of cusps and fissures to retain plaque bacteria created a huge increase in caries, and the ease with which food could be chewed reduced the size of the jaws whilst the teeth stayed the same size and so third molars got impacted, teeth couldn't find a harmonious place, the joint found it hard to adapt because chewing patterns stayed the same and so maybe we should just whack off all the cusps soon after the teeth erupted! And all of that in one breath.

But seriously, the lack of physiological tooth wear is a problem, especially when we have to replace occlusal surfaces of teeth artificially. If replacing all of them, it could be less of a problem because we can then control those occlusal surfaces and produce shallow cusps and fissures. But when we need to replace a few, and the rest have cusps which have never shown any signs of wear, then we need to understand just how teeth with cusps can function within the system without causing problems with normal masticatory movements. Chewing after all, is natural and automatic. You don't have to volitionally make your mandible move to chew food, whether it is soft or hard. This is because chewing is under the control of the masticatory central pattern generator (CPG). This CPG is a network of what are referred to as rhythmogenic neurons in the trigeminal sensory nucleus. 4 Fig. 16 shows a model of the CPG. Because it is centrally generated, interference in the form of the teeth or an abnormality in the jaws, can upset the whole system and possibly give rise to often vague oro-facial pain often classified under the gamut of what have become known as Temporomandibular Disorders, or Cranio-Facial Disorders.

So the next paper in the series will look at the relationships between the teeth and the joints to better understand why the teeth are where they are.

REFERENCES

1. Owen CP. Lingualised Occlusion. An eBook module. Available at www.appropriatech.com
2. Meng J, Wang Y, Li C. Transitional mammalian middle ear from a new Cretaceous Jehol eutriconodont. *Nature*. 2011 Apr 14; 472(7342): 181-5. doi: 10.1038/nature09921.
3. Owen CP. The prophylactic reduction of cusps--is it desirable? *J Oral Rehabil*. 1986; 13(1): 39-48. doi: 10.1111/j.1365-2842.1986.tb01554.x.
4. Morquette P, Lavoie R, Fhima MD, Lamoureux X, Verdier D, Kolta A. Generation of the masticatory central pattern and its modulation by sensory feedback. *Prog Neurobiol*. 2012; 96(3): 340-55. doi: 10.1016/j.pneurobio.2012.01.011.