

# Perforation of the palate

## - A report of two Syphilitic Gumma cases

SADJ July 2020, Vol. 75 No. 6 p311 - p315

F Titinchi<sup>1</sup>, N Behardien<sup>2</sup>, J Morkel<sup>3</sup>, J Opperman<sup>4</sup>

### ABSTRACT

Syphilis has recently shown resurgence in its incidence especially in immune-compromised patients. We present two cases of tertiary syphilis in middle-aged males with large perforations in the hard and soft palates, one of which had Human Immunodeficiency Virus (HIV) co-infection. Diagnosis was initially difficult due to non-specific features mimicking other conditions such as perforation of cocaine abuse aetiology, neoplastic conditions, sarcoidosis, fungal infections, bacterial infections other than *Treponema pallidum* and Wegeners granulomatosis.

With special investigations including Anti-Treponema Immunohistochemistry and histology, however, a definitive diagnosis of syphilitic gumma was reached. Intravenous penicillin was the mainstay of management along with treatment of the underlying medical conditions.

A removable acrylic obturator was used to close the oro-nasal fistula to improve swallowing and speech. Syphilis should be included as a differential diagnosis in cases of palatal perforation.

### Keywords

Orofacial syphilis, *Treponema pallidum*, gumma, oronasal fistula.

### INTRODUCTION

Syphilis, a disease caused by the bacterium *Treponema pallidum*, is a sexually transmitted disease (STD). It may be acquired or congenital, with a variable clinical course.<sup>1</sup> The acquired form may present as primary, secondary, latent, or tertiary syphilis.<sup>2</sup> The various stages include presentations of ulceration (chancres) at the site of infection, lymphadenopathy, mucocutaneous rash, gummas, cardiosyphilis and neurosyphilis. All stages may present with oral lesions.<sup>3</sup>

Although the incidence of syphilis was significantly reduced after the introduction of penicillin in the 1940's, there has been a dramatic increase in its incidence recently.<sup>4</sup> The World Health Organisation (WHO) reported 6 million new cases of syphilis worldwide among individuals aged between 15 and 49 years in 2016.<sup>5</sup>

The resurgence of syphilis is a major concern to global public health, particularly due to the epidemiologic and biologic synergy of syphilis and Human Immunodeficiency Virus (HIV).<sup>6-8</sup> South Africa, with the largest HIV epidemic in the world, has 19% of the global number of people living with HIV, 15% of new infections, and 11% of Acquired Immuno-Deficiency Syndrome (AIDS)-related deaths.<sup>9</sup>

As a means to highlight the resurgence of this condition, we review the literature and present two explanatory cases of perforation of the palate resulting from syphilitic gumma, including the management thereof.

### CASE 1

A 35-year-old male was referred to the Department of Maxillo-Facial and Oral Surgery at Tygerberg Oral Health Centre citing a four-month history of an ulcerative lesion of the hard palate, which had recently become painful (Figure 1). He also reported swallowing and speech difficulties. A medical history revealed that he was HIV-positive and had pulmonary tuberculosis (TB), both of which he had defaulted treatment of. He also reported a history of a genital chancre (diagnosed by his referring physician and managed by oral antibiotics).

Extra-orally, bilateral submandibular lymphadenopathy was noted. Intra-orally, a large, well-defined (20 mm x 20 mm), punched out, ulcerative lesion involving the hard palate was noted. A second ulcerative lesion of approximately (10 mm x 10 mm) was noted on the soft palate. Based on the history and examination the differential diagnosis included tuberculous ulceration, actinomycosis and tertiary syphilis.

### Author affiliations:

1. Fadi Titinchi: BChD, PDD (Oral Surg), MSc, Lecturer, Department of Maxillofacial and Oral Surgery, Faculty of Dentistry, University of the Western Cape, Cape Town, South Africa.  
ORCID Number: 0000-0003-3182-7038 (Young Author Under 35)
2. Nashreen Behardien: BChD, MSc, PDD (Implantology), Senior Lecturer, Department of Maxillofacial and Oral Surgery, Faculty of Dentistry, University of the Western Cape, Cape Town, South Africa.  
ORCID Number: 0000-0003-2881-7891
3. Jean Morkel: BChD, MBChB, MChD, FCMFOS(SA), Professor and Head of Department of Maxillofacial and Oral Surgery, Faculty of Dentistry, University of the Western Cape, Cape Town, South Africa.  
ORCID Number: 0000-0003-3089-4597
4. Johan Opperman: BSc, BChD, PDD, MChD, Consultant Oral and Maxillofacial Pathologist. National Health Laboratory Services (NHLS), Cape Town, South Africa.  
ORCID Number: 0000-0002-9684-6670

### Corresponding author: Fadi Titinchi

Department of Maxillofacial and Oral Surgery, Faculty of Dentistry, University of the Western Cape, Tygerberg Oral Health Centre, Francie Van Zijl Drive, Cape Town, South Africa.  
Email: ftitinchi@uwc.ac.za

### Author contributions:

1. Fadi Titinchi: Identification of cases, literature review, manuscript preparation - 30%
2. Nashreen Behardien: Writing case reports and editing of discussion - 30%
3. Jean Morkel: Overall appraisal and final editing of manuscript - 20%
4. Johan Opperman: Histological sections and diagnosis - 20%

On haematological study, the haemoglobin and platelet counts were low, while erythrocyte sedimentation rate was increased. The absolute CD4+ T-cell count was very low at 12 cells/ $\mu$ L and the HIV viral load was 10139 copies /ml.

All other routine haematological parameters were within normal range. The Venereal Disease Laboratory (VDRL) test detected titre of 1:32, highly suggestive for syphilis.

Both T pallidum antibodies FTA-ABS and Rapid Plasma Reagin (RPR) were reactive, while a bacterial swab culture for *Actinomyces* was negative.

A biopsy of the palatal mucosa was done at the per-ulcer margins of the lesion in the hard palate. The histopathology showed non-specific features of fibrosis and plasma cells in adjacent margins as well as palisaded arrangement of fibroblasts and macrophages (Figure 2). This confirmed the clinical diagnosis of tertiary syphilis.

Medically, the patient was managed on intravenous penicillin (Pen G 2.4 million units 7-day interval). The gumma became necrotic and subsequently healed leaving a large oronasal fistula as seen on Computed Tomography (CT) (Figure 3). The fistula in the hard palate was obturated using a removable acrylic obturator, (Figure 4) while the ulcer on the soft palate did not require further management.

No surgical debridement was necessary. During the course of treatment at the Maxillo-Facial and Oral Surgery Department, the patient was referred to the Infectious Diseases Clinic for restart of the anti-retroviral and TB medication. Unfortunately, the patient demised 6 months later, and no further surgical treatment could be performed.

## CASE 2

A 28-year-old male presented to the Oral Pathology Clinic at Tygerberg Hospital with a main complaint of a 'hole' in the palate. He reported experiencing a 'blocked nose' for five months prior, had a yellow discharge from the nose, and reported aspirating food particles into his nose. The patient had a history of genital chancres and weight loss as reported by his referring general - practitioner. No other medical history of note was reported.

Extra-orally, bilateral nasal crusting with a nasal septal perforation was noted on Ear Nose Throat (ENT) examination. Intra-orally, a small, round perforation of the hard palate (2mm x 2mm) was noted as well as a large perforation of the soft palate (10 mm x 15 mm) with marked erythema of the uvula (Figure 5). Initially, a clinical differential diagnosis of *Granulomatosis with Polyangiitis* (Wegener's granulomatosis) was made.

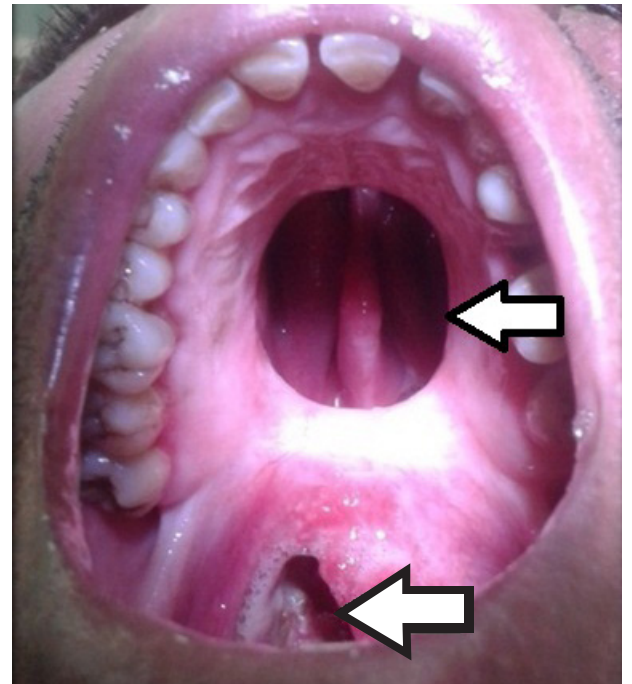
Special investigations included an incisional biopsy of the soft palate as it was more representative of the lesion; and the following haematological tests: full blood count; urea and electrolytes; HIV; rheumatoid factor; and Hepatitis B, and C. All test results were within normal range and hepatitis and HIV studies were negative.

Histopathological examination (Figure 6) demonstrated non-caseating granulomatous inflammation comprising of epithelioid histiocytes admixed with lymphocytes, plasma cells, and occasional multinucleated giant cells. Based on the histological findings along with the clinical picture, syphilitic ulcer and tuberculous ulcer were added to the list of differential diagnoses.

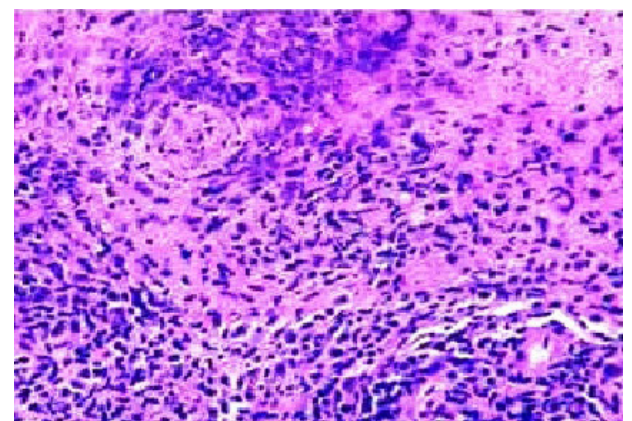
Special stains for fungal organisms and acid-fast bacilli were negative. Anti-Treponema immunohistochemistry however, was found to be positive for spirochetes (Figure 7).

An un-contrasted CT scan of the sinuses (Figure 8) displayed a destructive pattern centred on the hard palate and nasal cavity with septal perforation and erosion of the alveolar process .

The patient confirmed that he was managed previously with intravenous penicillin. Treatment included the construction of an acrylic obturator to improve phonetics and prevent food aspiration into the nose.

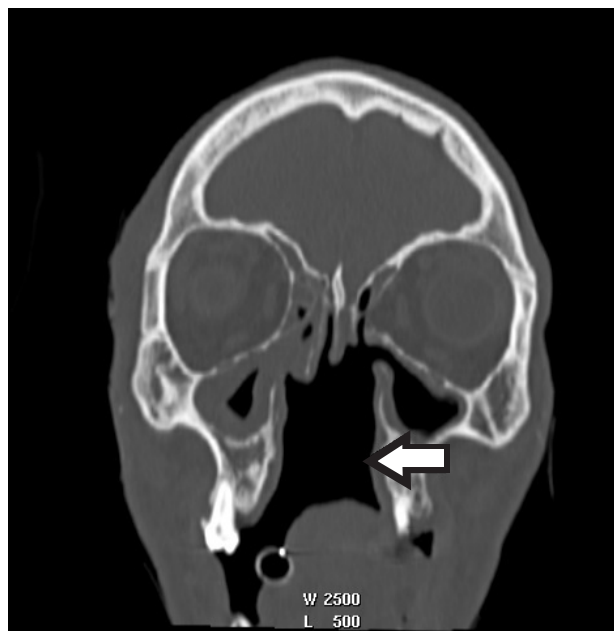


**Figure 1.** Intra-oral view showing ulcerative lesions in of the hard and soft palate post antibiotic treatment administered by referring physician.

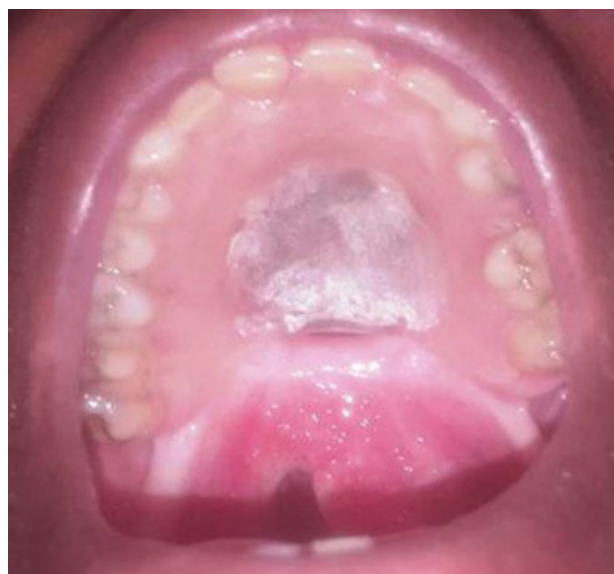

**Figure 2.** Histopathological specimen showing non-specific features of fibrosis and plasma cell infiltrate (H & E stain).

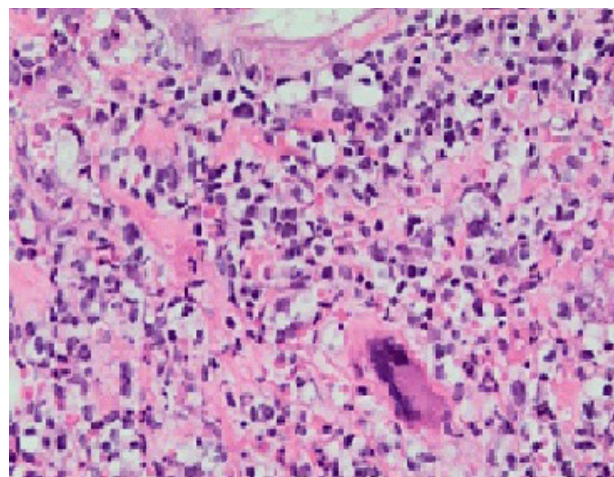




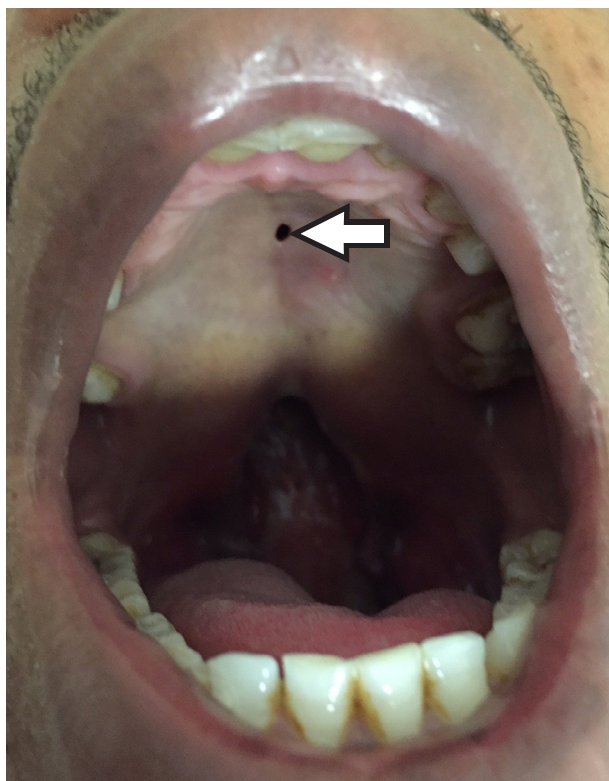**Figure 3.** Coronal computed tomography (CT) slice at the level of the hard palate clearly demonstrates the extent of destruction in the midline of the palate.



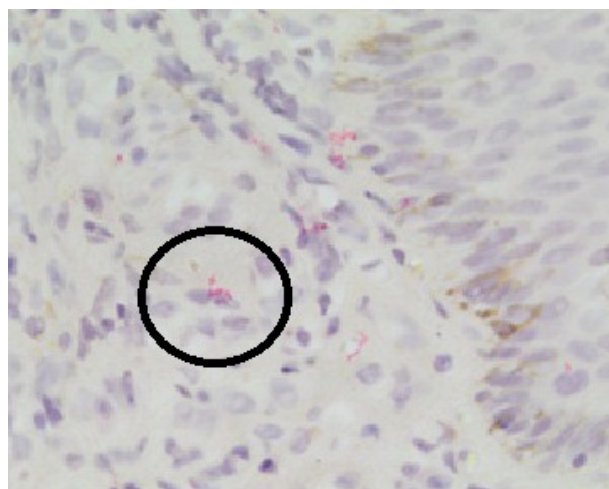
**Figure 4.** Intra-oral view of the acrylic obturator in place.



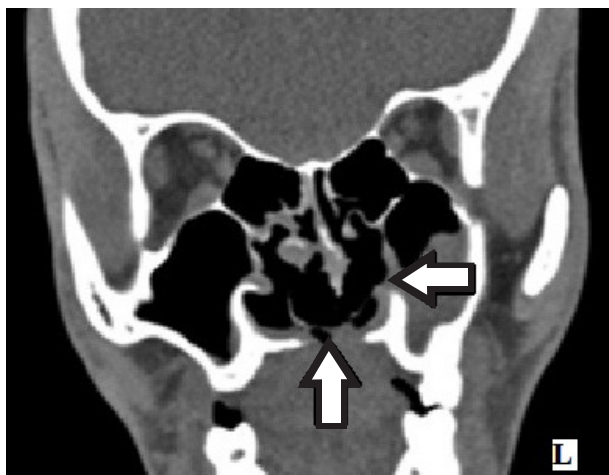
**Figure 6.** Non-caseating granulomatous inflammation showing multinucleated giant cells, lymphocytes and plasma cells obtained from the margins of the ulcerative lesion in the soft palate (H&E stain).



**Figure 5.** Intra-oral view showing ulcerative lesions in the hard palate.



**Figure 7.** Anti-Treponema Immunohistochemistry showing clumps of spirochete organisms (circled).



**Figure 8.** CT showing destruction of the hard palate involving the inferior turbinates on the left as well as erosion of the nasal septum.

DISCUSSION

Syphilis, as a differential diagnosis for perforation of the hard and soft palates, should be included due to the re-emergence of this condition. Syphilis can present in a myriad of ways, hence the name the “great imitator”<sup>10,11</sup>. Oral health workers should consider this entity as a differential diagnosis and ensure appropriate diagnostic tests.

Despite advances in diagnosis and treatment, syphilis remains endemic in sub-Saharan Africa and Southeast Asia, and it has re-emerged in several developed countries in the form of sporadic outbreaks and widespread epidemics.<sup>3</sup> The resurgence of syphilis is a major concern to global public health, particularly due to the epidemiologic and biologic synergy of syphilis and HIV.<sup>3,12</sup>

Tertiary syphilis can be defined as the appearance of new lesions in untreated patients after one year of primary lesions.<sup>13</sup> The typical notorious lesion of this stage is the ‘gumma’.<sup>13</sup> This is a granulomatous lesion, often found on the skin, bone, or liver.<sup>14</sup> Gummas can however involve any organ.<sup>15</sup> In the oral cavity, it is most commonly seen as a swelling on the tongue or hard palate, which eventually ulcerates.<sup>16</sup>

Gumma complications include bone erosion, palatal perforation, and oro-nasal fistulas.<sup>14</sup> Gummas of the oral mucosa usually affect the hard palate and typically start with a well-defined central ulcerative lesion, gradually increasing in size and later perforating the nasal cavity. Due to the risk of malignant change, biopsy is recommended biannually.

Gummas are often asymptomatic but very destructive if not managed timely. Perforation of underlying structures can lead to permanent deformity. Systemic complications can seriously affect the cardiovascular and nervous systems but are rarely seen.<sup>14</sup> Although oral tertiary syphilis lesions were described to be rare by Barrett in 2004,<sup>16</sup> its resurgence is evident by the presentation of cases in recent years.<sup>2,11,17</sup> The literature reports on eight cases of oral tertiary syphilis specifically relating to the hard palate (Table 1).<sup>2,4,11,17-21</sup>

All reported cases, including these two, presented in middle aged males (mean age 48.8 years). Three cases presented with HIV co-infection.<sup>14,20,21</sup> Six cases affected the hard palate,<sup>2,4,11,17-19</sup> while two cases affected the soft palate.<sup>20,21</sup> Unlike the two current cases, none of the cases in the literature simultaneously affected both hard and soft palate.

The clinical presentations ranged from sequestra formation, ulceration and clefting. This occurs as the lesion initially starts out as a painless ulceration and is commonly misdiagnosed.

The gumma is a highly destructive and rapidly expanding lesion that eventually leads to perforation of palate and the formation of a large oronasal fistula.<sup>2</sup>

The diagnosis for syphilis is dependent on non-treponemal tests, e.g. RPR, VDRL and treponemal anti-body specific tests e.g. Fluorescent Treponemal Anti-body Absorption (FTA-ABS), *Treponema Pallidum* Haemagglutination test (TPHA) and *Treponema Pallidum* Antibody test (TPAB), a chemiluminescent immunoassay.<sup>22</sup>

Non-treponemal tests uses antigens released during cellular damage caused by the organism, in serum and plasma e.g. lecithin, cholesterol and purified cardiolipin to detect antibodies against cardiolipin, which is present in many syphilis patients.<sup>22</sup> VDRL and RPR are flocculation tests used as initial screening for spirochete infection. These tests are relatively accurate but are not absolutely specific for syphilis and false positive reactions may occur in some cases.<sup>23</sup>

The National Health Laboratory Services (NHLS) at Tygerberg Hospital uses the reverse sequence algorithm testing for syphilis. These methods were employed in these cases. Whereas the traditional algorithm made use of a non-treponemal test (RPR) as a screening test, followed by a confirmatory treponemal test (FTA/TPHA), the reverse sequence algorithm starts with an automated treponemal screening test (TPAB) followed by, in those patients whose sera are reactive, a non-treponemal test (RPR) to determine disease activity.

The reverse algorithm offers increased sensitivity particularly in primary and tertiary syphilis but also in secondary syphilis where the prozone phenomenon may result in false negatives. It provides increased specificity at all stages of the infection due to fewer false positives.<sup>23</sup> Management of tertiary syphilis is summarized in Table 2. penicillin is the main treatment modality while obturators are a successful method of managing speech and masticatory problems. Reconstructive surgery is another option, but extensive scarring of syphilitic lesions renders surgical repair using local and regional flaps a challenge as ischaemia and necrosis render the tissues more likely to breakdown following surgical repair.<sup>17</sup> Free vascularised flaps in the form of a radial forearm flap is then often the optimal surgical solution.<sup>4</sup>

Table 1. Summary of previous cases published in literature on tertiary syphilis.

Author	Gender	Age	Site	Clinical presentation	Diagnosis	Treatment	Management of defect	HIV status
Huebsch (1955) <sup>18</sup>	M	33	Hard Palate	Sequestrum	N/A	N/A	N/A	N/A
Taylor and Hipple (1961) <sup>19</sup>	M	43	Hard Palate	Ulceration	N/A	Penicillin	N/A	N/A
Ramstad and Traaholt (1980) <sup>20</sup>	M	63	Soft Palate	Cleft	N/A	Penicillin	N/A	N/A
Kearns et al. (1993) <sup>21</sup>	M	43	Soft Palate	Ulceration	Biopsy	Penicillin	Surgical	Positive
Bains and Hosseini-Ardehali (2005) <sup>4</sup>	M	70	Hard Palate	Cleft	Serology	Penicillin	Palatal obturator	Positive
Murthy et al. (2014) <sup>11</sup>	M	48	Hard Palate	Cleft	Serology	N/A	Palatal obturator	Negative
Singh et al. (2015) <sup>2</sup>	M	55	Hard Palate	Cleft	Serology	Penicillin	Palatal obturator	Negative
Sharma and Sharma (2016) <sup>17</sup>	M	36	Hard Palate	Ulceration	Serology	N/A	N/A	Positive

**Table 2.** Management of palatal perforation due to tertiary syphilis.<sup>4</sup>

Initial phase	Antibiotics (Penicillin, Tetracyclines, etc.)
	Preventative advice and education
	Management of underlying medical condition
Conservative/ Non- surgical phase	Palatal obturators
	Speech therapy
Surgical/Reconstructive phase	Local flaps
	Regional flaps e.g. Tongue flaps
	Free flaps where the radial forearm flap is the most widely used
	Osseodistraction
Combination of Surgery and Prosthodontics	Implant supported obturators

## CONCLUSION

Tertiary syphilis presents with destructive gummatous lesions that can cause severe destruction to the orofacial regions. It is important to diagnose these lesions early with the aid of clinical and laboratory investigations. Management is aimed at eliminating the bacterial organisms with antibiotics and subsequent reconstruction of the defect.

## References

- Leão JC, Gueiros LA, Porter SR. Oral manifestations of syphilis. *Clinics*. 2006; 61(2): 161-6.
- Singh C, Parvathi D, Amarnath J. Destructive Potential of Spirochete: Perforation of Hard Palate: A Case Report. *IOSR Dent Med Sci Ver I*. 2015; 14(4): 2279-861. Available from: [www.iosrjournals.org](http://www.iosrjournals.org).
- Stamm LV. Global challenge of antibiotic-resistant *Treponema pallidum*. *Antimicrob Agents Chemother*. 2010; 54(2): 583-9.
- Bains MK, Hosseini-Ardehali M. Palatal perforations: Past and present. Two case reports and a literature review. *Br Dent J*. 2005; 199(5): 267-9.
- WHO. WHO guidelines for the treatment of *Treponema pallidum* (syphilis). WHO Libr Cat Data [Internet]. 2016; 1-51. Available from: [https://www.ncbi.nlm.nih.gov/books/NBK384904/pdf/Bookshelf\\_NBK384904.pdf%0Ahttp://apps.who.int/iris/bitstream/10665/249572/1/9789241549806-eng.pdf?ua=1%0Ahttp://www.bmj.com/cgi/doi/10.1136/bmj.2.398.180-b](https://www.ncbi.nlm.nih.gov/books/NBK384904/pdf/Bookshelf_NBK384904.pdf%0Ahttp://apps.who.int/iris/bitstream/10665/249572/1/9789241549806-eng.pdf?ua=1%0Ahttp://www.bmj.com/cgi/doi/10.1136/bmj.2.398.180-b).
- Stamm LV, Mudrak B. Old foes, new challenges: Syphilis, cholera and TB. *Future Microbiol*. 2013; 8(2): 177-89.
- Chesson HW, Heffelfinger JD, Voigt RF, Collins D. Estimates of primary and secondary syphilis rates in persons with HIV in the United States, 2002. *Sex Transm Dis*. 2005; 32(5): 265-9.
- Fleming DT, Wasserheit JN. From epidemiological synergy to public health policy and practice: The contribution of other sexually transmitted diseases to sexual transmission of HIV infection. *Sex Transm Infect*. 1999; 75(1): 3-17.
- Karp G, Schlaeffer F, Jotkowitz A, Riesenberger K. Syphilis and HIV co-infection. *Eur J Intern Med*. 2009; 20(1): 9-13.
- Maincent G, Labadie H, Fabre M, Novello P, Derghal K, Patriarche C, et al. Tertiary hepatic syphilis. A treatable cause of multinodular liver. *Dig Dis Sci*. 1997; 42(2): 447-50.
- Murthy V, Vaithilingam Y, Livingstone D, Pillai A. Prosthetic rehabilitation of palatal perforation in a patient with "syphilis: The great imitator." *BMJ Case Rep*. June 2014; bcr2014204259.
- Ho EL, Lukehart SA. Syphilis: using modern approaches to understand an old disease Find the latest version: Review series Syphilis: using modern approaches to understand an old disease. *J Clin Invest*. 2011; 121(12): 4584-92.
- Goh BT. Syphilis in adults. *Sex Transm Infect*. 2005; 81(6): 448-52.
- Leuci S, Martina S, Adamo D, Ruoppo E, Santarelli A, Sorrentino R, et al. Oral Syphilis: A retrospective analysis of 12 cases and a review of the literature. *Oral Dis*. 2013; 19(8): 738-46.
- Kampmeier RH. The Late Manifestations of Syphilis: Skeletal, Visceral and Cardiovascular. *Med Clin North Am*. 1964; 48(3): 667-97.
- Barrett AW, Dorrego MV, Hodgson TA, Porter SR, Hopper C, Argiriadou AS, et al. The histopathology of syphilis of the oral mucosa. *J Oral Pathol Med*. 2004; 33(5): 286-91.
- Sharma S, Sharma S. Palatal Perforation Secondary to Tertiary Syphilis: An Uncommon Presentation and Diagnosis of Exclusion. *Int J Oral Heal Dent*. 2016; 2(1): 56.
- Huebsch R. Gumma of the hard palate, with perforation: Report of a case. *Oral Surgery, Oral Med Oral Pathol*. 1953; 8: 690-3.
- Taylor R, Hipple W. Gumma of palate with negative standard tests for syphilis. *Oral Surgery, Oral Med Oral Pathol*. 1961; 14(7): 788-92.
- Ramstad T, Traaholt L. Destruction of the soft palate and nose by tertiary 'benign' syphilis. A case report. *J Oral Rehabil*. 1980; 7(2): 111-5.
- Kearns G, Pogrel MA, Honda G. Intraoral tertiary syphilis (gumma) in a human immunodeficiency virus-positive man: A case report. *J Oral Maxillofac Surg*. 1993; 51(1): 85-8.
- Seña AC, White BL, Sparling PF. Novel *Treponema pallidum* Serologic Tests: A Paradigm Shift in Syphilis Screening for the 21<sup>st</sup> Century. *Clin Infect Dis*. 2010; 51(6): 700-8.
- Henao-Martínez AF, Johnson SC. Diagnostic tests for syphilis: New tests and new algorithms. *Neurol Clin Pract*. 2014; 4(2): 114-22.