



Blood platelet counts, morphology and morphometry in lions, *Panthera leo*

L. DU PLESSIS*

Electron Microscope Unit, Department of Anatomy and Physiology, Faculty of Veterinary Science, University of Pretoria, Onderstepoort, 0110 South Africa

ABSTRACT

DU PLESSIS, L. 2009. Blood platelet counts, morphology and morphometry in lions, *Panthera leo*. *Onderstepoort Journal of Veterinary Research*, 76:317–321

Due to logistical problems in obtaining sufficient blood samples from apparently healthy animals in the wild in order to establish normal haematological reference values, only limited information regarding the blood platelet count and morphology of free-living lions (*Panthera leo*) is available. This study provides information on platelet counts and describes their morphology with particular reference to size in two normal, healthy and free-ranging lion populations. Blood samples were collected from a total of 16 lions. Platelet counts, determined manually, ranged between 218 and 358 x 10⁹/l. Light microscopy showed mostly activated platelets of various sizes with prominent granules. At the ultrastructural level the platelets revealed typical mammalian platelet morphology. However, morphometric analysis revealed a significant difference ($P < 0.001$) in platelet size between the two groups of animals. Basic haematological information obtained in this study may be helpful in future comparative studies between animals of the same species as well as in other felids.

Keywords: Counts, lion, microscopy, morphology, morphometry, platelets

INTRODUCTION

The important role that platelets play in haemostasis has been well documented (Jain 1993; Tablin 2000). Knowledge of their structure and function is therefore important as it may be the first indication of an underlying clinical condition or pathology that may lead to defective haemostasis. The value of comparative studies aimed at establishing basic haematological values has been recognized in recent years (Hawkey 1991). Whereas the haematology of the domestic cat has been well studied and documented, there are few reports on the blood picture of wild cats (Jain 1993; Pothiwong, Sakulwira, Prachammuang & Vethchagarun 2006). This is probably due to the fact that it is difficult to obtain

adequate numbers of blood samples from healthy animals in the wild. Samples used to derive such information are often from sick animals, laboratory animals or those kept in zoos which may yield misleading data regarding the situation in nature. For example, platelet numbers often exceed 1000 x 10⁹/l in laboratory mice (Jain 1993), whereas the normal platelet count range for two wild mouse species was reported to range between 190–340 and 208–446 x 10⁹/l, respectively (Moore 2000). Values from different laboratories may vary, and many factors may influence the blood picture (age, sex, time of day, excitation of animal and nutrition), but if all of these variables are taken into account, baseline values can still be established. In studies of this nature, individuals used for reference purposes should approximate as closely as possible such factors as the demographic origin, species, sex and diet of the pa-

* E-mail: lizette.duplessis@up.ac.za

tient. Ideally, different subsets of individuals with a defined health status should be selected to determine baseline values. In addition, many observations (optimally $n = 120$) are necessary to establish a reliable reference range (Lumsden 2000). However, this is in most cases not possible for wildlife species, with the result that a wide gap exists regarding reliable baseline haematological information for non-domesticated animals.

Limited information regarding the platelet count and morphology of lions is available. Jain (1993) reported on platelet counts of three young lions (under the age of 2 years), while Hawkey and Hart (1986) gave a platelet count range based on 32 adult lions kept in captivity. This study describes the platelet morphology, with particular reference to size, as well as giving an indication of the normal platelet count range, of two healthy lion populations from different locations in South Africa.

MATERIALS AND METHODS

Blood samples were collected from 16 adult or sub-adult lions (*Panthera leo*) of either sex. Eight of the lions were from the Venetia Nature Reserve in Limpopo Province, South Africa, while the other eight were from the Hluhluwe-iMfolozi Park in KwaZulu-Natal, South Africa. The animals were immobilized by darting them with either a mixture of medetomidine and Zoletil® (Logos Agvet, USA) or of Zoletil® alone. The Limpopo lions were immobilized as part of a management culling process, while the others were part of an immunological investigation. A veterinarian declared all the animals to be physically healthy with no obvious signs of disease prior to blood collection. Three tubes (Vacutainer®) of blood were drawn from the femoral vein approximately 30–60 min after the animals had been darted. The first blood collection tube containing EDTA as the anti-coagulant was used for the blood smears, which were stained with Wright's stain (Rapidiff®, Clinical Sciences Diagnostics, South Africa). The other two tubes containing acid-citrate dextrose (ACD) as the anti-coagulant were used for the preparation of samples for transmission and scanning electron microscopy (TEM and SEM) as described by Du Plessis, Botha & Stevens (1996). Manual blood counts were done using a light microscope (LM) (100x oil objective) on all the blood smears according to the method described by Jain (1993). Samples for ultrastructural studies were viewed with a JEOL 840 scanning electron microscope (JEOL Electron Optics Instrumentation, Japan) and Philips CM10 trans-

mission electron microscope (Philips Electron Optical Division, The Netherlands). Image analysis was performed on TEM images of the platelets cut perpendicular to the equatorial plane (Du Plessis *et al.* 1996) using the iTEM Soft Imaging System software (Olympus, Germany). A total of 195 platelets were measured. The data obtained were subjected to a one-way analysis of variance using the statistics module in SigmaPlot V11.0 (Systat Software Inc., San Jose CA, USA).

RESULTS

Platelet counts

Manual platelet counts performed on the blood smears of the eight lions from KwaZulu-Natal ranged from 250–358 $\times 10^9/\ell$, with an average count of 308 $\times 10^9/\ell$ (SD 41.2 $\times 10^9/\ell$), while the Limpopo lions' platelet counts ranged from 218–288 $\times 10^9/\ell$, with an average count of 250.2 $\times 10^9/\ell$ (SD 25.6 $\times 10^9/\ell$). The mean platelet count of all the lions combined was 275.5 $\times 10^9/\ell$ (SD 43.6 $\times 10^9/\ell$).

Microscopy

Light microscopy

On the Wright's-stained blood smears, platelets appeared round- to oval-shaped, variably sized and were activated, as indicated by the presence of numerous pseudopodia (Fig. 1). Purple-staining granules could be distinguished in the light pink-stained cytoplasm. The centralization of granules implied the presence of different stages of activation. Platelet clumping was seen in a few cases.

Electron microscopy

SEM confirmed the LM observations. Platelets appeared as bilaterally flattened discs (Fig. 2). Their size was not uniform, and a mixture of large and small platelets was observed. Pseudopodia commonly occurred, indicating activation of the platelets.

Most of the sectioned platelets appeared lentiform (Fig. 3) on TEM, with the occasional platelet which was cut through the equatorial plane exhibiting a round profile (Fig. 4). Some platelets appeared to be activated as indicated by the presence of pseudopodia and centralization of the cytoplasmic granules. The α -granules were of moderate electron-density and were generally round although other shapes were observed. Typical dense bodies and mitochondria were scattered throughout the cyto-

plasm. In platelets with little signs of activation, the peripheral band of microtubules was easily discernible either as small rings at the poles of the platelet (Fig. 3), or, in platelets sectioned in the equatorial plane, as a band of longitudinally oriented tubules located immediately beneath the cell membrane (Fig. 4). A well-developed surface connecting canalicular system was present. Glycogen granules were scattered throughout the cytoplasm, often pre-

senting in a cytoplasmic area devoid of other organelles. Occasionally an exceptionally large platelet was seen.

Image analysis

All the measurements of the Limpopo lion platelets were significantly larger than those of the KwaZulu-Natal lion platelets ($P < 0.001$) (Table 1). The as-

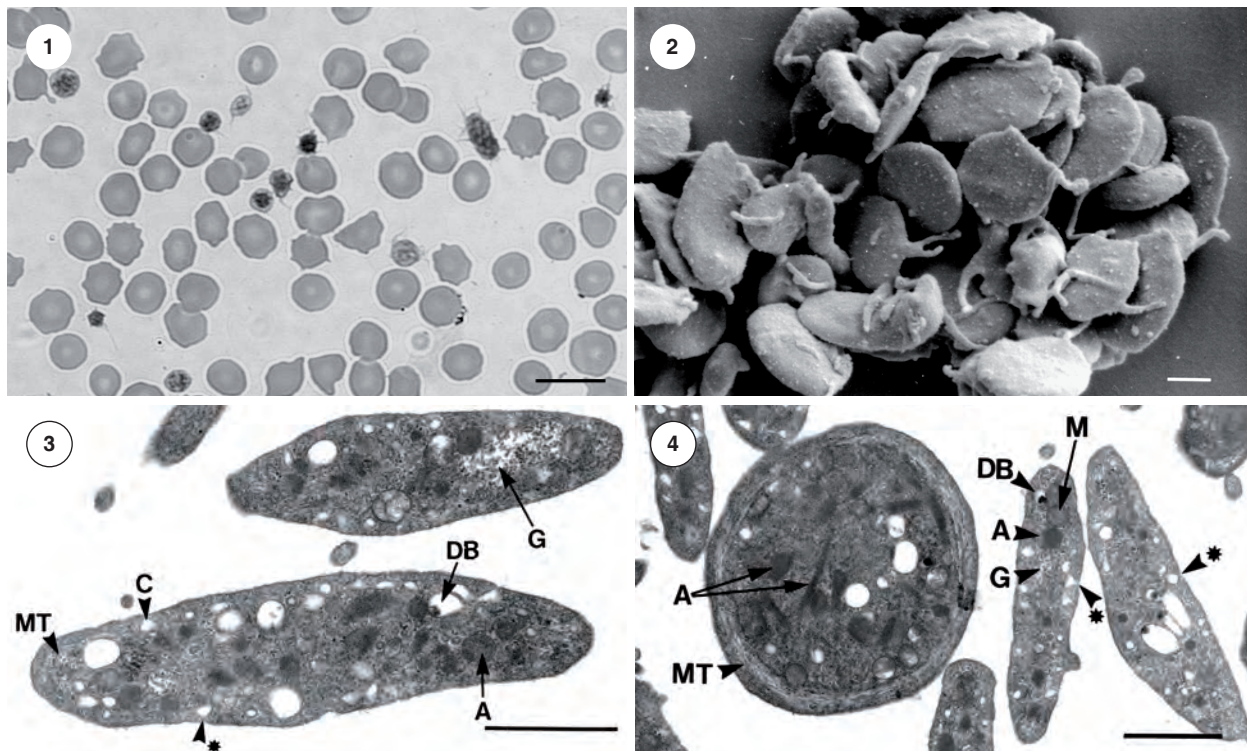


FIG. 1 Wright's-stained blood smear, Limpopo lions. Note the variably sized platelets scattered amongst red blood cells, the presence of pseudopodia, and granules in the platelets. *Bar = 10 μ m*

FIG. 2 SEM image of platelets, KwaZulu-Natal lions. Platelets appear as bilaterally flattened discs with pseudopodia. *Bar = 1 μ m*

FIG. 3 and 4 TEM images of platelets, KwaZulu-Natal lions. A few canalliculi (C) can be seen opening onto the cell surface (*). Note the different shapes of the α -granules (A). Microtubules (MT), dense bodies (DB), glycogen granules (G) and mitochondria (M) are clearly visible in the cytoplasm. *Bar = 1 μ m*

TABLE 1 Platelet measurements (mean \pm SD)

| Platelets | Perimeter (μ m) | Area (μ m ²) | Max. projection (μ m) | Min. projection (μ m) | Aspect ratio |
|----------------------|----------------------|-------------------------------|----------------------------|----------------------------|-----------------|
| Limpopo | | | | | |
| <i>n</i> = 87 | 8.61 \pm 1.13 | 3.31 \pm 0.83 | 3.56 \pm 0.53 | 1.35 \pm 0.23 | 2.74 \pm 0.58 |
| KwaZulu-Natal | | | | | |
| <i>n</i> = 108 | 7.15 \pm 0.81 | 2.15 \pm 0.46 | 3.01 \pm 0.39 | 1.03 \pm 0.18 | 3.11 \pm 0.73 |
| Total | | | | | |
| <i>n</i> = 195 | 7.80 \pm 1.21 | 2.67 \pm 0.87 | 3.25 \pm 0.53 | 1.18 \pm 0.26 | 2.94 \pm 0.69 |

n = number of platelets measured

pect ratio, as an indication of the cell shape, was significantly ($P < 0.001$) smaller in the Limpopo lions (2.74 ± 0.58), indicating that these cells were less oval-shaped or lentiform than the platelets of the KwaZulu-Natal lions (3.11 ± 0.73). The overall cell-shape of all the platelets was 2.94 ± 0.69 .

DISCUSSION

Hawkey, Hart, Bennett, Gascoyne, Knight & Kirkwood (1990) pointed out the importance of establishing normal blood cell ranges and that the potential value of platelet counts as an indicator of clinical abnormalities in adult mammals should not be overlooked. In some cases, for example in bovine species, it is known that the response of white blood cells to infection is minimal and that the platelet count is of more value for identifying and following the course of a bacterial infection. The platelet counts of the 16 lions examined in this study ranged from $218\text{--}358 \times 10^9/\ell$ with an average value of $275.5 \times 10^9/\ell$ (SD 43.6). This value is in line with an average value of $297 \times 10^9/\ell$ reported by Hawkey & Hart (1986) who based their findings on 32 captive lions. Information on lion platelet counts, however, remains sparse (see e.g. Jain 1993). While platelet numbers remain fairly constant within a species, values may vary widely between different species. Hawkey & Hart (1986) compared baseline haematological values for six felid species, all kept in captivity, and found that although there was an overlap in the range of the platelet counts, there were differences in the platelet counts of the different species. For example, the average lion platelet count is considerably lower than the $344 \times 10^9/\ell$ reported for cheetahs (Du Plessis, Botha, Reyers & Stevens 2004), confirming the differences in counts for different felid species. When comparing lion platelets with those of domestic cats, the situation becomes even more complex due to the wide range in values reported for the cat (Clinkenbeard & Meinkoth 2000). The general platelet count for the domestic cat ranges from $300\text{--}800 \times 10^9/\ell$, with an average of $450 \times 10^9/\ell$ (Jain 1993), but since different laboratories may not always use the same methods and instrumentation, they may report different reference ranges. For example, data compiled by Moritz, Fickenscher, Meyer, Failing & Weiss (2004) reveals that cats have an average platelet count of $281.34 \times 10^9/\ell$. In their comparative study, data gathered from Tvedten (1999, cited by Moritz *et al.* 2004) reflected a range of $230\text{--}680 \times 10^9/\ell$, whereas Kraft *et al.* (1999, cited by Moritz *et al.* 2004) reported a lower count of $180\text{--}550 \times 10^9/\ell$. While the platelet counts of the lions in the present

study correlate with some of these domestic cat values, the variations in figures again indicate the need for comparative studies and the use of standardized methods. The danger of generalizing values within a group of animals is also highlighted. Manual counts, although not accurate as different laboratories use different methods for the cell calculations (Jain 1993; Norman, Barron, Nash & Clampitt 2001), may give a more general reflection of the platelet status and the occurrence of platelet clumping. Stress or excitement of the animal at the time of sampling, a phenomenon known as the 'epinephrine effect', may also lead to an increase in platelet count and should be taken into consideration when interpreting platelet counts (Jain 1993).

The morphology of the platelets from the two groups of lions was similar. On LM they appeared activated as indicated by the presence of numerous pseudopodia, centralization of the granules and tendency to spread. However, this is not an uncommon finding in felids in which the cytoplasmic margins are often poorly defined, surface projections are often seen, and platelet clumping is observed (Norman *et al.* 2001). Ultrastructurally, the lion platelets fit the general description of circulating mammalian platelets, i.e. discoid with a smooth surface (Jain 1993; Tablin 2000). In addition, the platelet morphology revealed in this study, and that of the cheetahs previously described (Du Plessis *et al.* 2004), was similar. Platelets tend to be large in members of the cat family and giant forms equal in size to red blood cells may often be seen (Jain 1993; Zelmanovic & Hetherington 1998). Large platelets may be found in animals recovering from thrombocytopenia (Jain 1993) whereas young platelets are also large and granular (Sirios 1990). According to data compiled by Tablin (2000), mammalian platelets measure $5\text{--}7 \mu\text{m}$ in length and less than $3 \mu\text{m}$ in width, while Jain (1993) reported that platelets have a diameter of $2.5 \mu\text{m}$ whereas oval forms are $3.5 \mu\text{m}$ in length. Zucker-Franklin (1988) gave the long axis of $1.5\text{--}3.0 \mu\text{m}$ to be the norm. Although all the animals were declared healthy at the time of blood collection, significant differences were noted in the platelet dimensions of the two lion populations studied, with the Limpopo lions having larger platelets. However, the combined measurements of the lion platelets, i.e. $3.25 \pm 0.53 \mu\text{m}$ (max. projection) and $1.18 \pm 0.26 \mu\text{m}$ (min. projection), fell within the above reported ranges for mammalian platelets. When compared to those of cheetahs, however, the lion platelets were slightly larger than those of the cheetahs, which had maximum and minimum projections of $2.933 \pm 0.579 \mu\text{m}$ and $1.000 \pm 0.183 \mu\text{m}$, respec-

tively (Du Plessis *et al.* 2004). It was interesting to note, as indicated above, that while the lion platelet count ($275.5 \times 10^9/\ell$) was lower than that of cheetahs ($344 \times 10^9/\ell$), the size of individual platelets was larger. Whether there is a relationship between larger platelets and a lower platelet count as in this case, which is implied in the literature (Levin & Bessman 1983), remains to be determined. Care was taken to exclude any artificial alterations in size by collecting the blood in an anti-coagulant containing citrate (ACD in this case) as opposed to EDTA which is known to influence blood cell morphology after prolonged exposure (Bath 1993; Macey, Azam, McCarthy, Webb, Chapman, Okrongly, Zelmanovic & Newland 2002). However, the possibility of an underlying condition affecting the well-being of the lions, which influenced the platelet size, cannot be excluded. The differences in platelet size of the two populations investigated in this study emphasize the importance of demographic origins, collecting samples from more than one location when establishing a baseline, sample size and the importance of comparative studies. The heterogeneity of platelets regarding size, number and function, and its clinical significance remains controversial.

In conclusion, the morphology of the lion platelets conformed to the general description of mammalian platelets. By examining a sample size of 16 lions living in the wild, this study strengthens the quantitative and baseline information available on the platelets of wild felids.

ACKNOWLEDGEMENTS

I wish to thank the Venetia Nature Reserve and the Hluhluwe-iMfolozi Park for permission to collect the blood samples, the staff at both locations for their help, and in particular Dr P. Brothers and the late Prof. D.G.A. Meltzer for co-ordinating the projects and immobilizing the lions. The assistance of Prof. A. Guthrie, Faculty of Veterinary Science, University of Pretoria, for help with the statistical analysis is gratefully acknowledged.

REFERENCES

- BATH, P.M.W. 1993. The routine measurement of platelet size using sodium citrate alone as the anticoagulant. *Thrombosis and Haemostasis*, 70:687–690.
- CLINKENBEARD, K.D. & MEINKOTH, J.H. 2000. Normal hematology of the cat, in *Schalm's veterinary hematology*, 5th ed., edited by B.F. Feldman, J.G. Zinkl & N.C. Jain. New York: Lippincott Williams & Wilkins.
- DU PLESSIS, L., BOTHA, A.J. & STEVENS, K. 1996. Ultrastructure of buffalo, *Syncerus caffer*, platelets: comparison with bovine and human platelets. *Journal of Morphology*, 229: 309–314.
- DU PLESSIS, L., BOTHA, A.J., REYERS, F. & STEVENS, K. 2004. Blood platelets of the cheetah (*Acinonyx jubatus*). *Zoo Biology*, 23:263–271.
- HAWKEY, C.M. 1991. The value of comparative haematological studies. *Comparative Haematology International*, 1:1–9.
- HAWKEY, C.M., HART, M.G., BENNETT, P.M., GASCOYNE, S.C., KNIGHT, J.A. & KIRKWOOD, J.K. 1990. Diagnostic value of platelet counts in mammals. *Veterinary Record*, 127: 18.
- HAWKEY, C.M. & HART, M.G. 1986. Haematological reference values for adult pumas, lions, tigers, leopards, jaguars and cheetahs. *Research in Veterinary Science*, 41:268–269.
- JAIN, N.C. 1993. *Essentials of veterinary hematology*. Philadelphia: Lea & Febiger.
- LEVIN, J. & BESSMAN, J.D. 1983. The inverse relationship between platelet volume and platelet number. *Journal of Laboratory and Clinical Medicine*, 101:295–307.
- LUMSDEN, J.H. 2000. Reference values, in *Schalm's veterinary hematology*, 5th ed., edited by B.F. Feldman, J.G. Zinkl & N.C. Jain. New York: Lippincott Williams & Wilkins.
- MACEY, M., AZAM, U., MCCARTHY, D., WEBB, L., CHAPMAN, E.S., OKRONGLY, D., ZELMANOVIC, D. & NEWLAND, A. 2002. Evaluation of the anticoagulants EDTA and citrate, theophylline, adenosine, and dipyridamole (CTAD) for assessing platelet activation on the ADVIA 120 hematology system. *Clinical Chemistry*, 48:891–899.
- MOORE, D.M. 2000. Hematology of the mouse (*Mus musculus*), in *Schalm's veterinary hematology*, 5th ed., edited by B.F. Feldman, J.G. Zinkl & N.C. Jain. New York: Lippincott Williams & Wilkins.
- MORITZ, A., FICKENSCHER, Y., MEYER, K., FAILING, K. & WEISS, D.J. 2004. Canine and feline hematology reference values for the Advia 120 hematology system. *Veterinary Clinical Pathology*, 33:32–38.
- NORMAN, E.J., BARRON, R.C.J., NASH, A.S. & CLAMPITT, R.B. 2001. Prevalence of low automated platelet counts in cats: comparison with prevalence of thrombocytopenia based on blood smear estimation. *Veterinary Clinical Pathology*, 30:137–140.
- POTHIWONG, W., SAKULWIRA, K., PRACHAMMUANG, P. & VETHCHAGARUN, S. 2006. Observations on the structure of red blood cells, white blood cells and platelets in some *Felis* spp. and *Panthera* spp. *Thai Journal of Veterinary Medicine*, 36:55–62.
- SIRIOS, M. 1990. Mammalian blood cell morphology. Part II. Leukocytes and thrombocytes. *Veterinary Technician*, 11: 465–470.
- TABLIN, F. 2000. Platelet structure and function, in *Schalm's veterinary hematology*, 5th ed., edited by B.F. Feldman, J.G. Zinkl & N.C. Jain. New York: Lippincott Williams & Wilkins.
- ZELMANOVIC, D. & HETHERINGTON, E.J. 1998. Automated analysis of feline platelets in whole blood, including platelet count, mean platelet volume, and activation state. *Veterinary Clinical Pathology*, 27:2–9.
- ZUCKER-FRANKLIN, D. 1988. Megakaryocytes and platelets, in *Atlas of blood cells, function and pathology*, edited by D. Zucker-Franklin, M.F. Greaves, C.E. Grossi & A.M. Marmont. Philadelphia: Lea & Febiger.