

An outbreak of chlamydiosis in farmed Indopacific crocodiles (*Crocodylus porosus*)

F W Huchzermeyer^{a*}, E Langelet^b and J F Putterill^c

ABSTRACT

An outbreak of chlamydiosis was diagnosed in hatchling and juvenile Indopacific crocodiles (*Crocodylus porosus*) on a crocodile farm in Papua New Guinea. The outbreak was characterised by high mortality with hepatitis and exudative conjunctivitis. The agent appears to have been introduced with live wild-caught crocodiles, which are purchased routinely by the farm. Improved quarantine procedures and treatment with tetracycline led to a rapid reduction of losses on the farm.

Key words: *Chlamydia*, conjunctivitis, crocodile, *Crocodylus porosus*, hepatitis, tonsillitis.

Huchzermeyer F W, Langelet E, Putterill J F **An outbreak of chlamydiosis in farmed Indopacific crocodiles (*Crocodylus porosus*)**. *Journal of the South African Veterinary Association* (2008) 79(2): 99–100 (En.). PO Box 12499, Onderstepoort, 0110 South Africa.

INTRODUCTION

Outbreaks of chlamydiosis have previously been reported in farmed Nile crocodiles (*Crocodylus niloticus*) in South Africa and Zimbabwe with hepatitis in the acute form and conjunctivitis in chronic cases^{2,4}. While cases of chlamydiosis have been reported from many reptile species, the occurrence of the disease in crocodiles appeared to be restricted to the Nile crocodile in southern Africa^{1,5}. This paper reports on a severe outbreak of chlamydiosis in hatchling and juvenile Indopacific crocodiles on a farm in Papua New Guinea.

^aPO Box 12499, Onderstepoort, 0110 South Africa.

^bMainland Holdings Crocodile Farm, PO Box 169, Lae, 411 Papua New Guinea.

^cOnderstepoort Veterinary Institute, Private Bag X05, Onderstepoort, 0110 South Africa.

*Author for correspondence.
E-mail: crocvet@mweb.co.za

Received: November 2007. Accepted: June 2008.

CASE HISTORY

The crocodile farm where the outbreak occurred recruits hatchlings and juveniles of Indopacific crocodiles from 3 sources: incubation of eggs laid on the farm, incubation of eggs collected from the wild and the purchase of wild-caught juvenile crocodiles within certain size limits (66–120 cm, the majority between 70 and 85 cm). These animals are purchased throughout the year and are between 6 months and 1 year old. They are quarantined on arrival for 3 months and some mortality normally occurs during the first 2 months. The farm-produced eggs and those collected from the wild hatch at different times, spreading the rearing season of hatchlings. The proportion of live-purchased crocodiles of the total annual recruitment used to be around 50 %, but in the last few years there has been a decreasing trend in live purchases

not only due to increased hatches on the farm but also to a real reduction in live purchases which in the last 2 years had dropped to below 20 %. The live crocodiles come from all areas of the country, while eggs are collected in the Sepic River Region only. From 1994 to 2002 the annual mortality on the farm ranged between 11 % and 26 %, but in 2003 it increased to 63 % and reached 48 % in 2004 (Fig. 1).

After the provisional diagnosis of chlamydiosis had been established based on macroscopic pathology and impression smears, treatment of all infected and in-contact groups was started with tetracycline by injection, oral dosing and finally in the feed at 1.5 g active substance/kg of feed. In addition, a strict observation of quarantine procedures was introduced. Consequently the mortality declined to below 18 % in 2005 (Fig. 1).

MATERIALS AND METHODS

In December 2004 the senior author visited the farm near Lae and during a period of 10 days performed 102 *post mortems* on daily mortalities, the length of crocodiles ranging from 31 to 270 cm. Liver impression smears were air-dried, fixed and stained with Diff-Quick, the only stain available on the farm (Diff-Quick, Lab-Aids (Pty) Ltd, Narrabeen, expired in 1995). Organ samples were fixed in 10 % buffered formalin and later submitted to the Department of Pathology

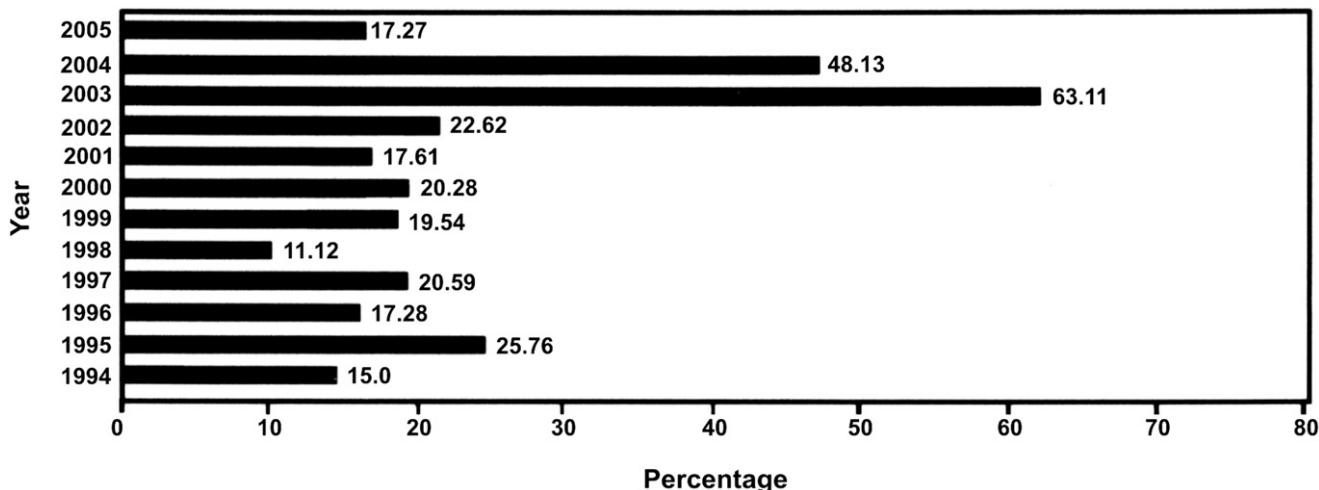


Fig. 1: Annual mortality of hatchlings and live-purchased crocodiles from 1994 to 2005.

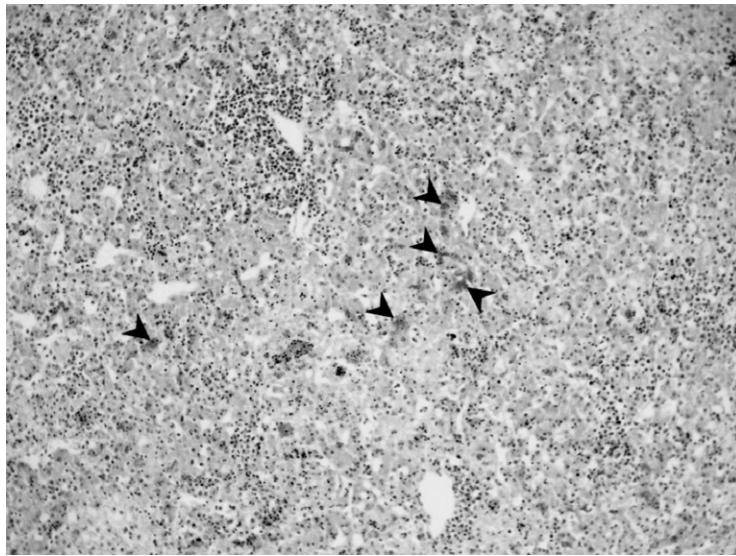


Fig. 2: Lymphoplasmocytic hepatitis with chlamydial colonies in hepatocytes (arrowheads).

of the Faculty of Veterinary Science, Onderstepoort, of the University of Pretoria, for routine embedding, sectioning and staining with haematoxylin-eosin and Giemsa. The stained sections were examined by the senior author.

RESULTS

In 75 of the cases the most important findings were hepatitis, splenomegaly, swollen pharyngeal tonsils and conjunctivitis. In addition, there were 10 cases of presumed bacterial dermatitis, 8 runts and various miscellaneous conditions including 1 case of pox. No internal or external parasites were found. The Diff-Quick-stained liver impression smears, although far from ideal, showed the presence of chlamydial colonies in the hepatocytes. This was later confirmed in the histopathological sections. There was a lymphoplasmocytic hepatitis with multifocal necrosis and chlamydial colonies in the hepatocytes (Fig. 2).

DISCUSSION

The liver lesions closely resembled those found in acute chlamydiosis in Nile crocodiles⁴. The pharyngeal tonsils had not been described at the time of the publication of the above paper⁶. There is therefore no basis for comparison of the

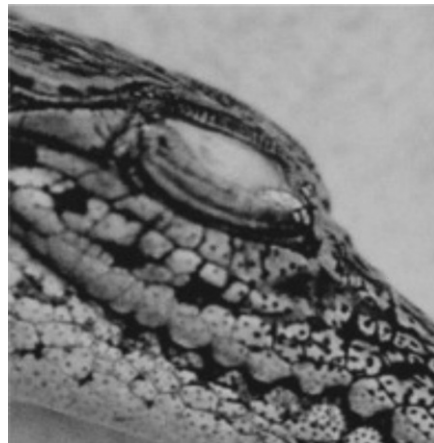


Fig. 3: Conjunctivitis in a *Crocodylus porosus* hatchling. Note the accumulation of fibrin under the nictitating membrane.

effect of the infection in the 2 crocodile species on this organ. Severe exudative conjunctivitis with deposits of fibrin under the nictitating membranes (Fig. 3) was a common feature in the outbreak described above, while in Nile crocodiles it appears to be restricted to outbreaks of the chronic form, which is not accompanied by hepatic lesions^{3,4}. While in a retrospective survey of chlamydiosis in reptiles it is stated categorically that reptilian cases of chlamydiosis occur sporadically only⁵, this is clearly not the case in croco-

diles. The liver lesions in the present cases were of the same confluent nature as previously described in Nile crocodiles⁴, while in most other reptilian cases granulomatous lesions prevail^{1,5}. The taxonomic status of the agent of crocodilian chlamydiosis remains unknown. However, all indications are that there is no danger to people handling live or slaughtered crocodiles or consuming crocodile meat².

The investigation on the farm indicated that the live-purchased crocodiles appeared to be the source of the infection. Usually the animals arrive in a severely stressed state which may contribute to activation of a dormant infection into a clinical manifestation. While it is recognised that the purchase of live wild-caught animals poses the danger of introducing diseases, the farm is legally obliged to continue this practice. Together with egg collection it is intended as a conservation measure that also provides a crocodile-related income for the villagers.

This is the 1st report of chlamydiosis in a crocodilian species other than the Nile crocodile.

REFERENCES

1. Bodetti T J, Jacobson E, Wan C, Hafner L, Pospischil A, Rose K, Timms P 2002 Molecular evidence to support the expansion of the hostrange of *Chlamydiophila pneumoniae* to include reptiles as well as humans, horses, koalas and amphibians. *Systemic and Applied Microbiology* 25: 146–152
2. Huchzermeyer F W 1997 Public health risks of ostrich and crocodile meat. *Revue Scientifique et Technique, Office International des Epizooties* 16: 599–604
3. Huchzermeyer F W 2003 *Crocodiles: biology, husbandry and diseases*. CABI Publishing, Wallingford, Oxon, UK
4. Huchzermeyer F W, Gerdes G H, Foggin C N, Huchzermeyer K D A, Limper L C 1994 Hepatitis in farmed hatchling Nile crocodiles (*Crocodylus niloticus*) due to chlamydial infection. *Journal of the South African Veterinary Association* 65: 20–22
5. Soldati G, Lu H, Vaughan L, Polkinghorne A, Zimmermann D R, Huder J B, Pospischil A 2004 Detection of mycobacteria and chlamydiae in granulomatous inflammation of reptiles: a retrospective study. *Veterinary Pathology* 41: 388–397
6. Putterill J E, Soley J T 2001 Surface features of the roof of the pharyngeal cavity of the Nile crocodile, *Crocodylus niloticus*. *Proceedings Microscopical Society of Southern Africa* 31: 69